



**CATÁLOGO
MODELOS
ANATOMÍA II
S. CARDIOVASCULAR**

Facultad Ciencias de la Salud




**Biblioteca y
Centro de Recursos**



**UNIVERSIDAD DE
MANIZALES®**
Acreditación Institucional
de Alta Calidad
Resolución 4752 de 11 de mayo de 2019

S

- Ángela Morales
- Camila Suárez
- Carlos López
- Fabián Ortega
- Felipe Lara
- Felipe Sanabria
- Juan Carlos Rengifo
- Juan David Ossa
- Laura Sánchez
- Manuel Ramírez
- Manuela Castrillón
- Sebastián Cárdenas
- Stephanía Núñez



Mediastino – Grandes Vasos

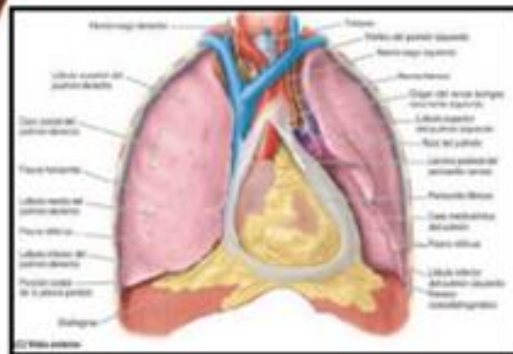
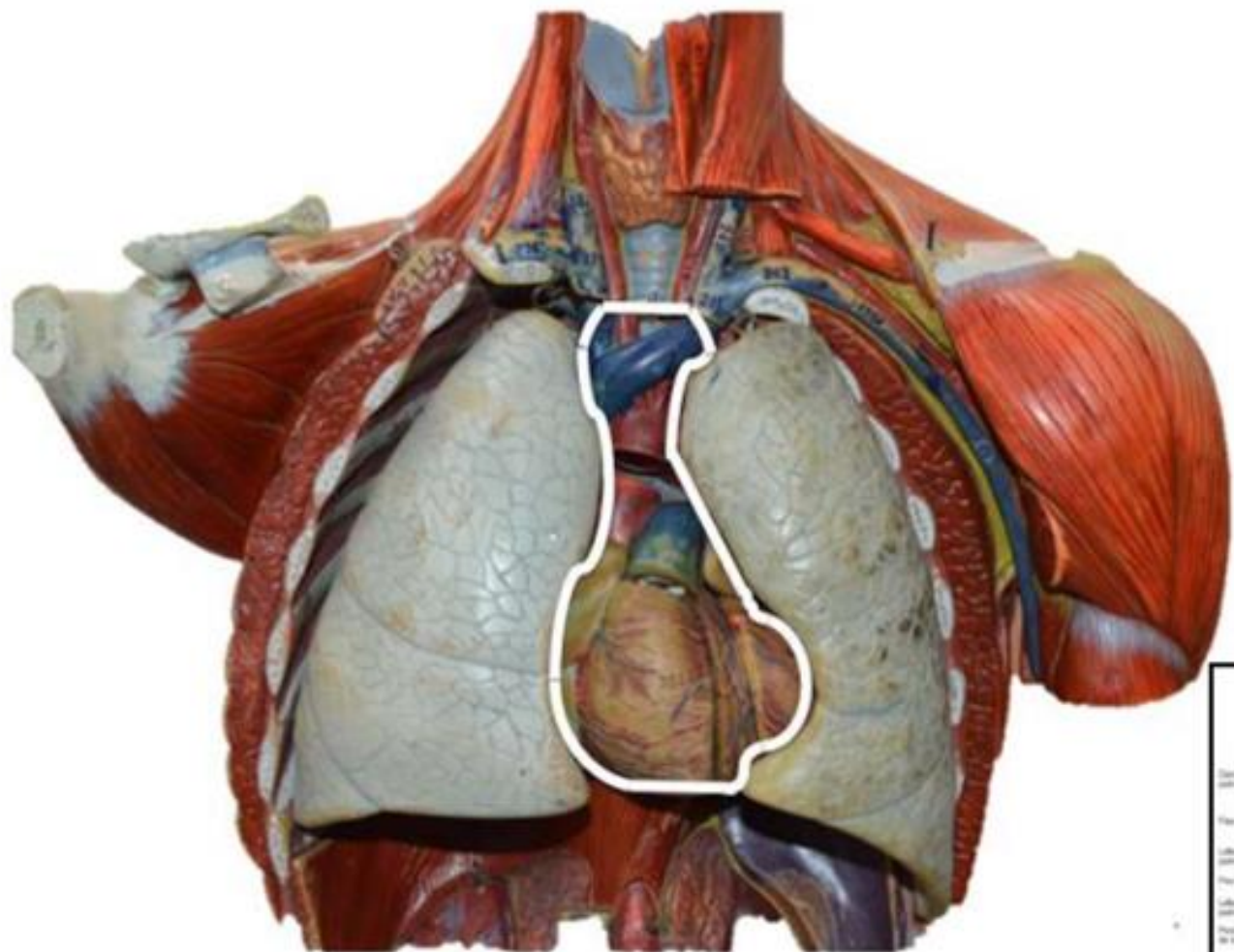
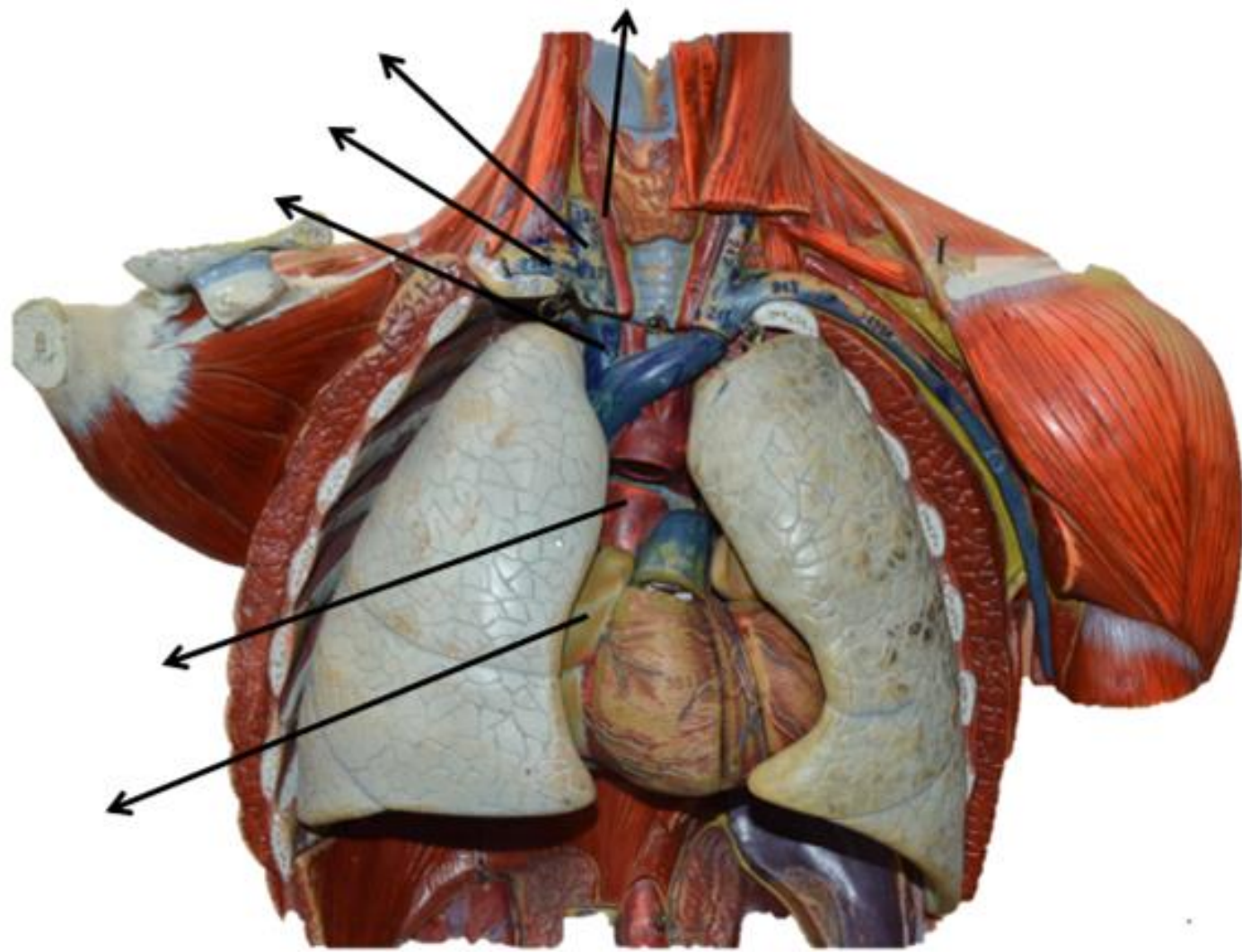
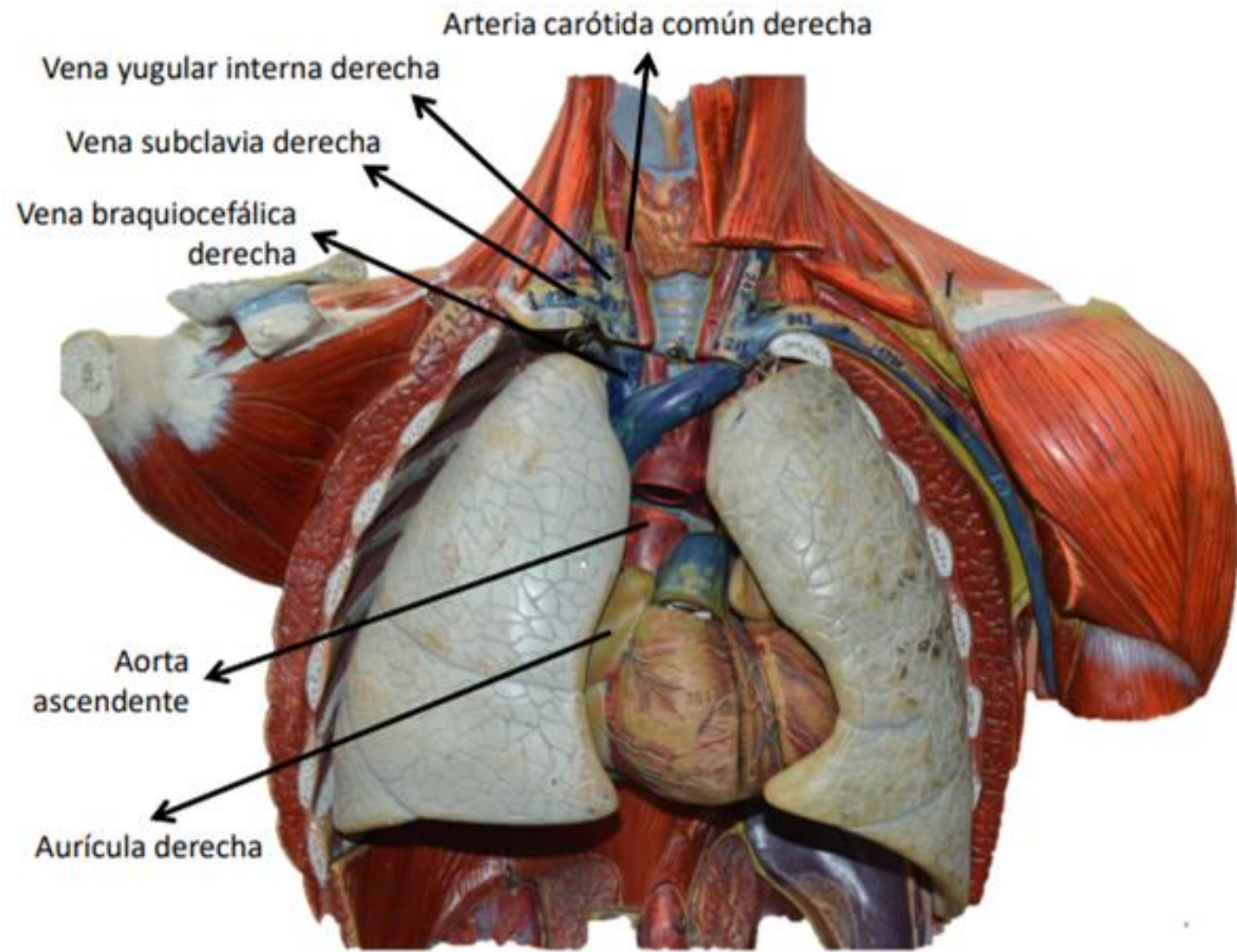
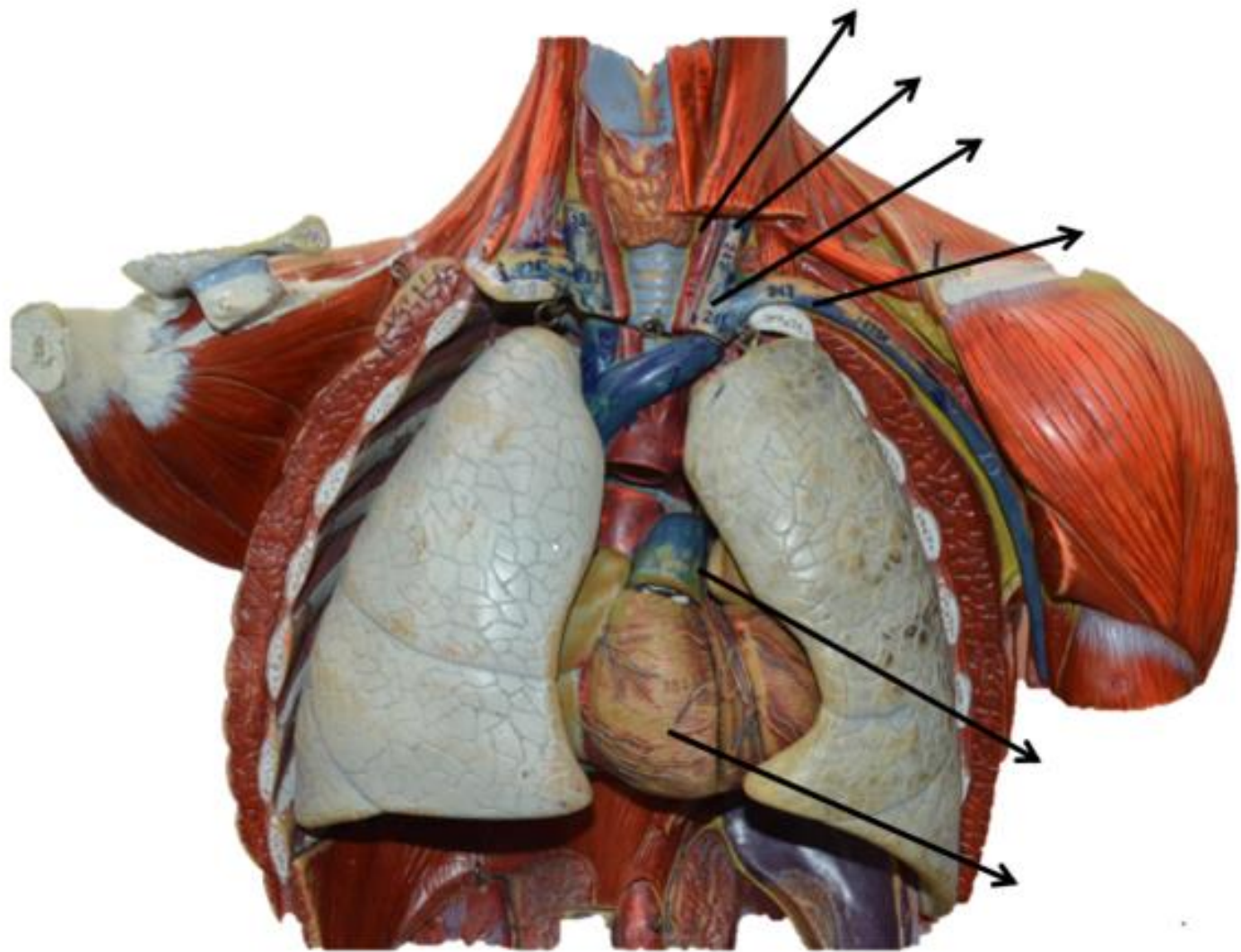


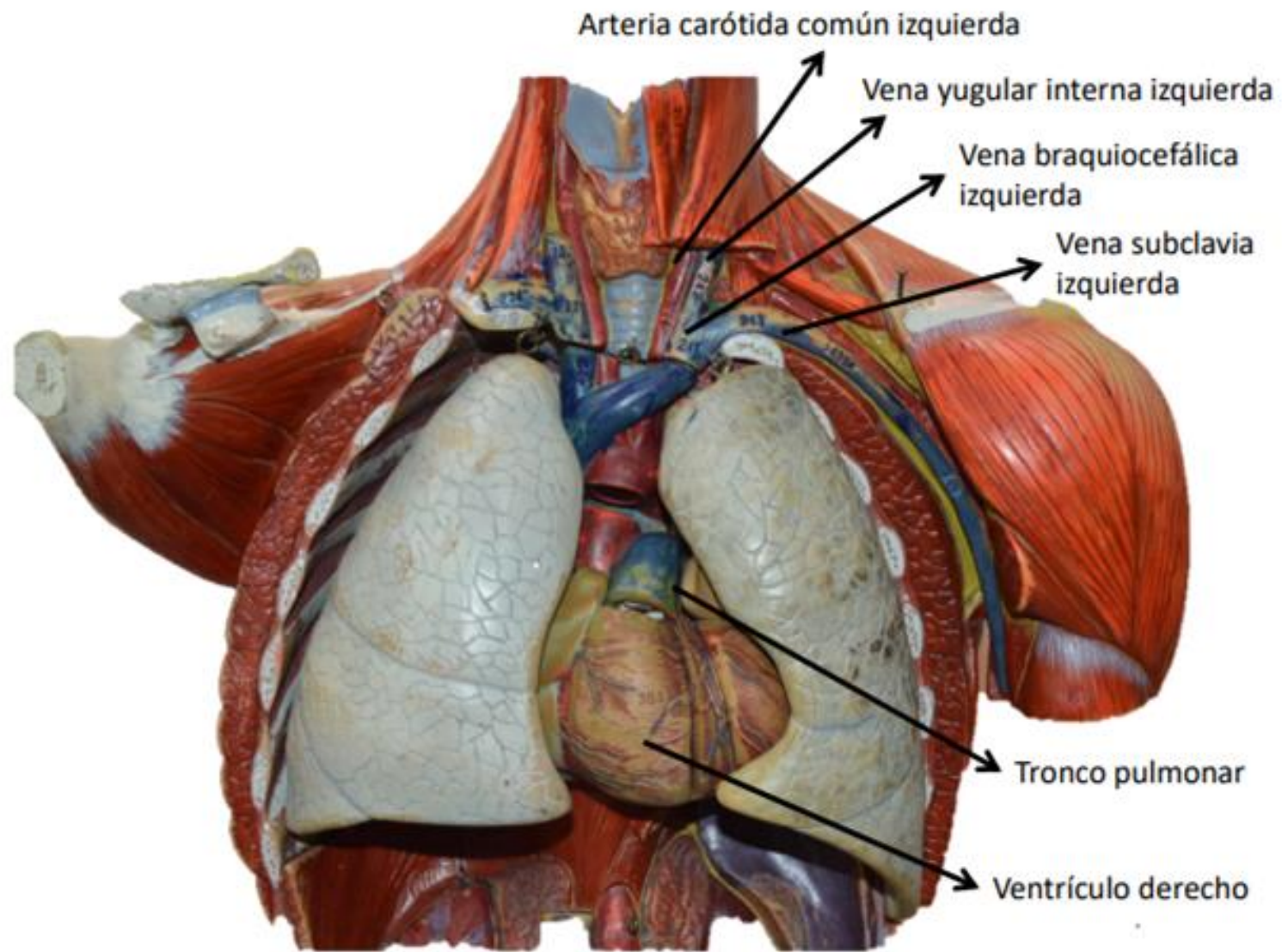
Figura: 4-33. Caras costales de los pulmones.

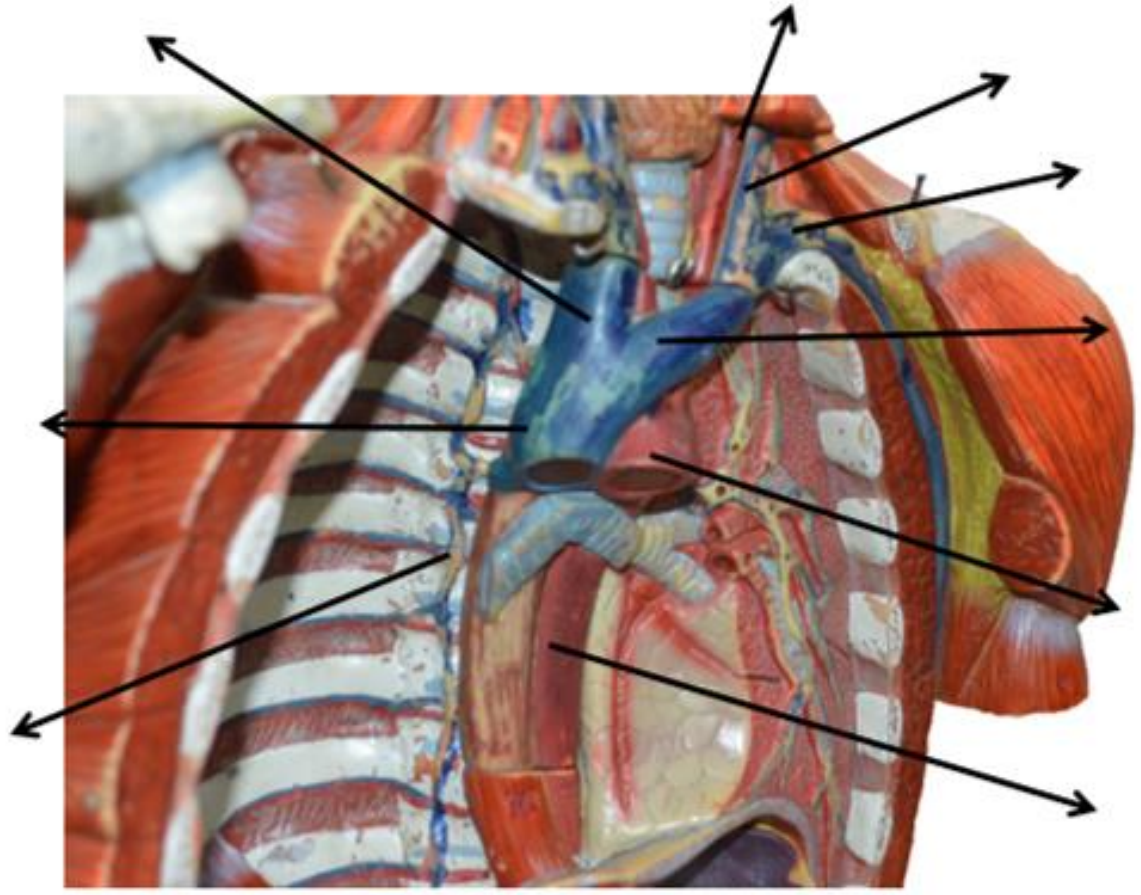
Fuente: Moore KL, Dalley AF, Agur A MR; Fundamentos de anatomía con orientación clínica. 8a Ed. Barcelona: Wolters kluwer Health; 2018. Pagina, 637

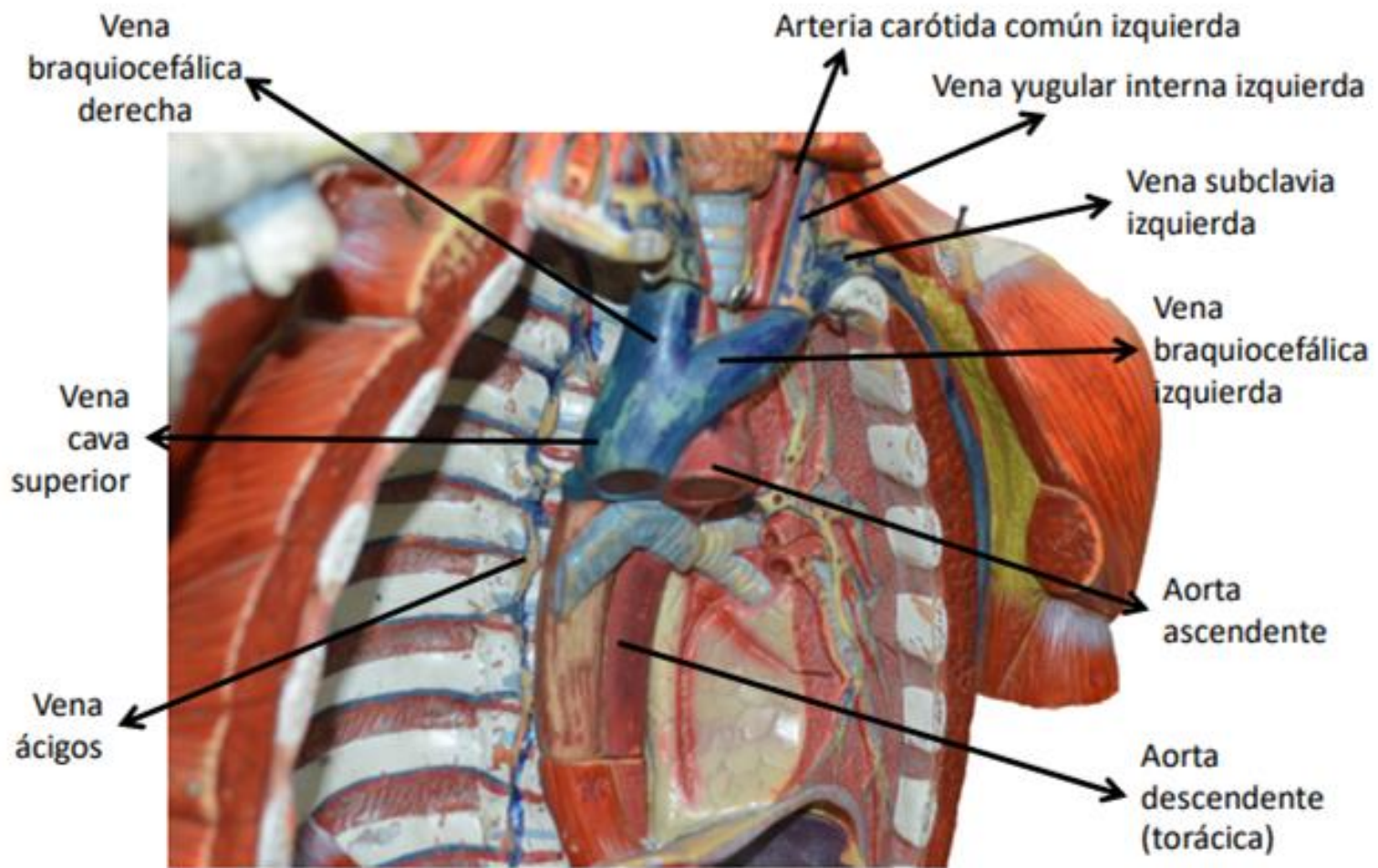


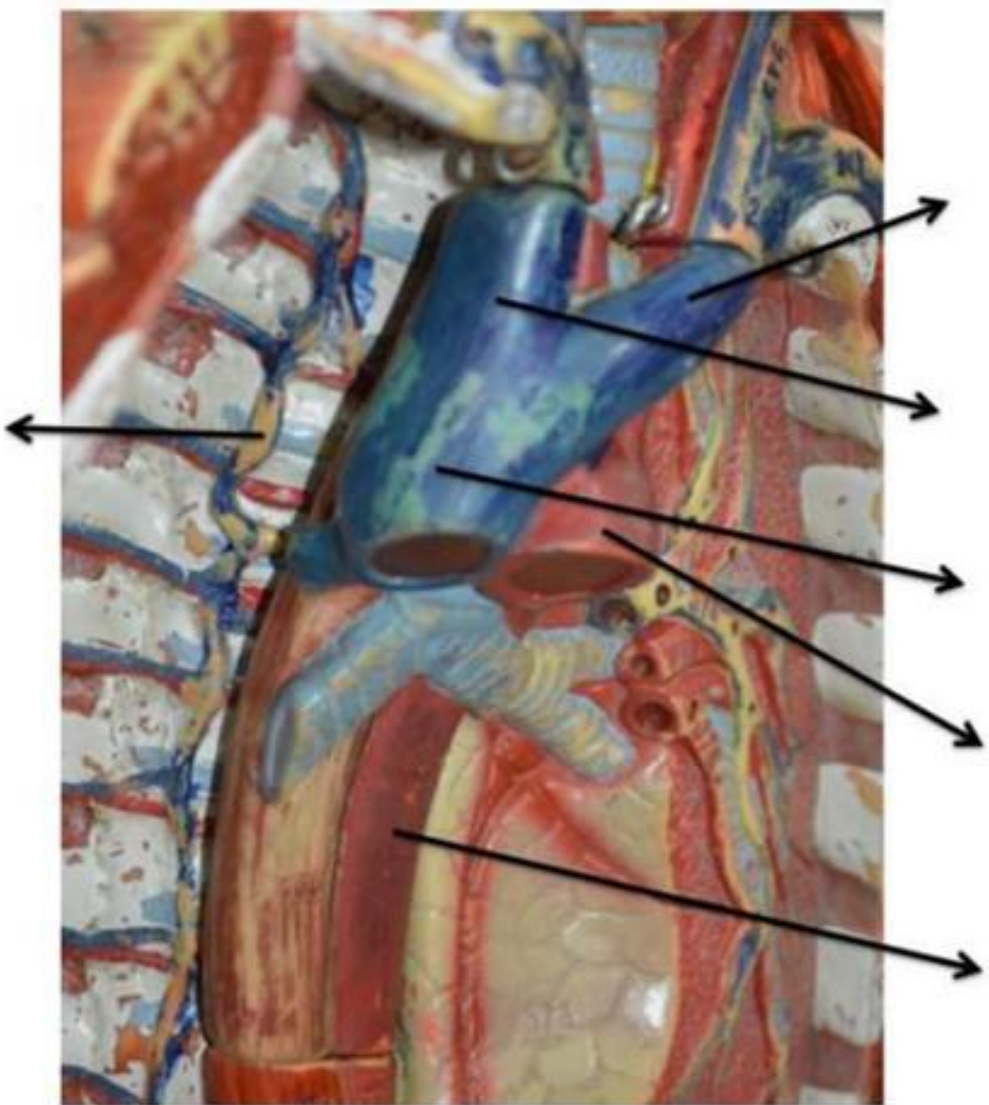












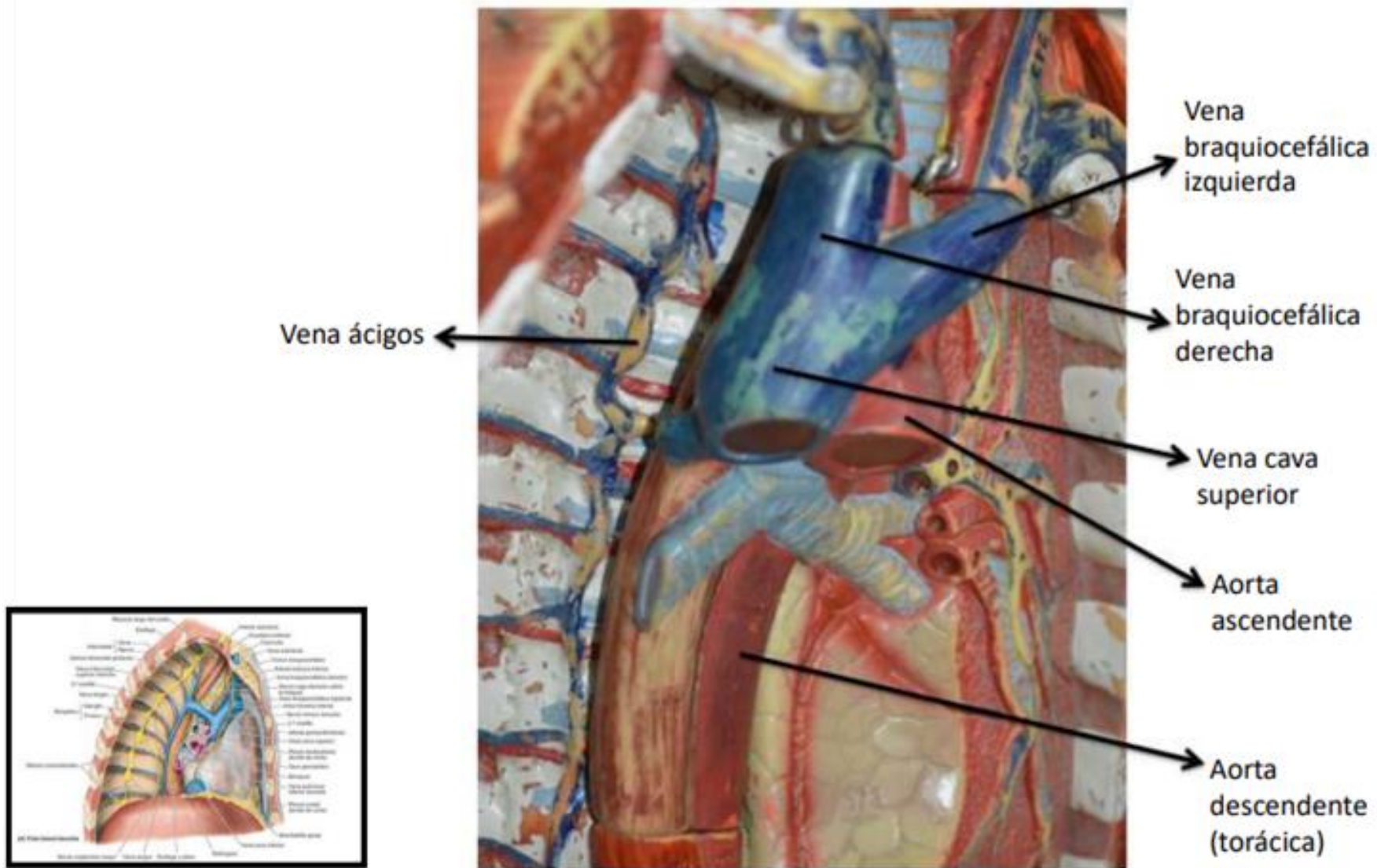
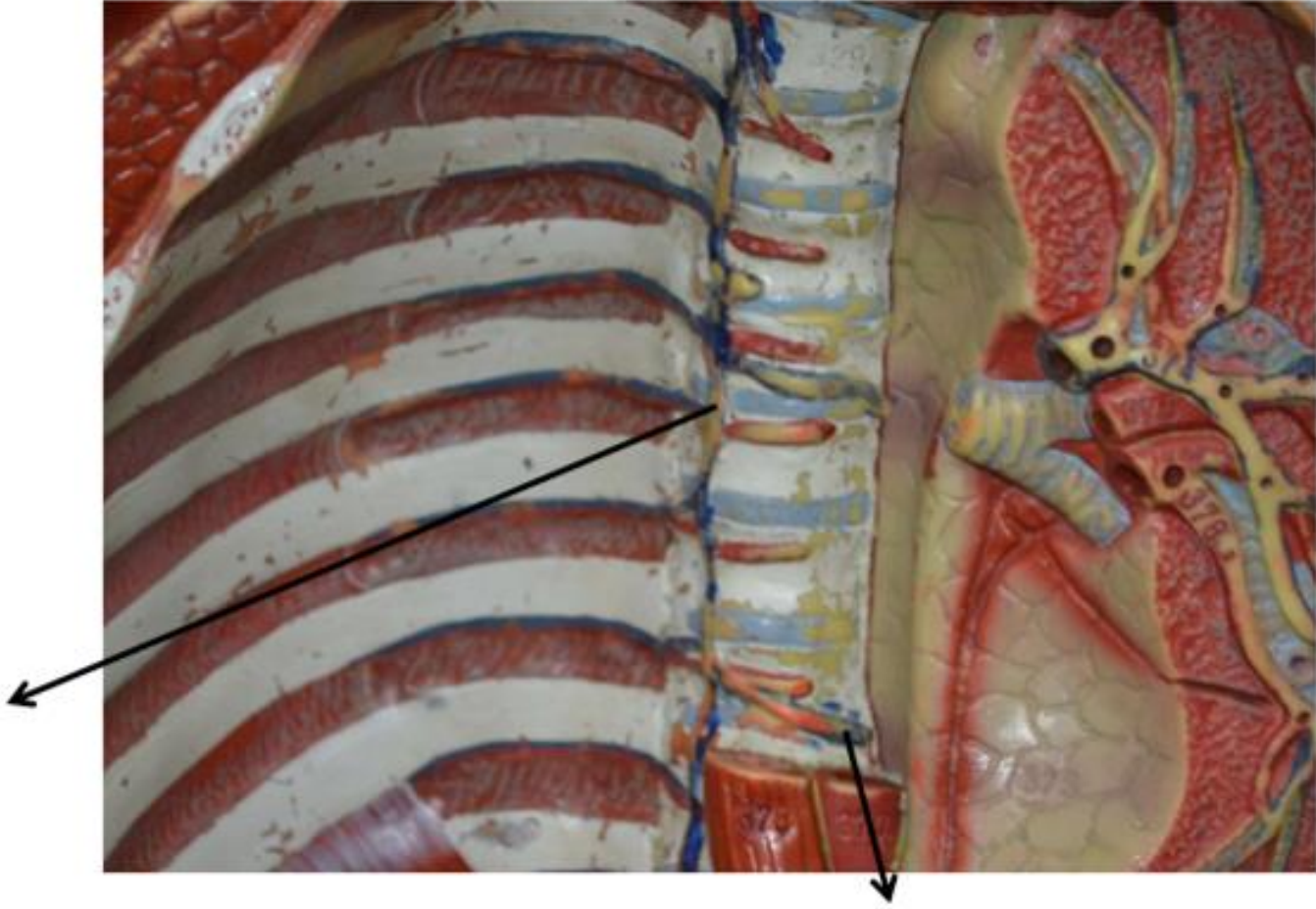
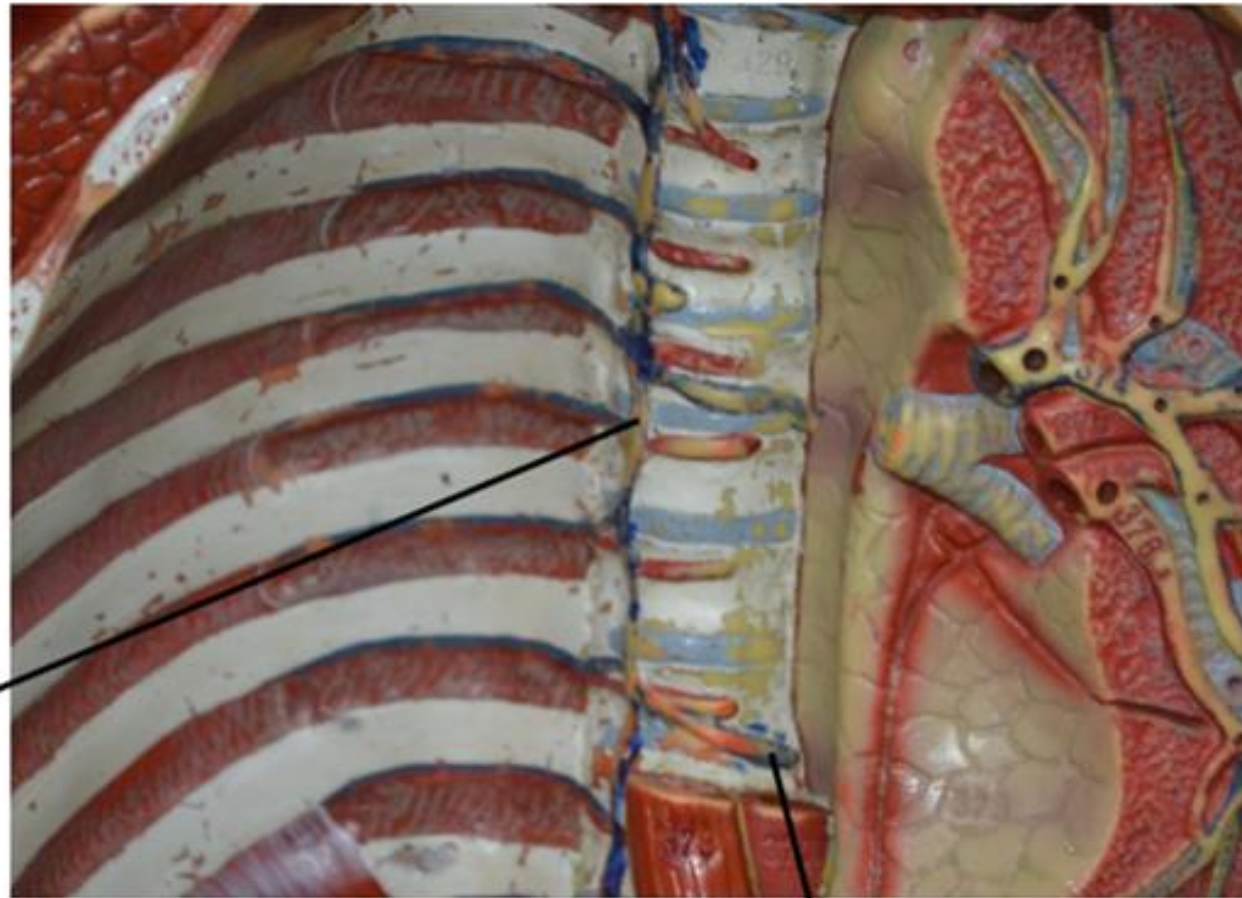
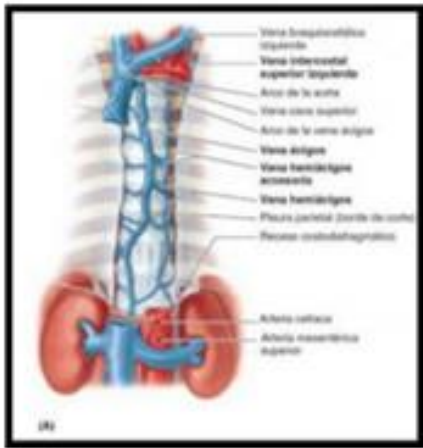


Figura: 4-71. Presentación lateral del mediastino.

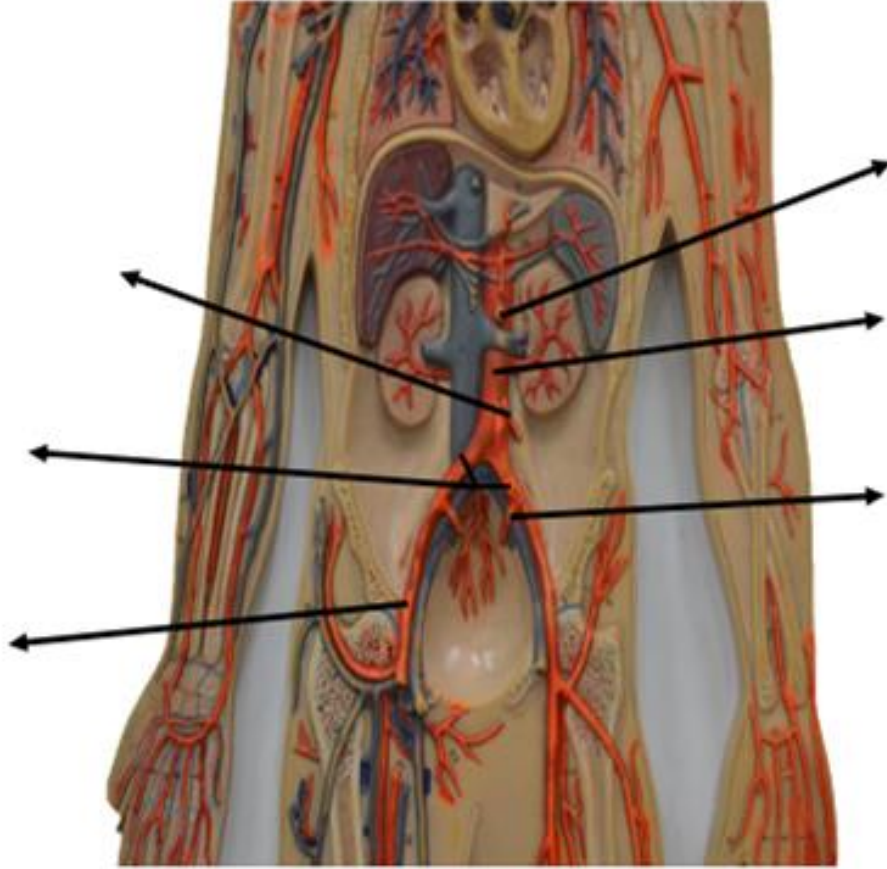




Vena
ácigos

Vena
hemiaquílica

Figura: 4-75. Sistema venoso ácigos.



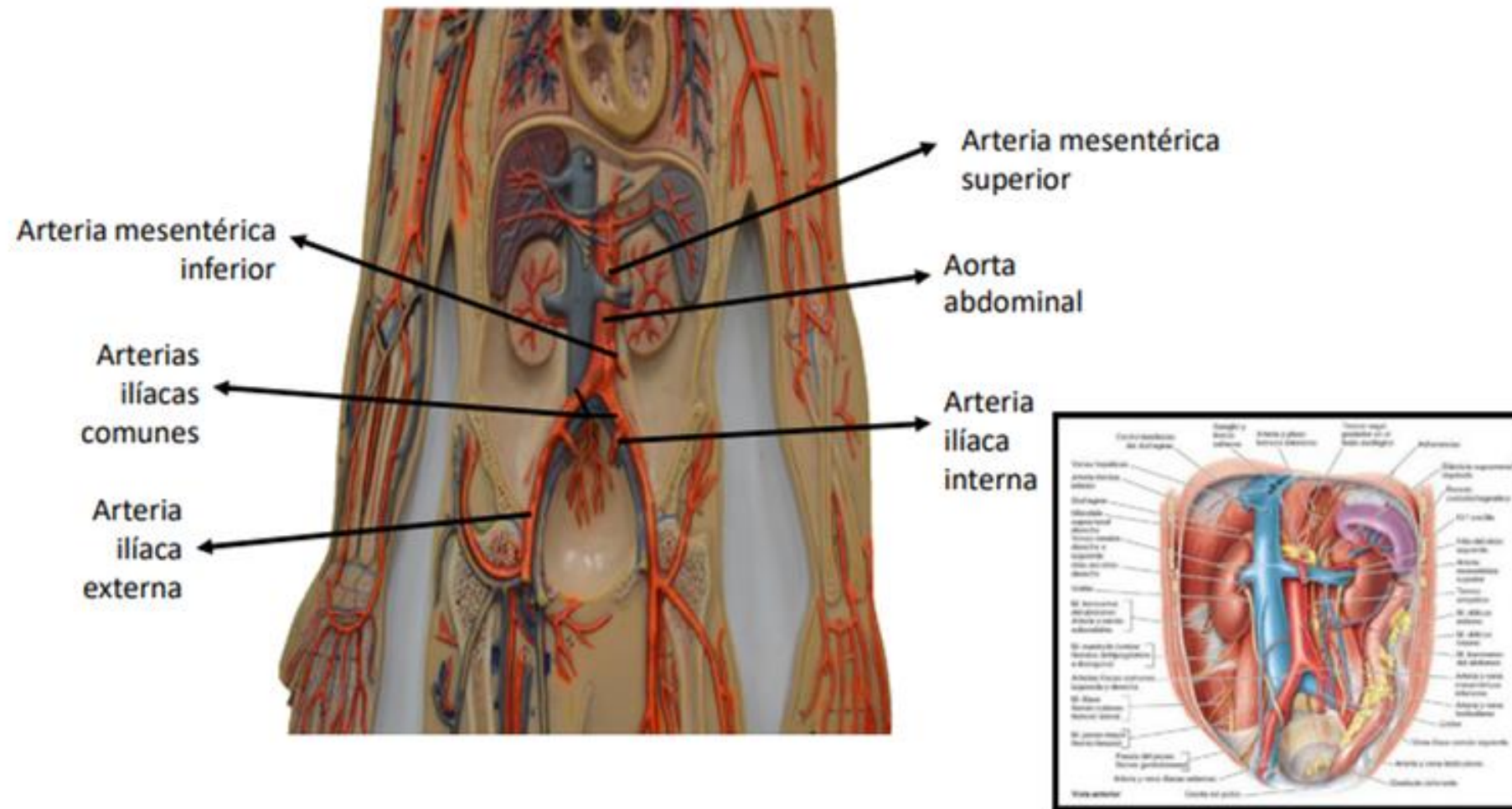
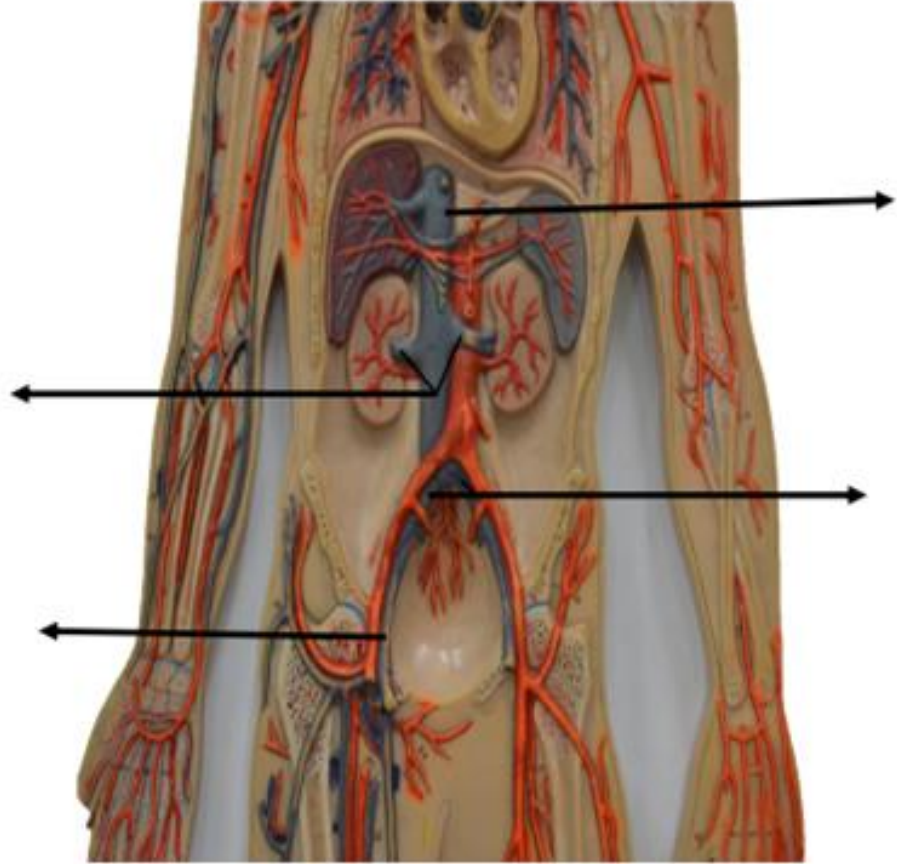
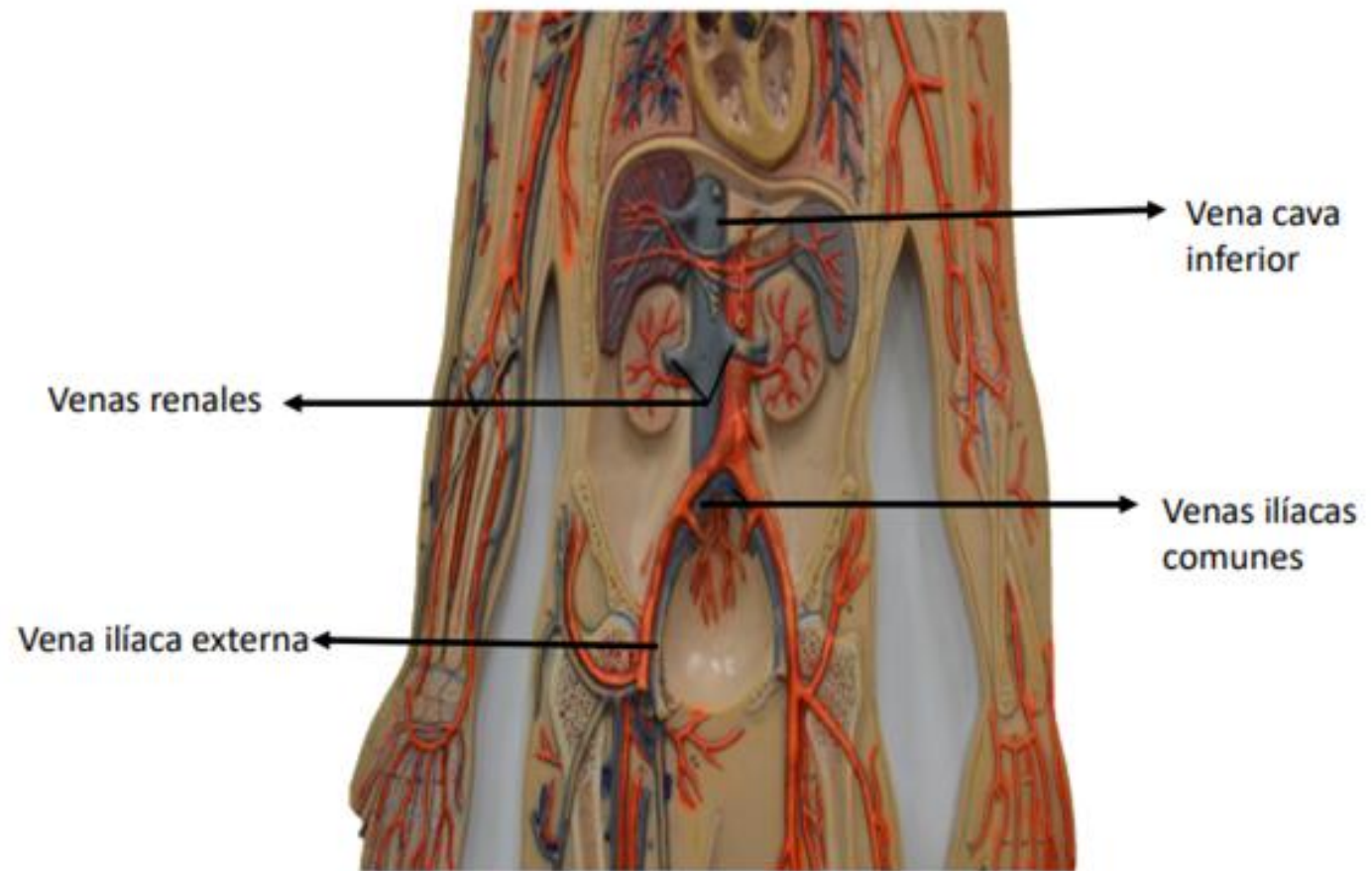


Figura: 5-76. Pared posterior del abdomen. Se observan los grandes vasos, los riñones, las glándulas suprarrenales.

Fuente: Moore KL, Dalley AF, Agur A MR; Fundamentos de anatomía con orientación clínica. 8a Ed. Barcelona: Wolters kluwer Health; 2018. Pagina, 957





Vena cava inferior

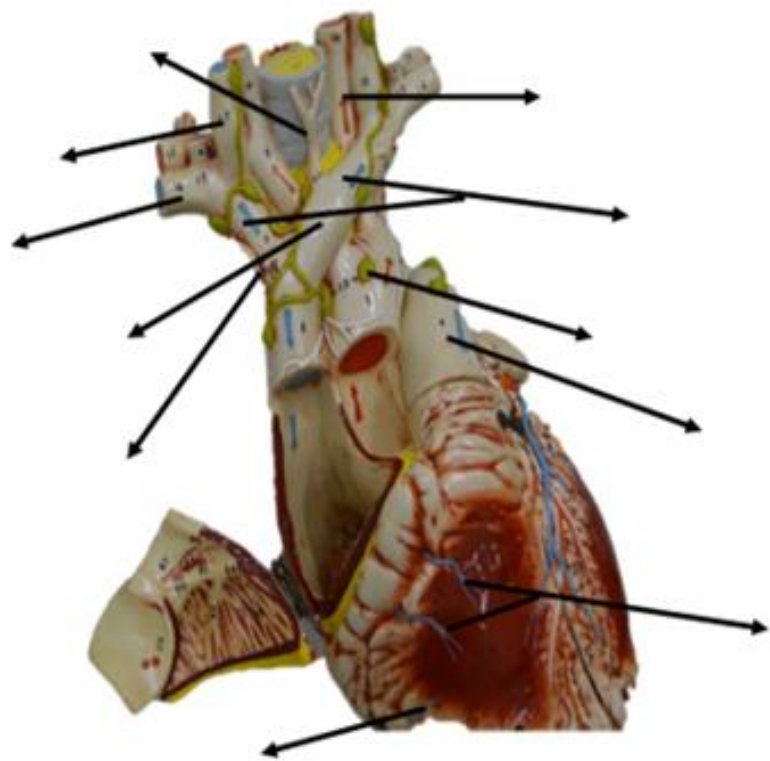
Venas renales

Venas ilíacas comunes

Vena ilíaca externa



Corazón



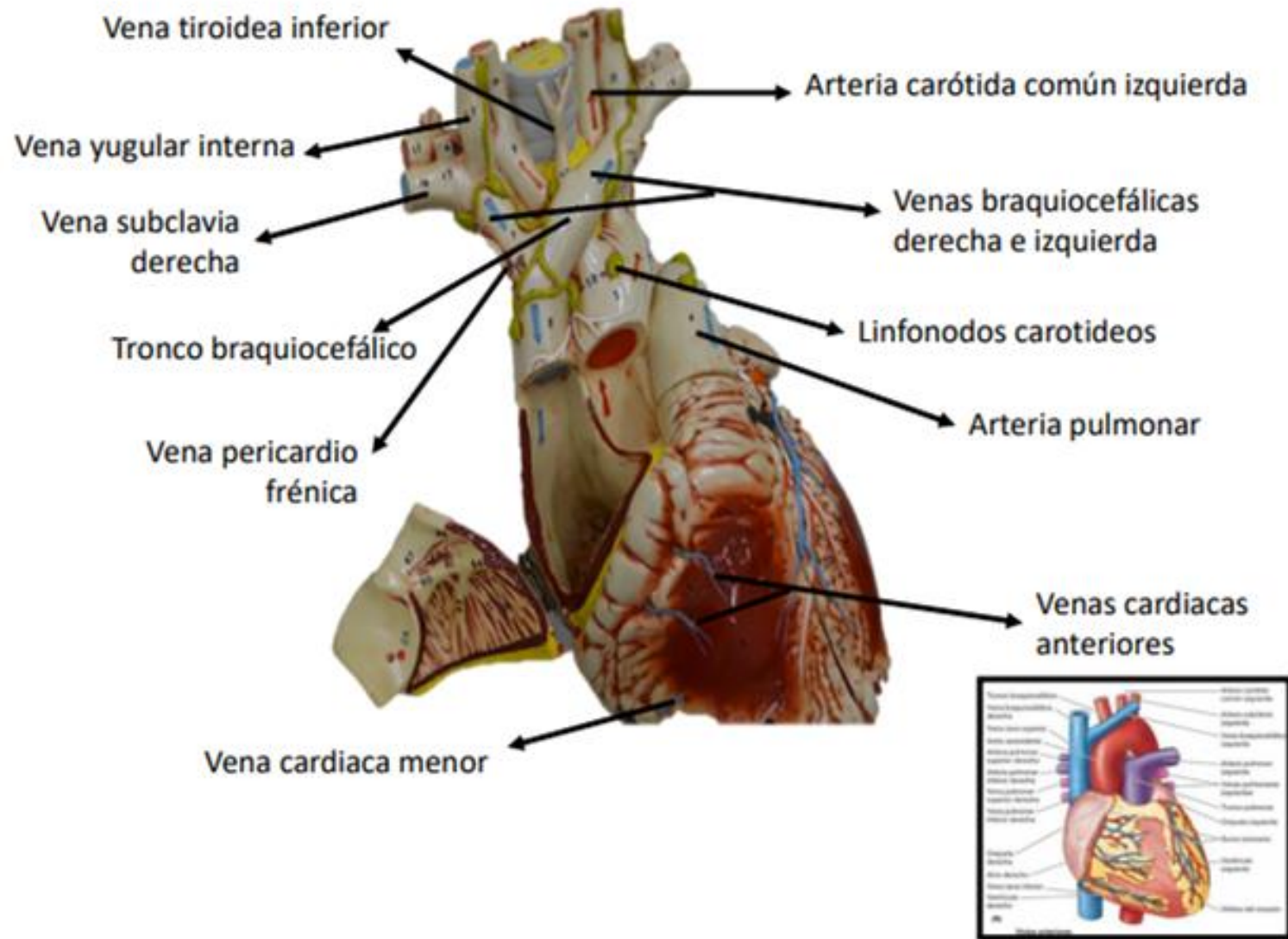
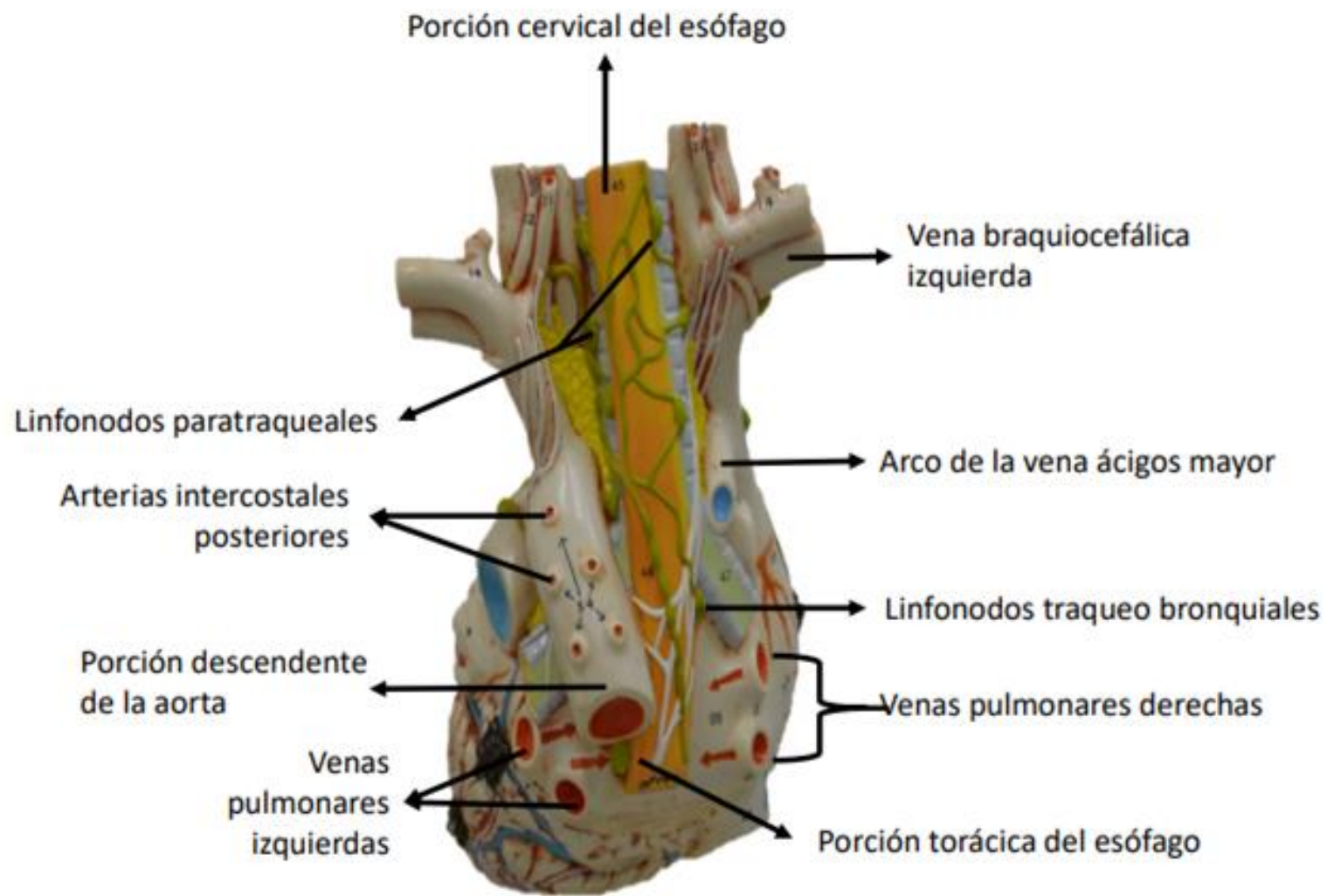
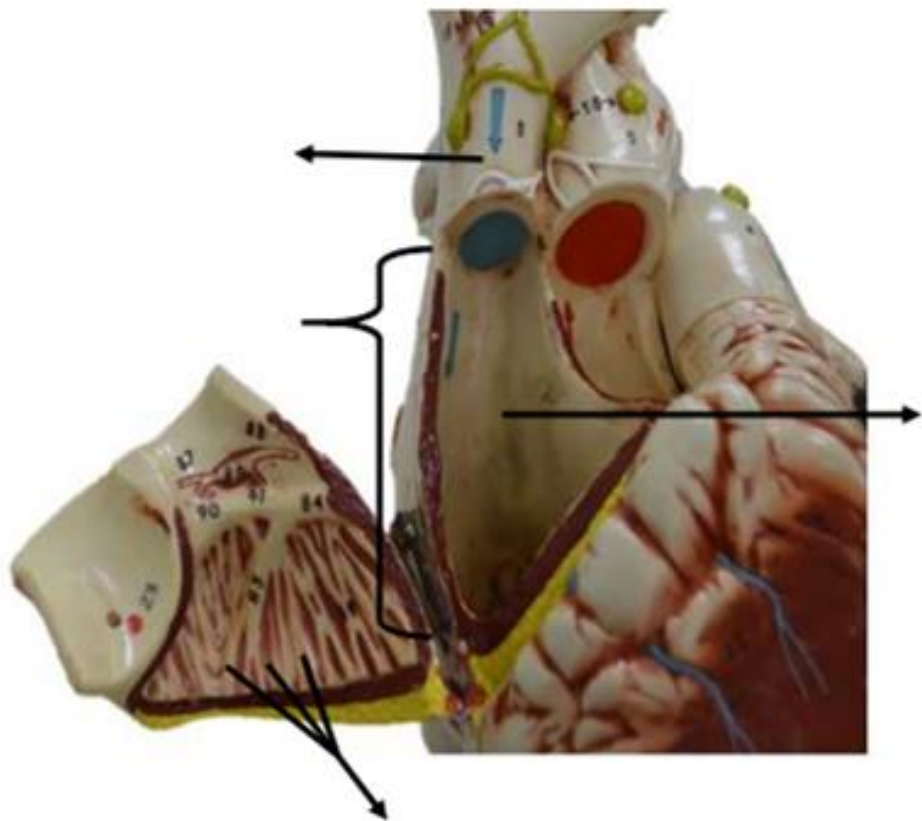


Figura: 4-53. Forma, orientación, caras y bordes del corazón.





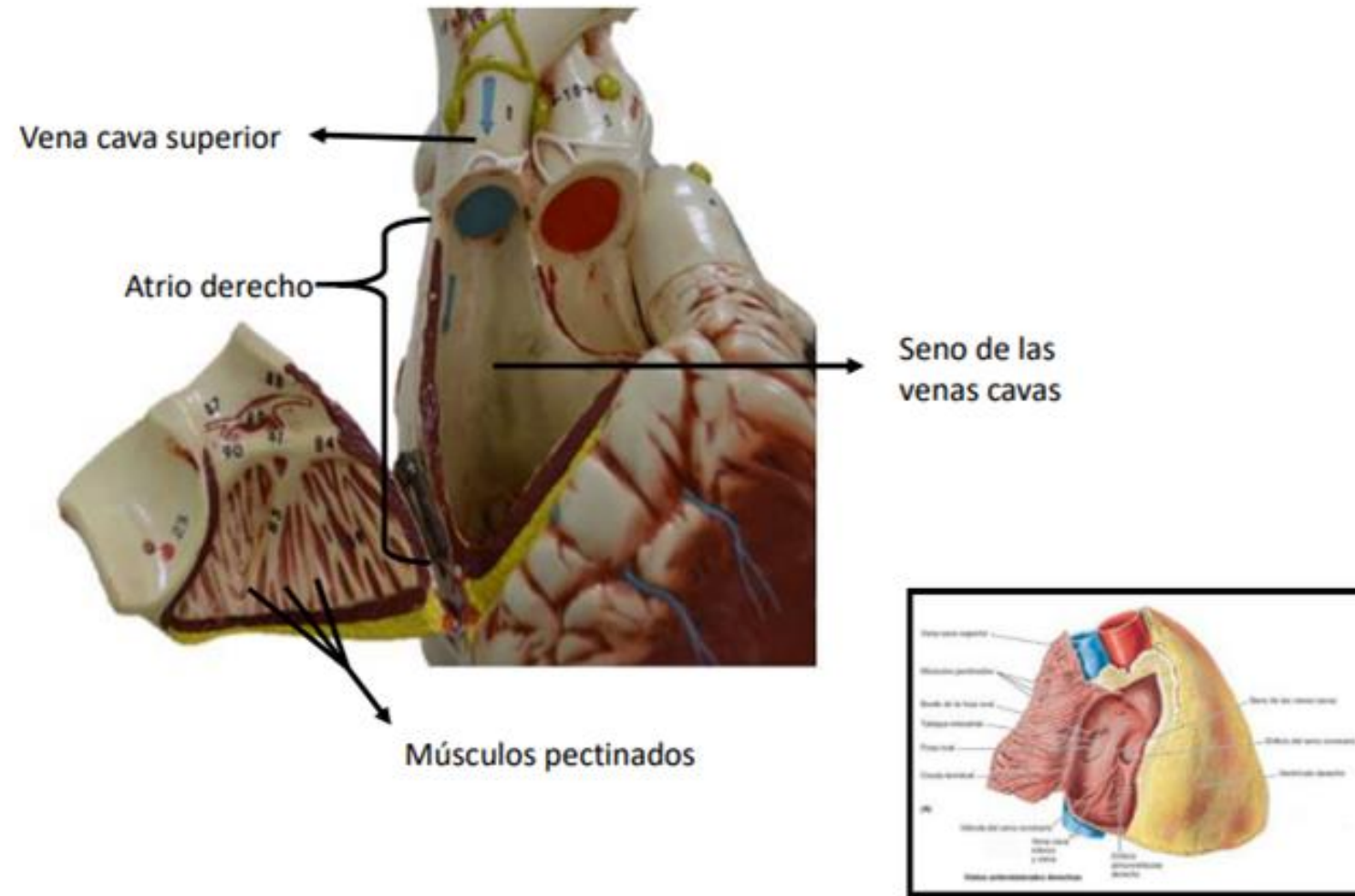
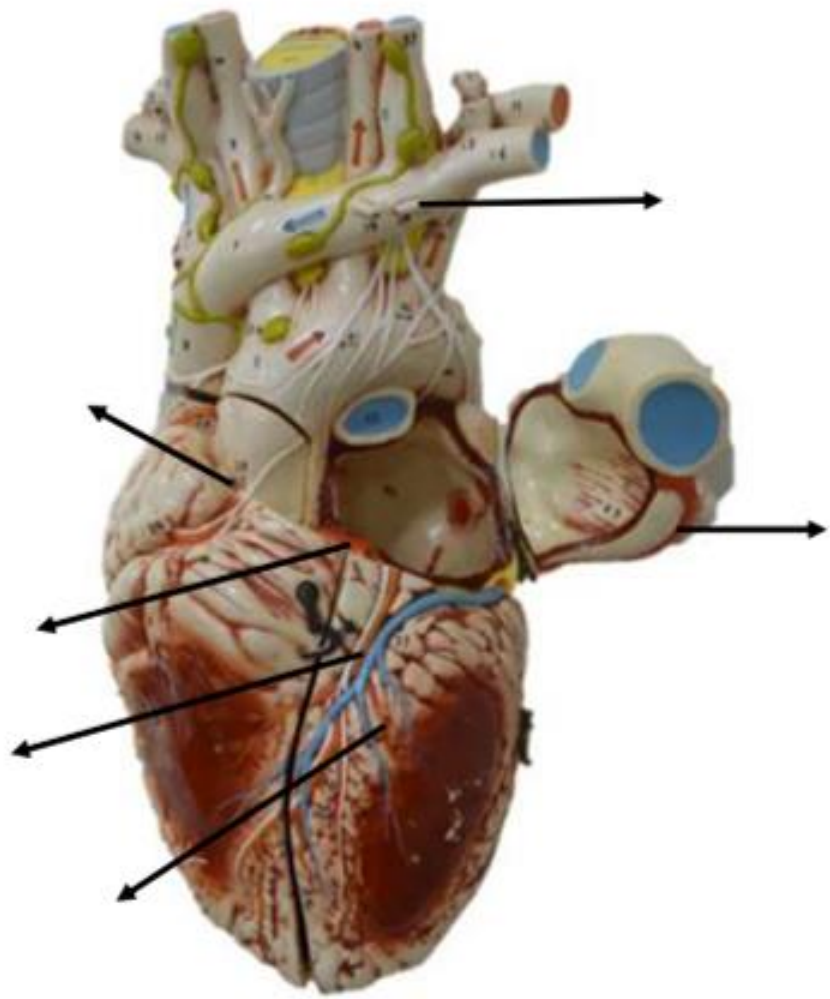


Figura: 4-54. Atrio derecho del corazón.



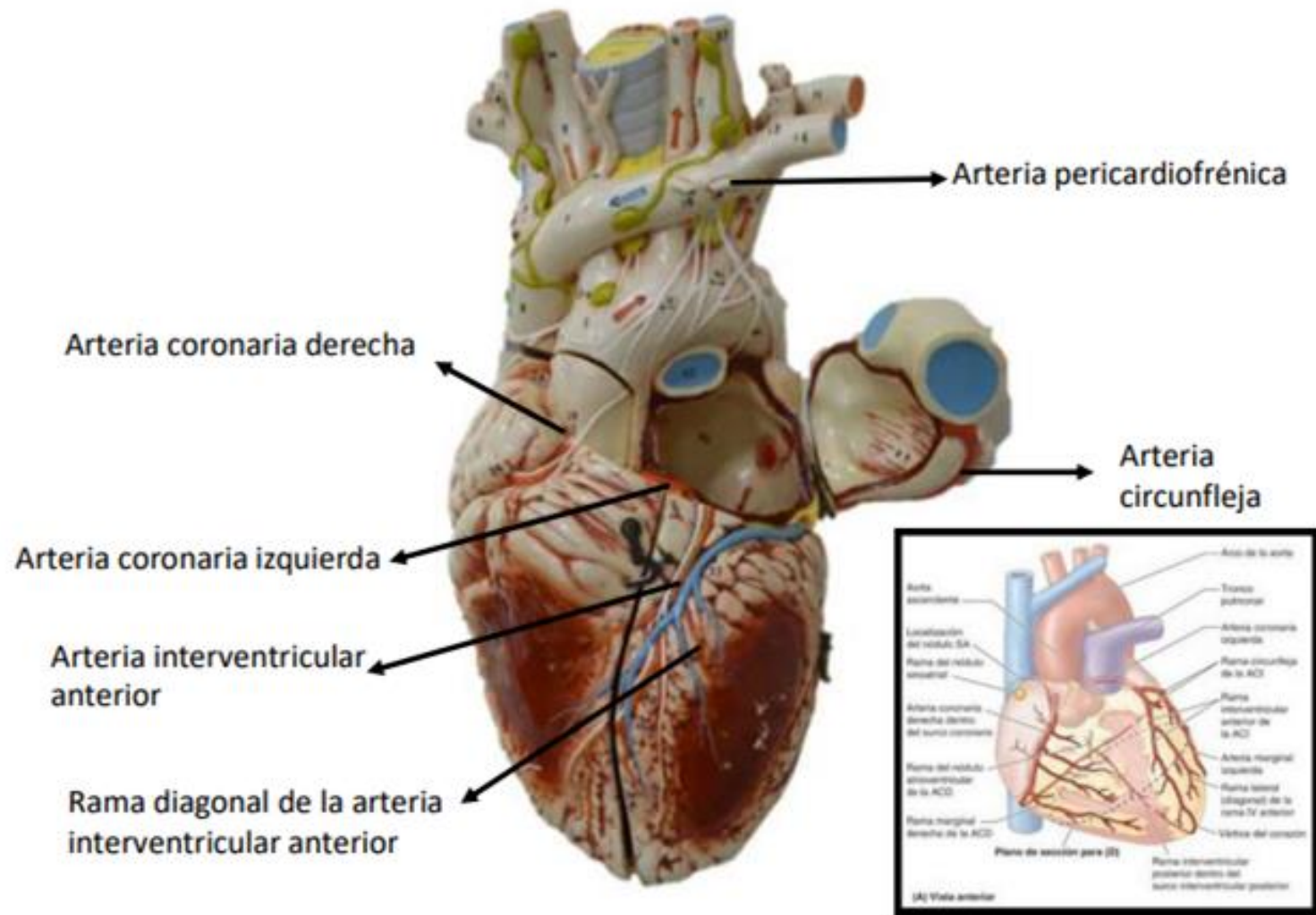
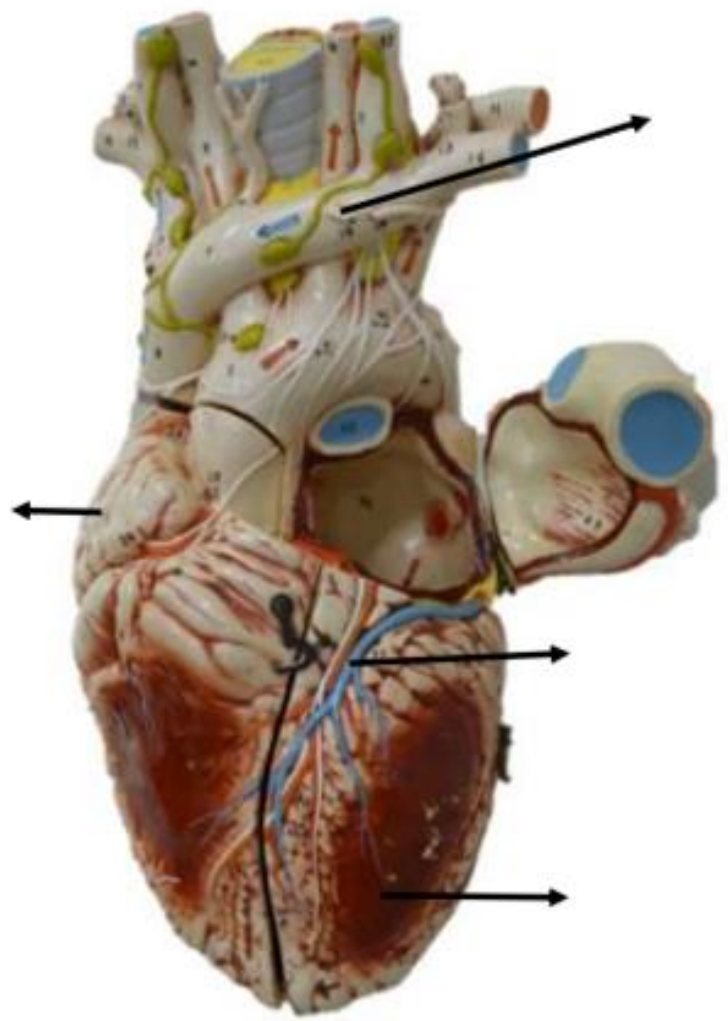
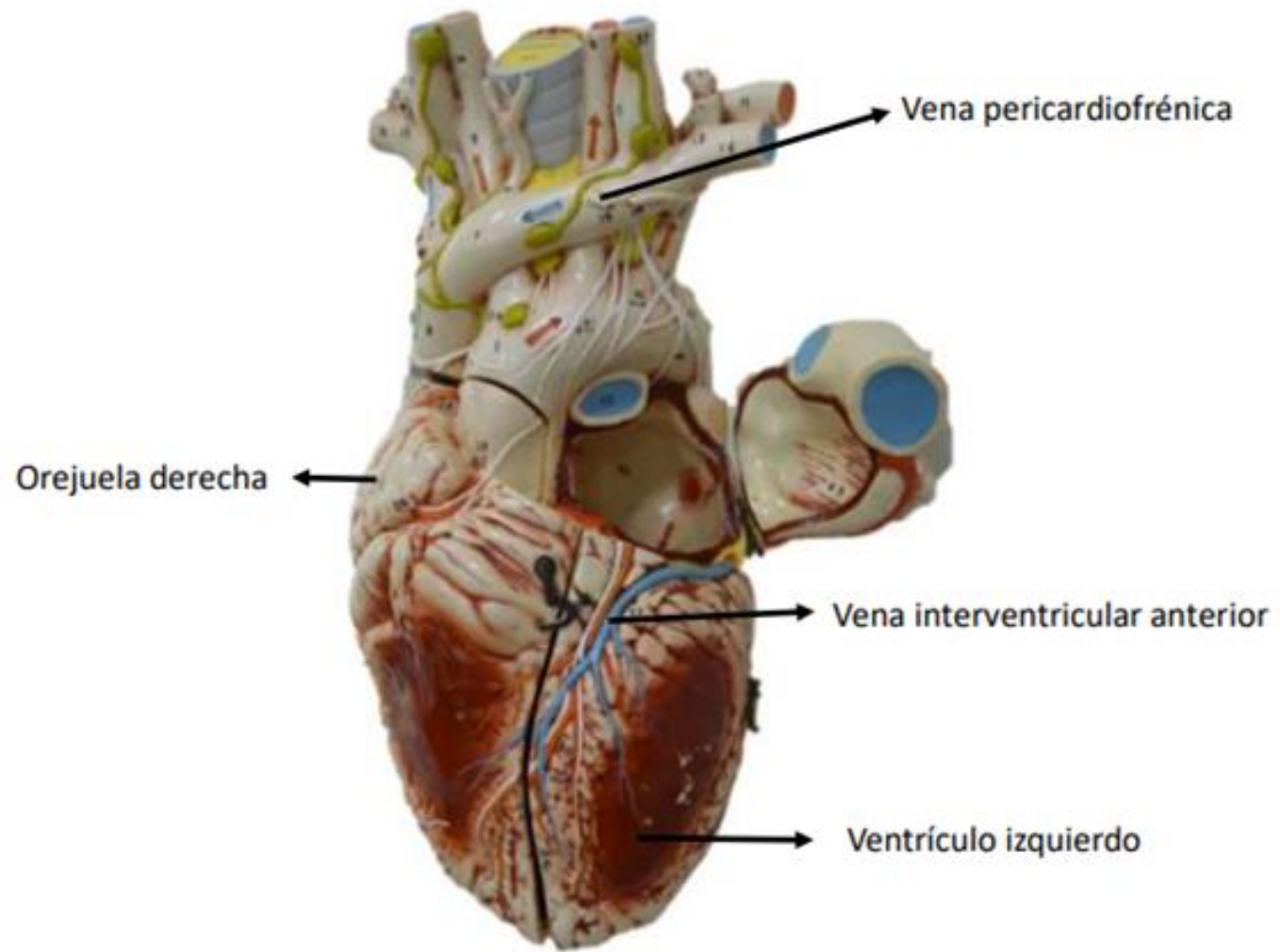
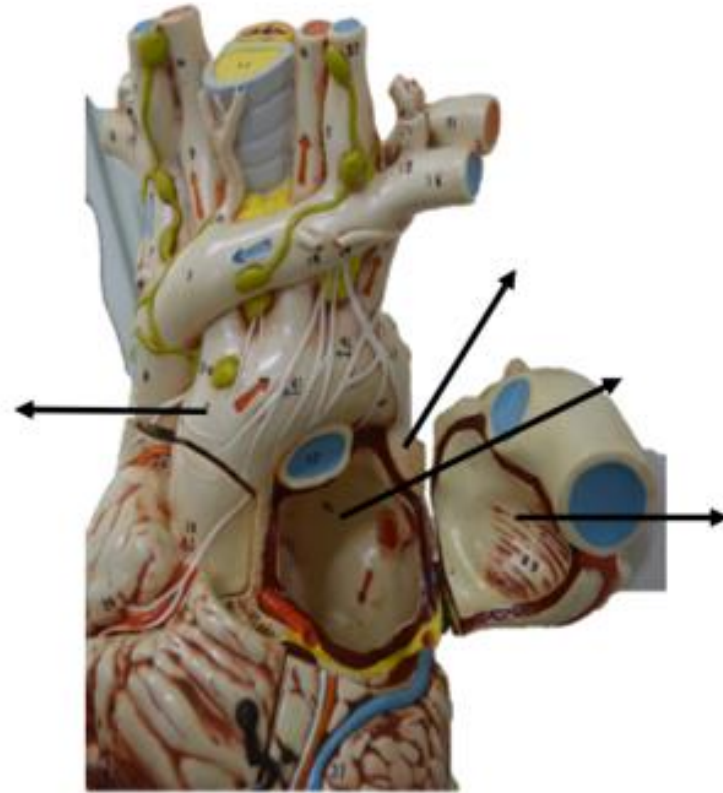
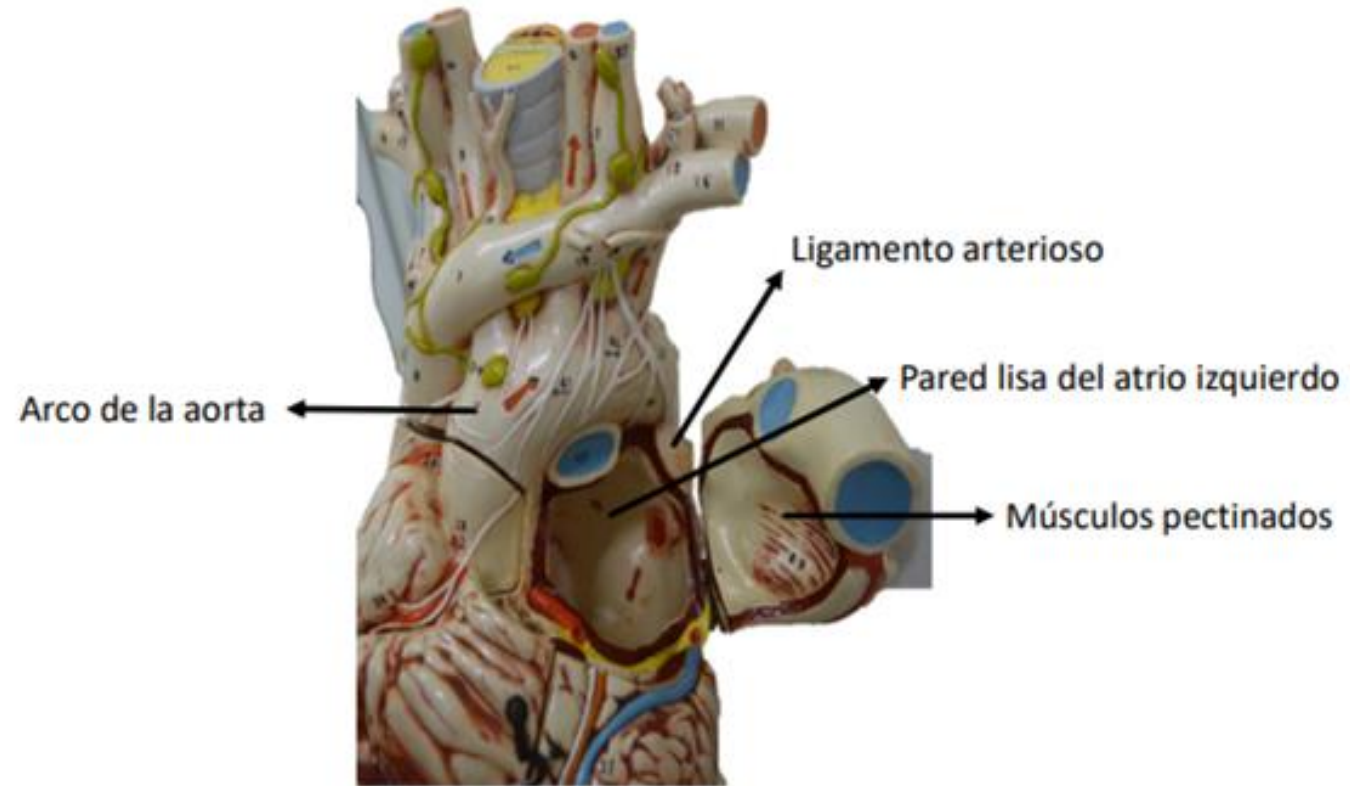


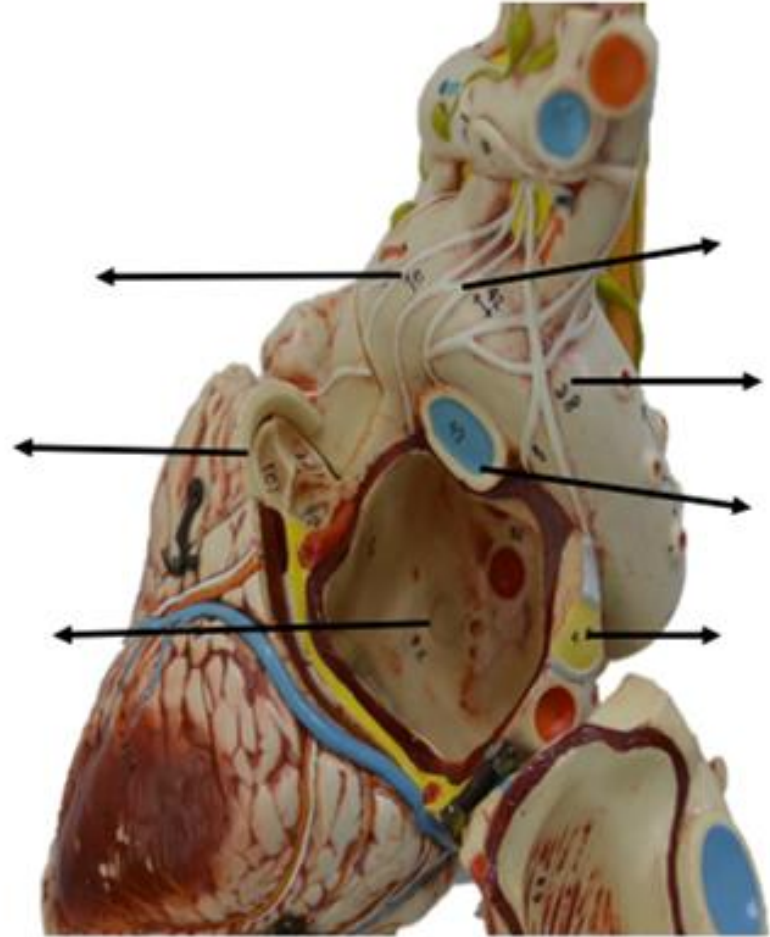
Figura: 4-60. Arterias coronarias.

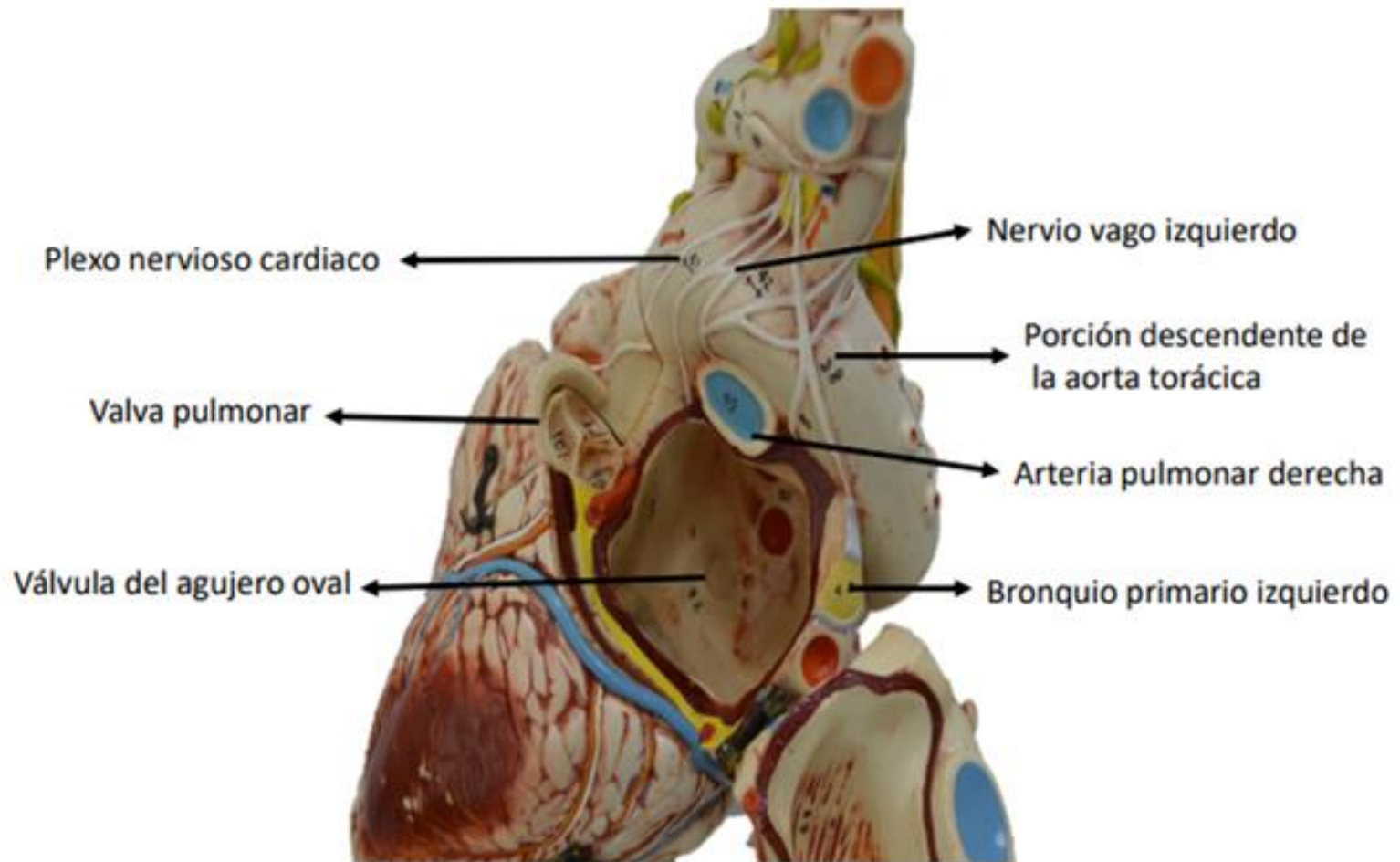












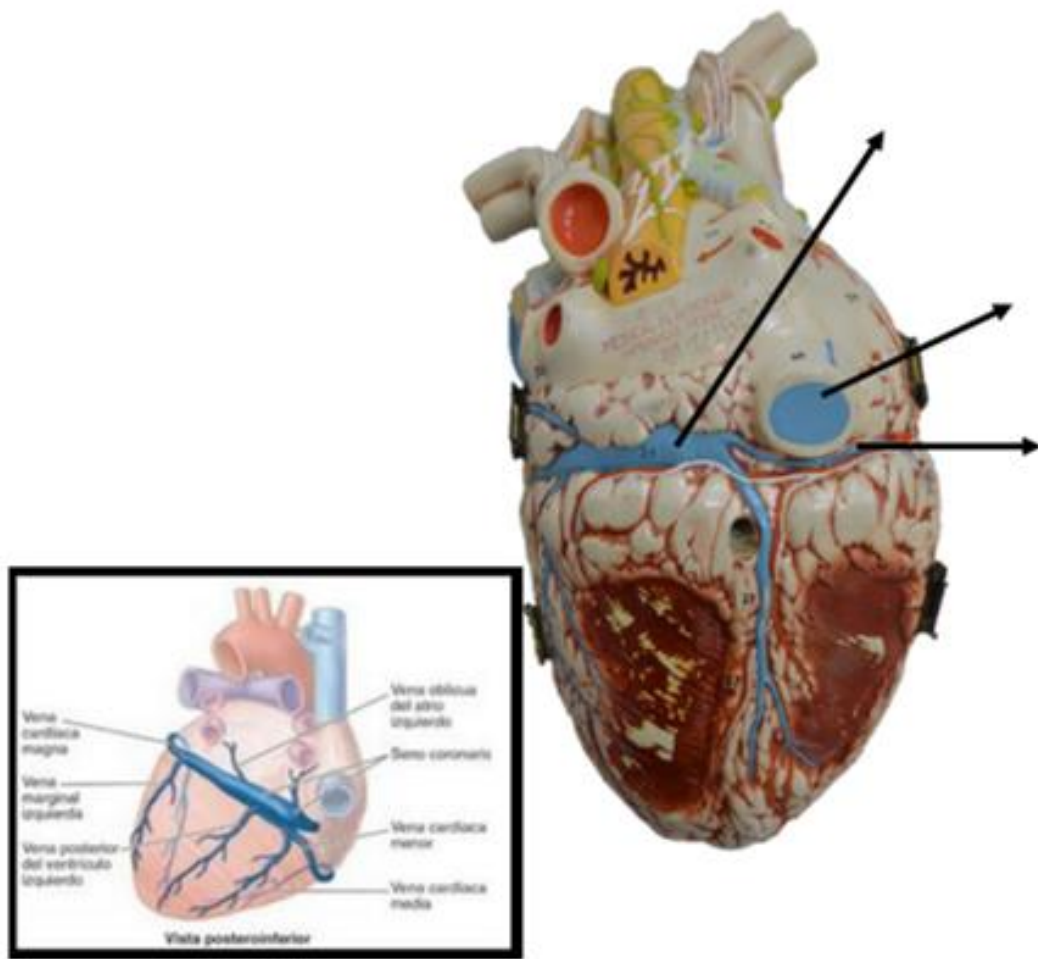


Figura: 4-62. Venas del corazón.c

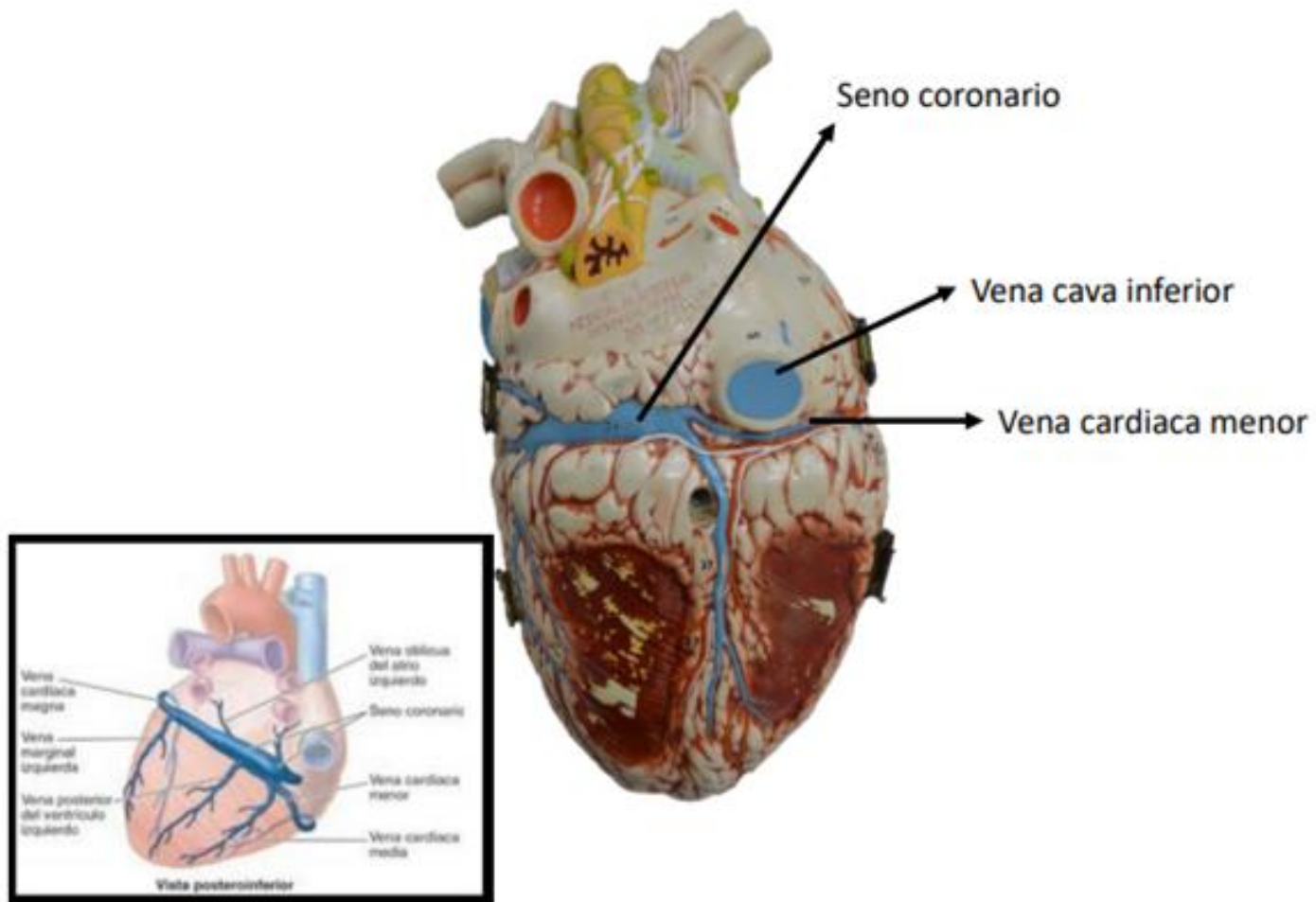
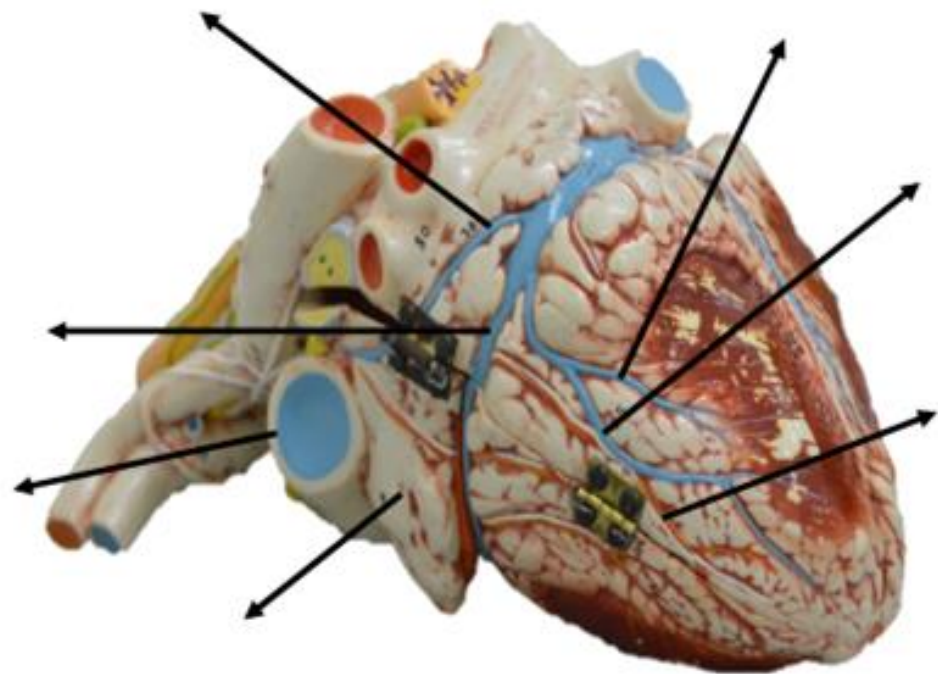
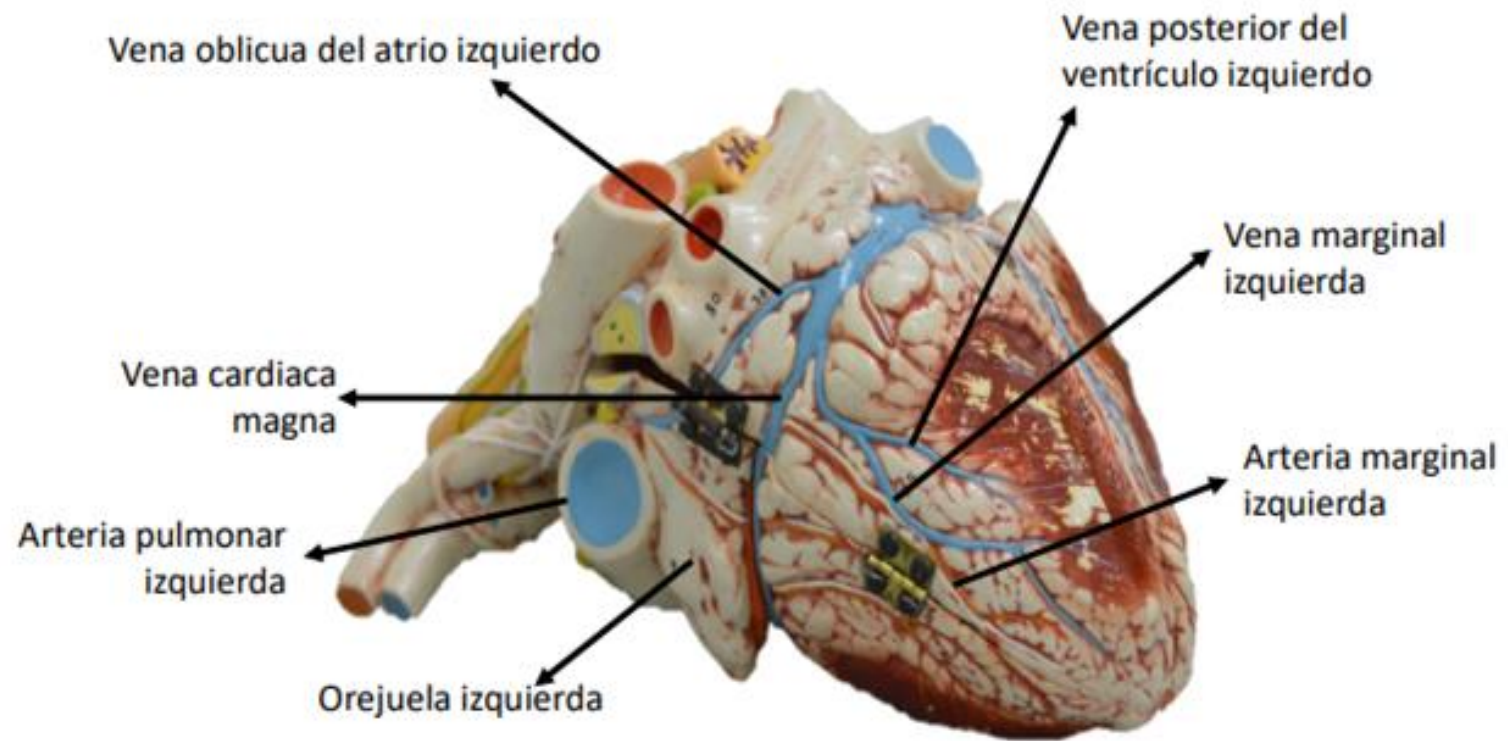
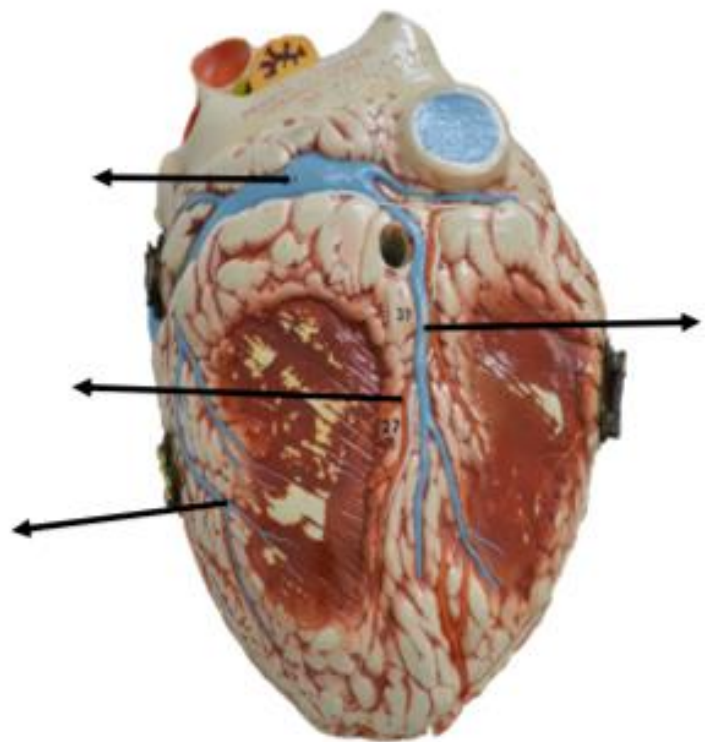
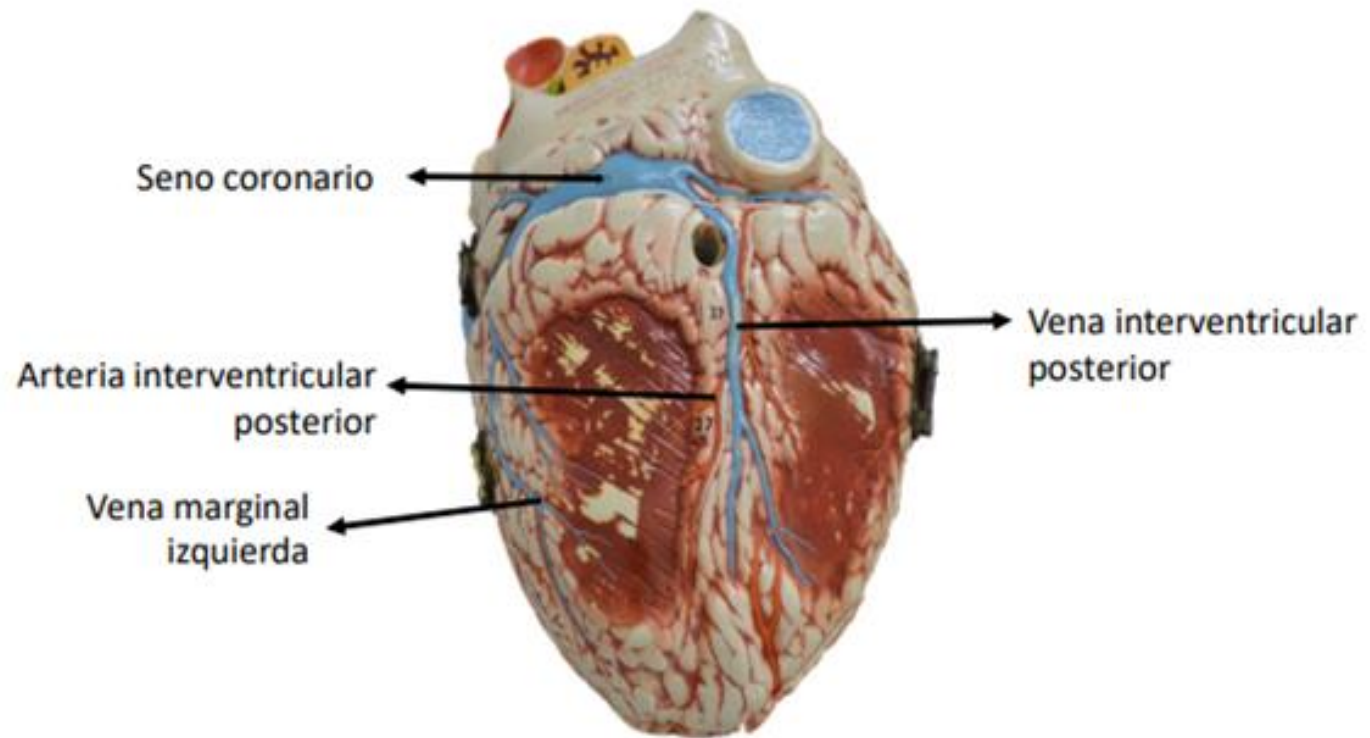


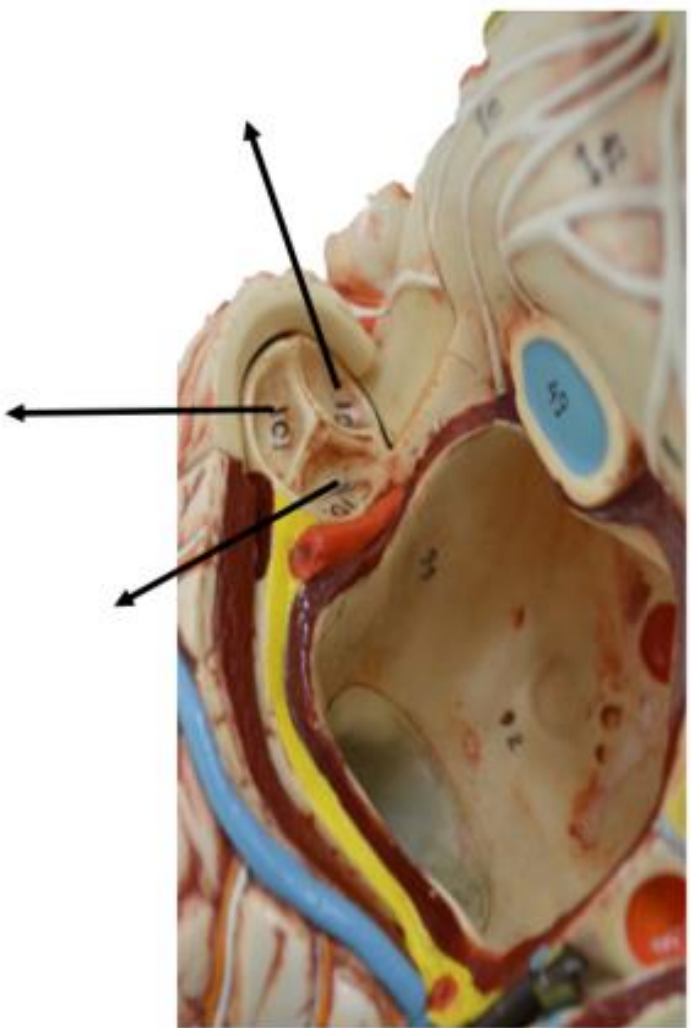
Figura: 4-62. Venas del corazón.







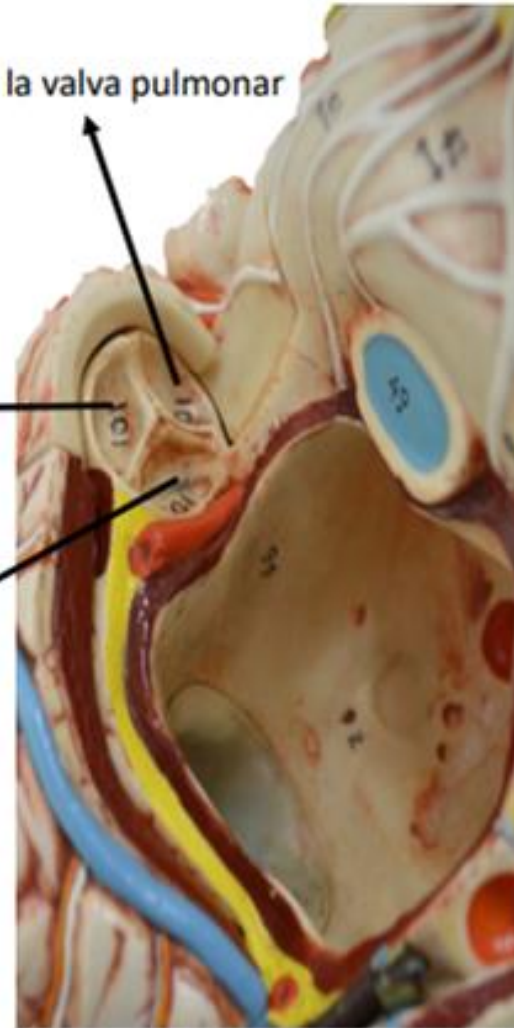


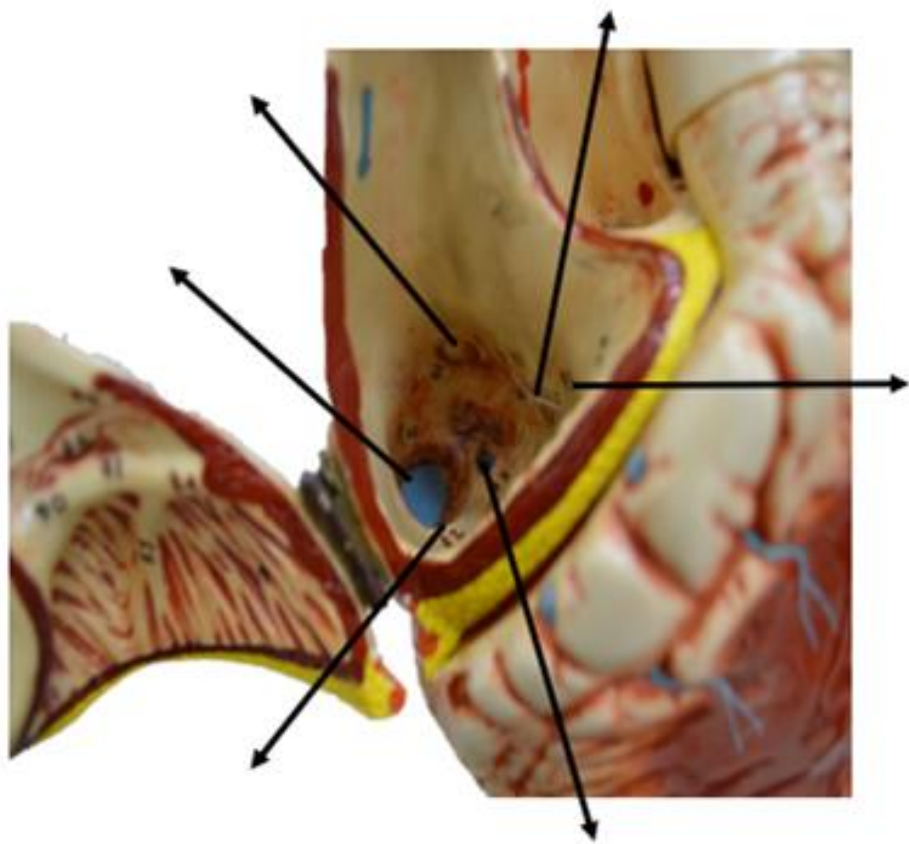


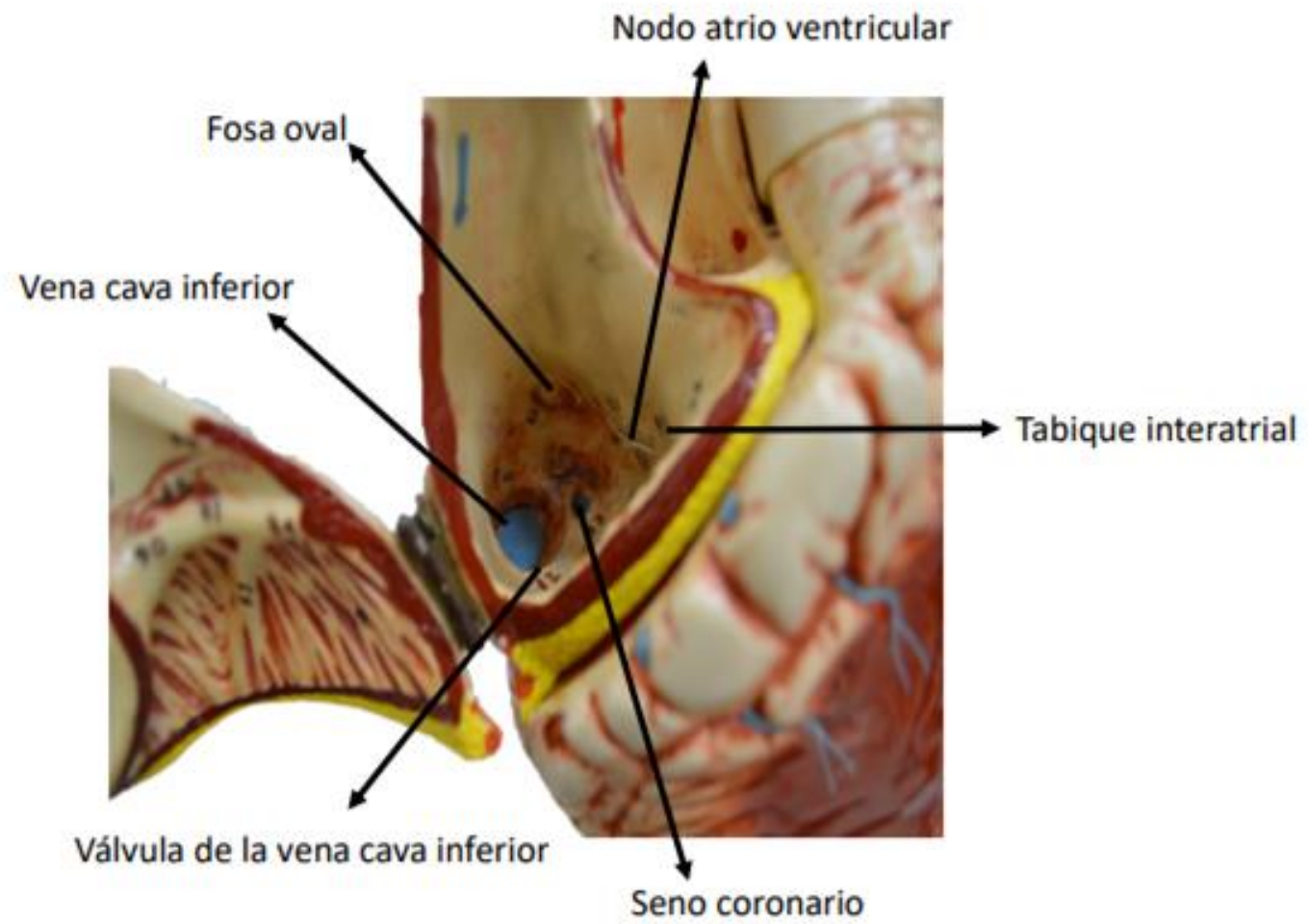
Válvula posterior derecha de la valva pulmonar

Válvula anterior de la valva pulmonar

Válvula posterior izquierda de la valva pulmonar







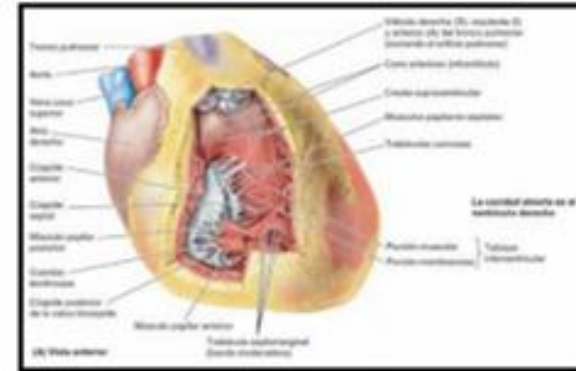
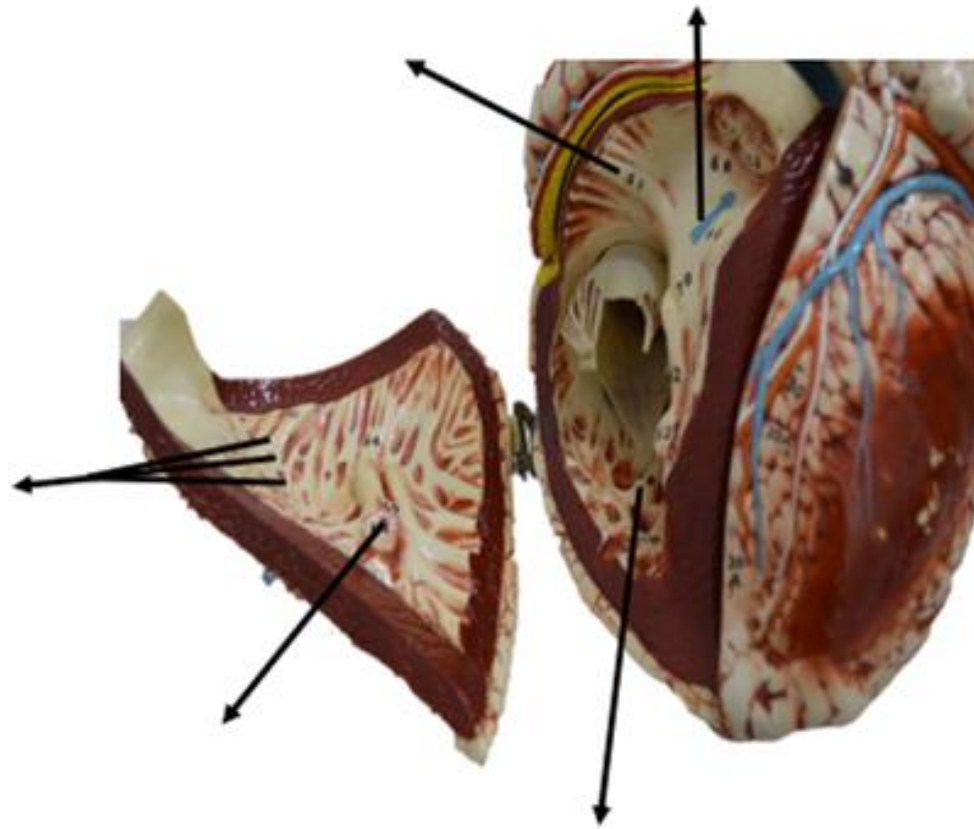


Figura: 4-55. Interior del ventrículo derecho del corazón.

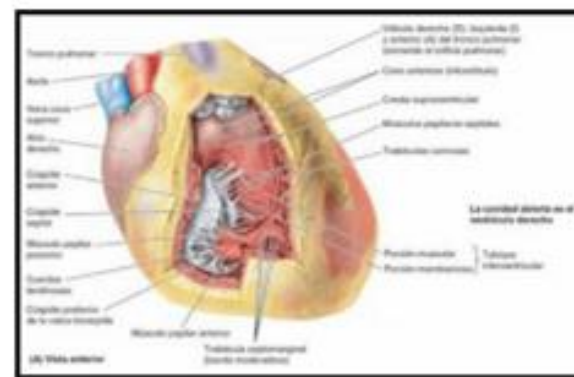
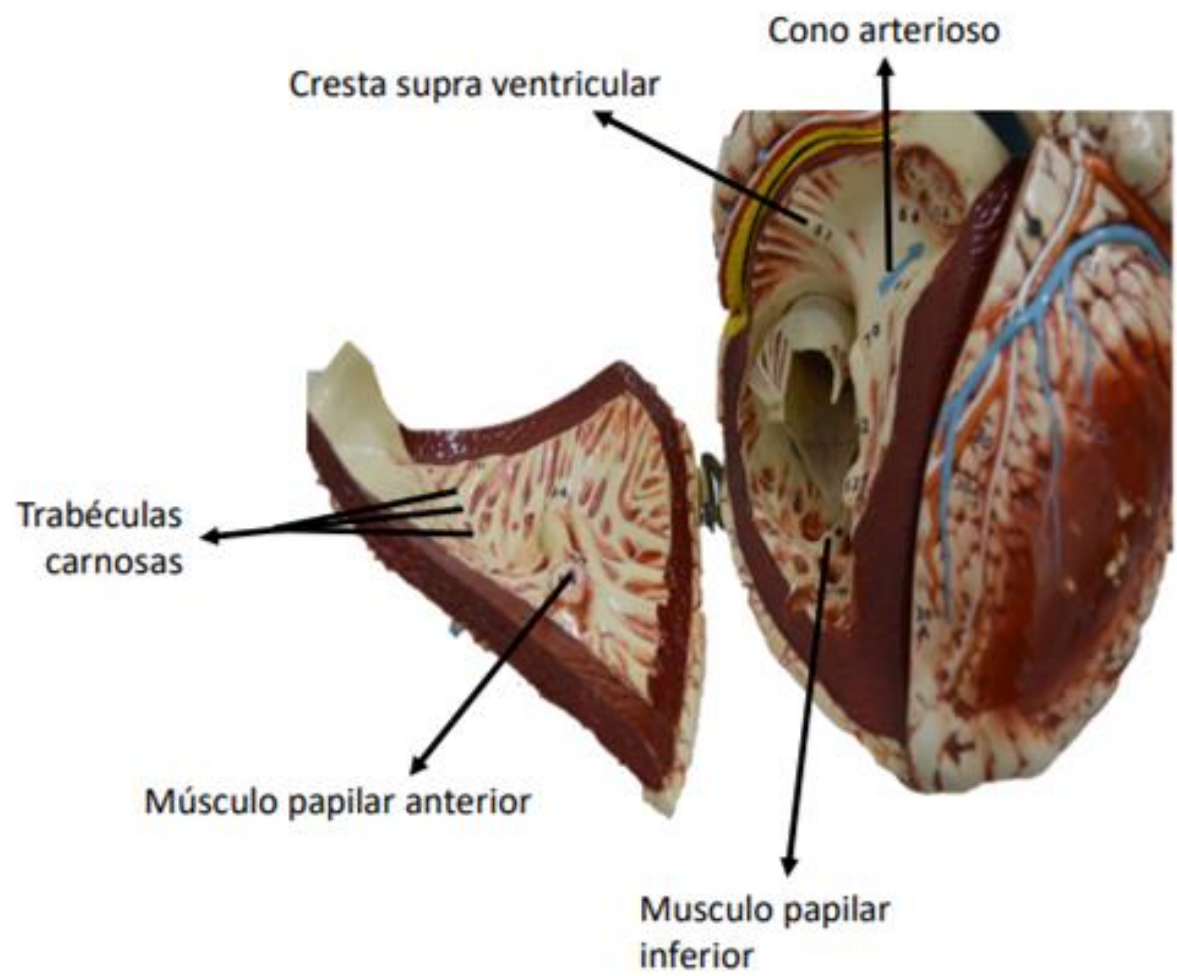
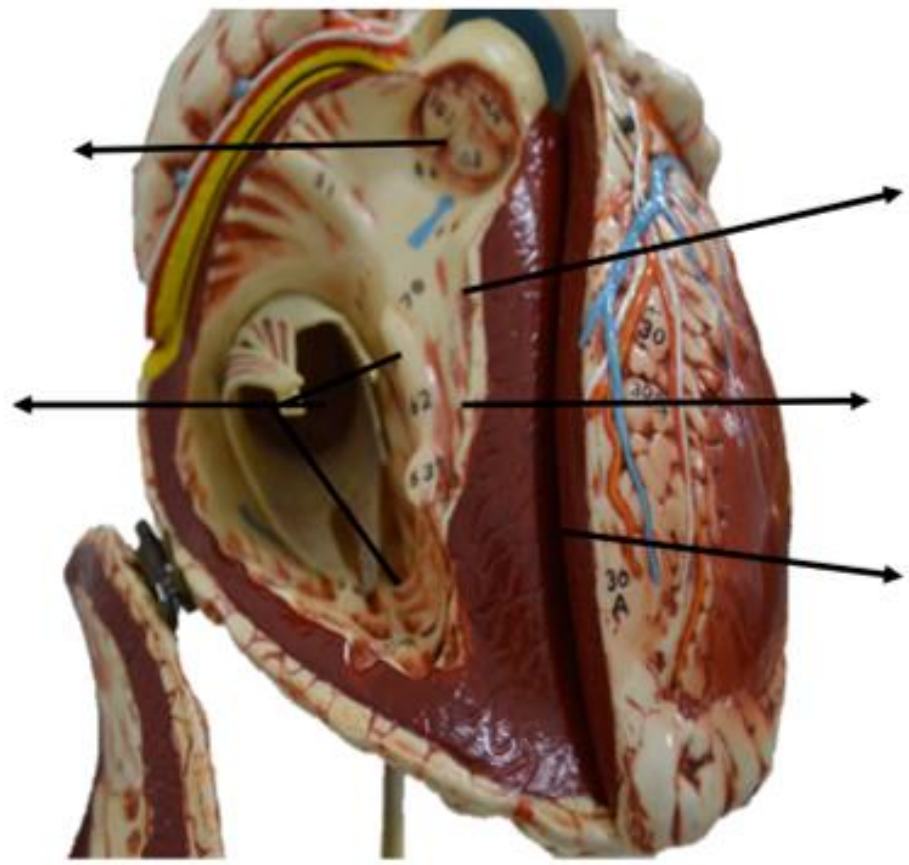
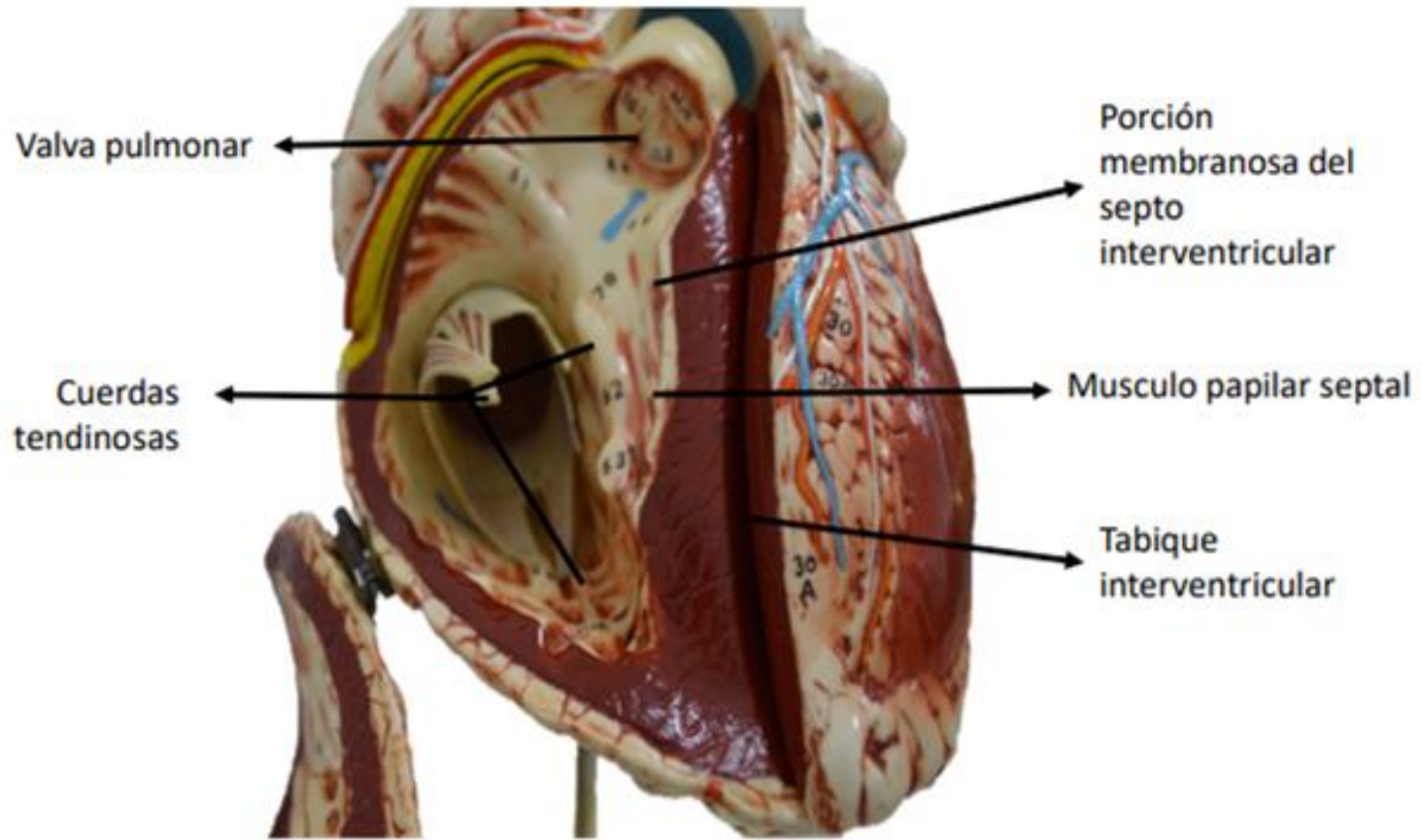
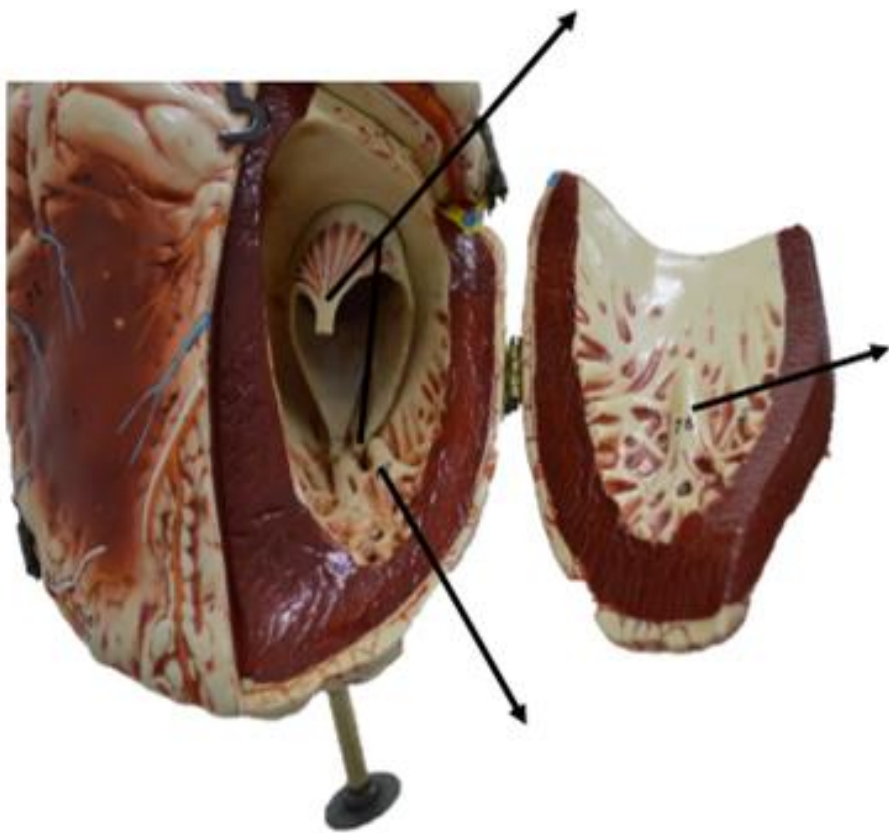


Figura: 4-55. Interior del ventrículo derecho del corazón.

Fuente: Moore KL, Dalley AF, Agur A MR; Fundamentos de anatomía con orientación clínica. 8a Ed. Barcelona: Wolters kluwer Health; 2018. Pagina, 691







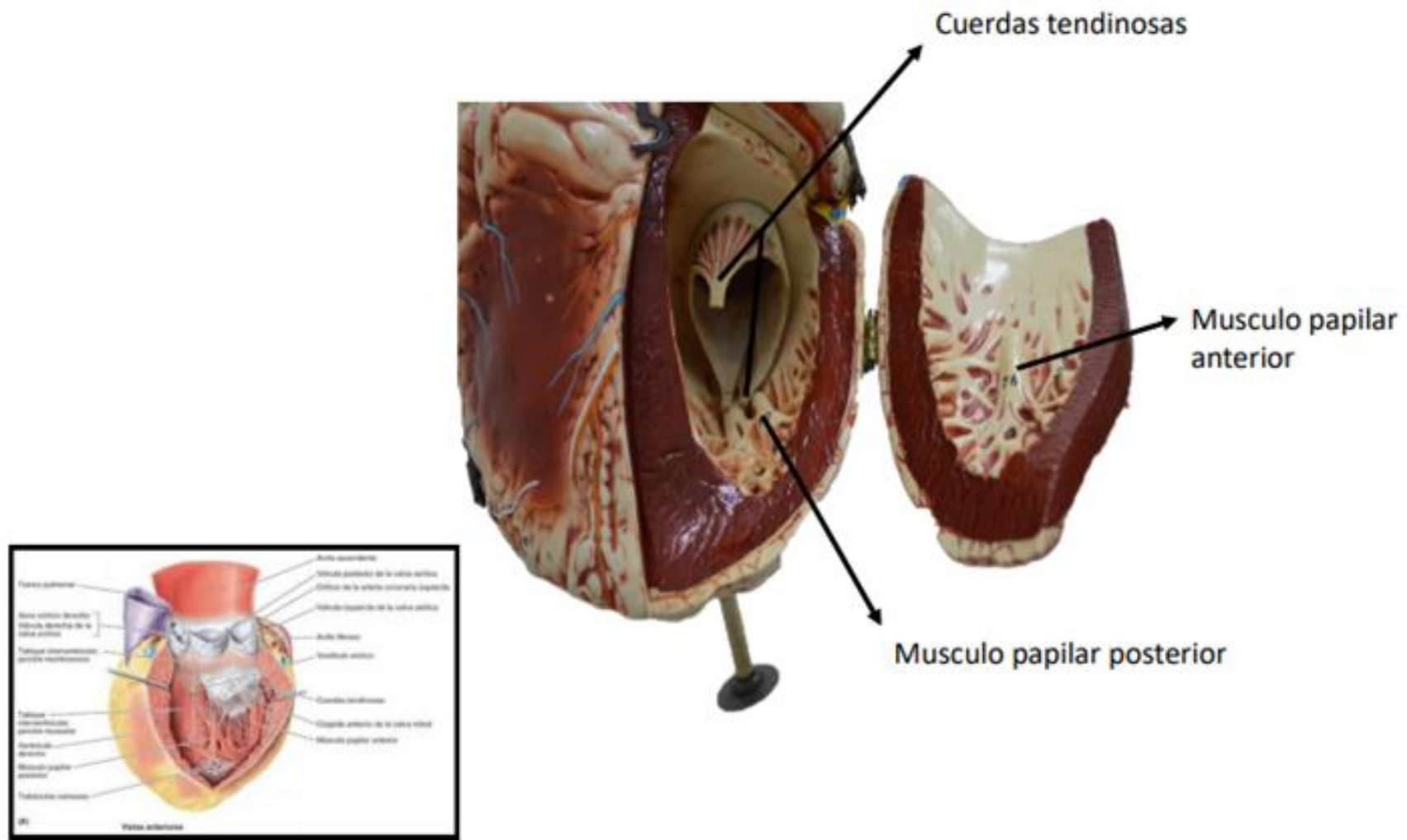


Figura: 4-58. Vista interior y del tracto de salida del ventrículo izquierdo del corazón.

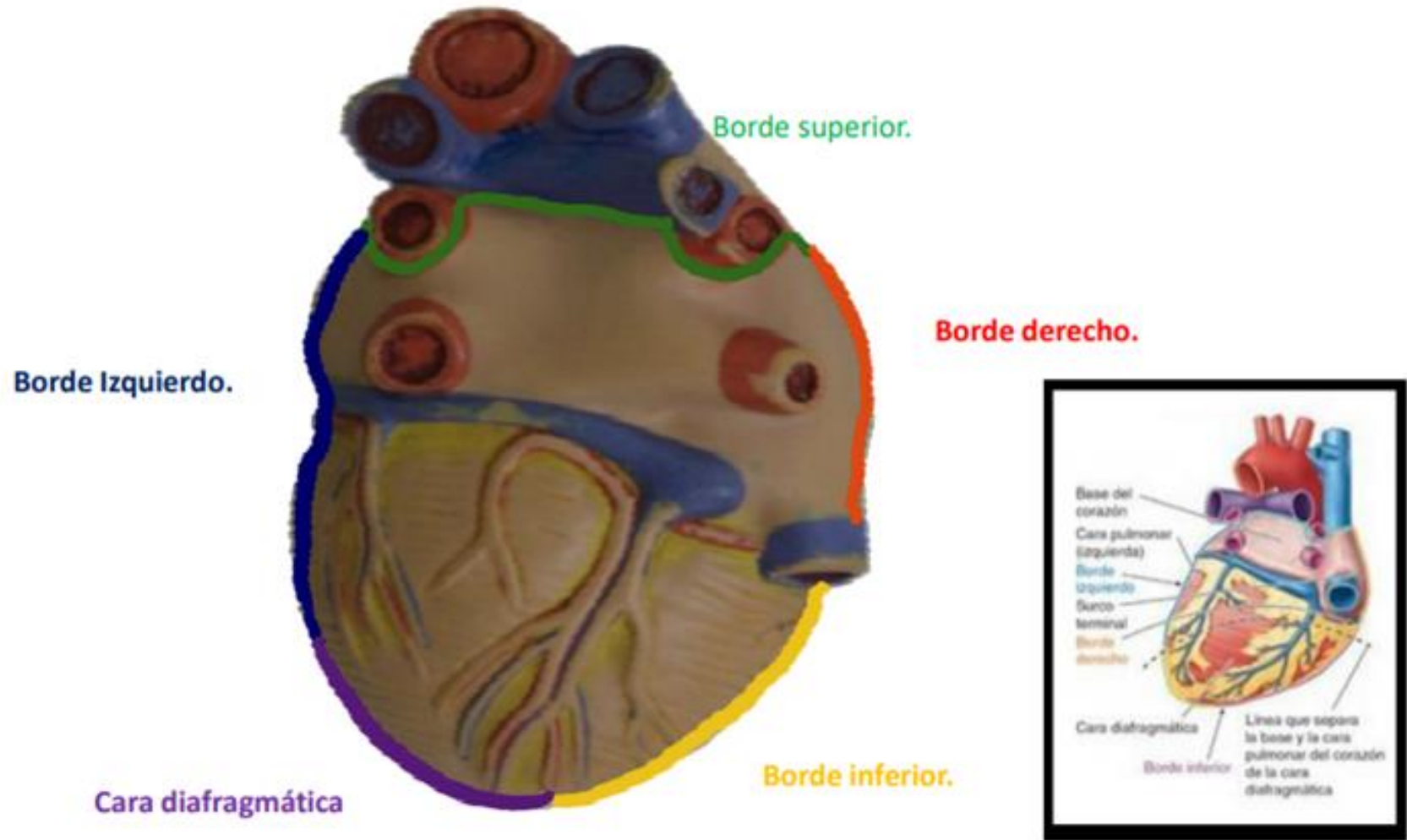
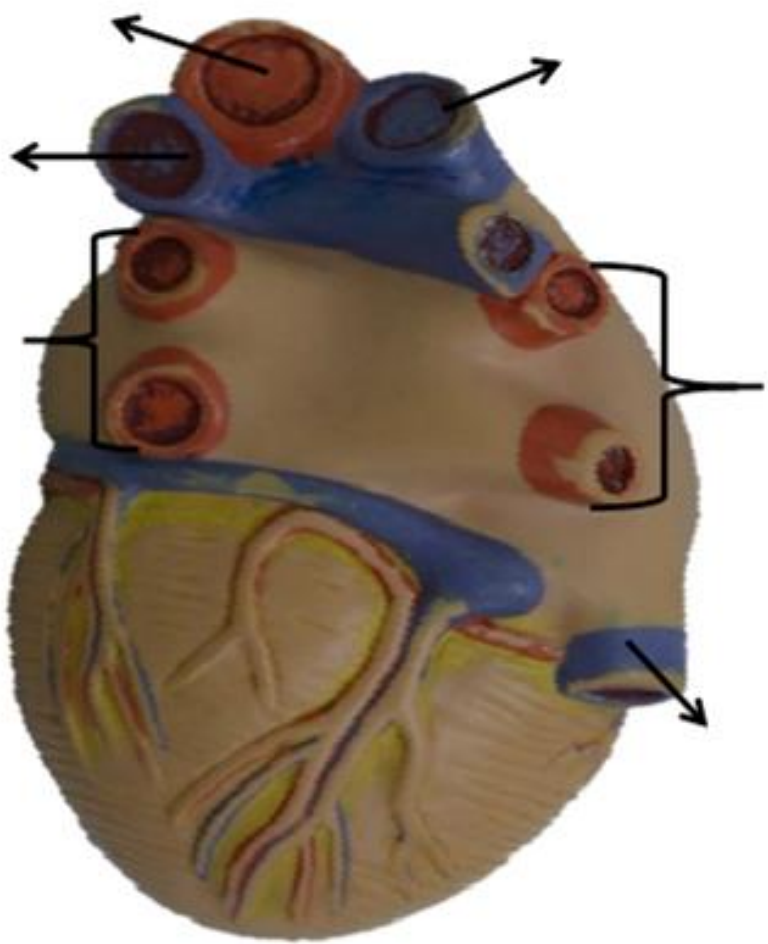


Figura: 4-53. Forma, orientación, caras y bordes del corazón.

Fuente: Moore KL, Dalley AF, Agur A MR; Fundamentos de anatomía con orientación clínica. 8a Ed. Barcelona: Wolters kluwer Health; 2018. Pagina, 689



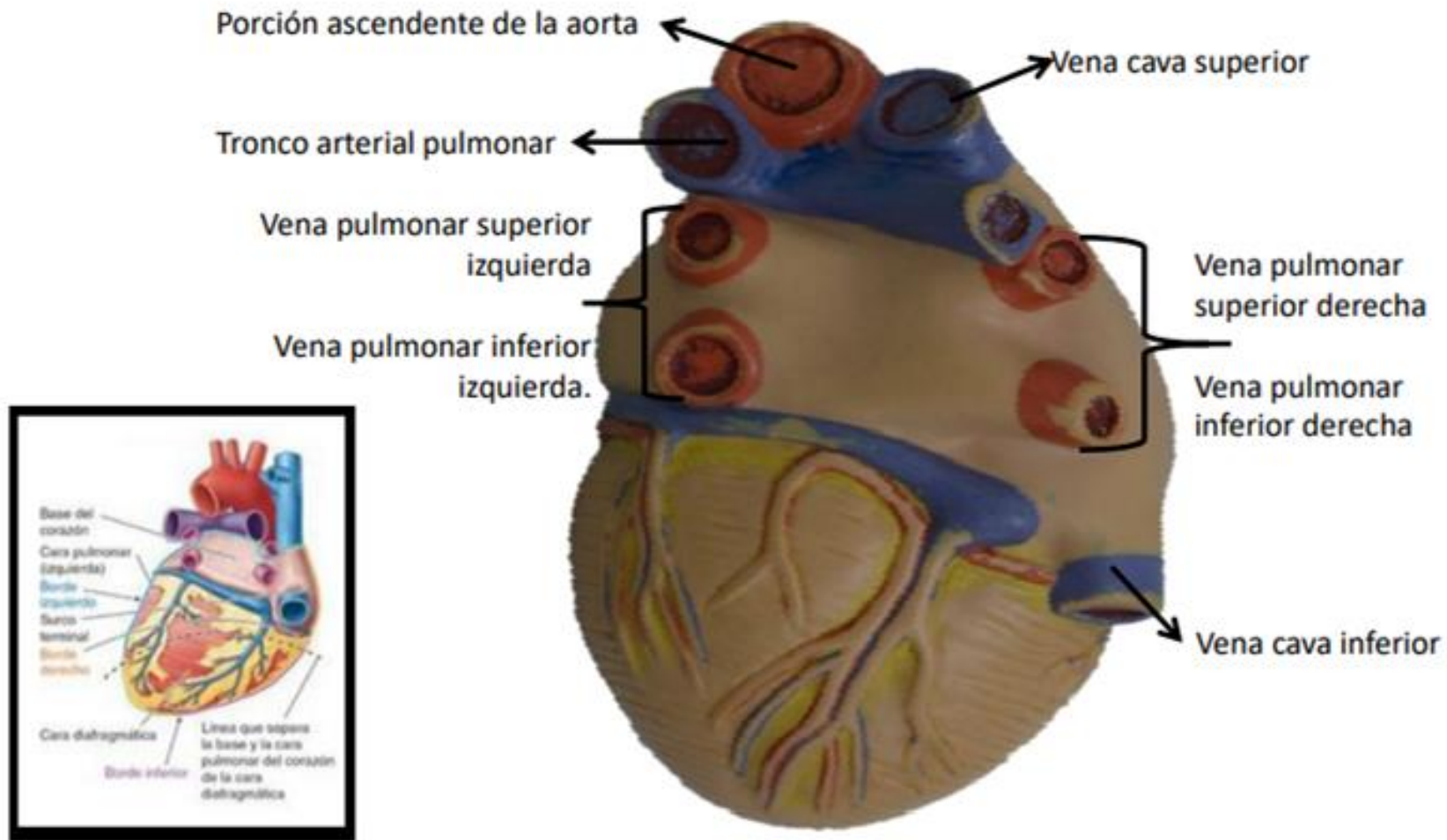
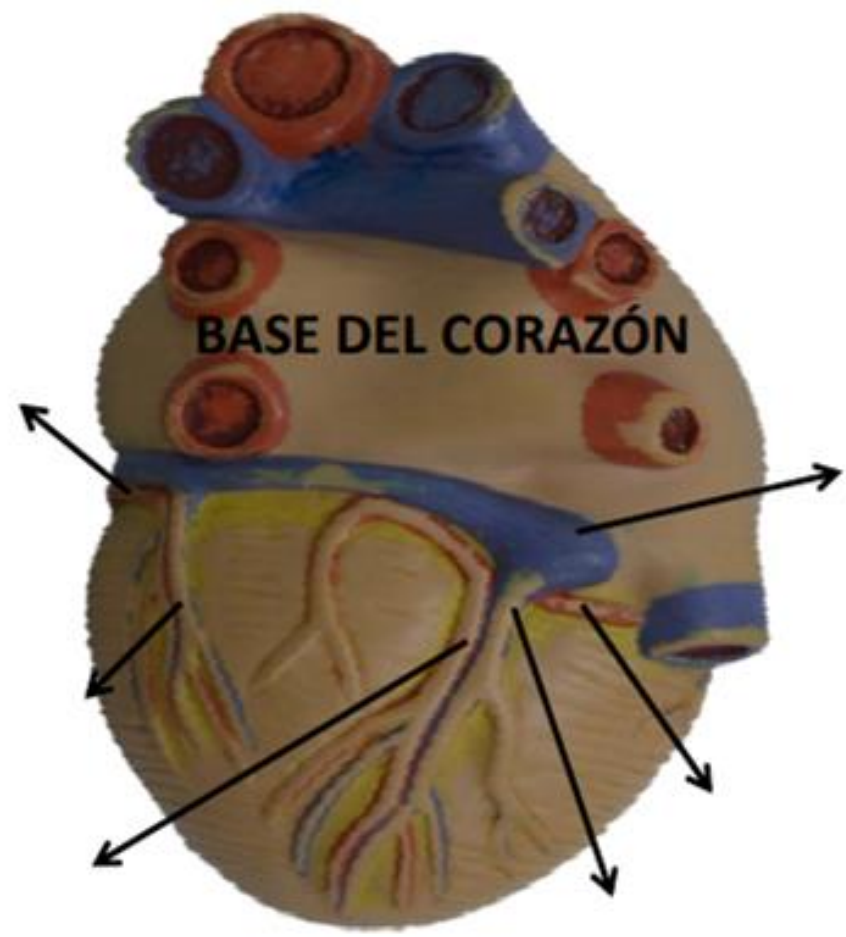
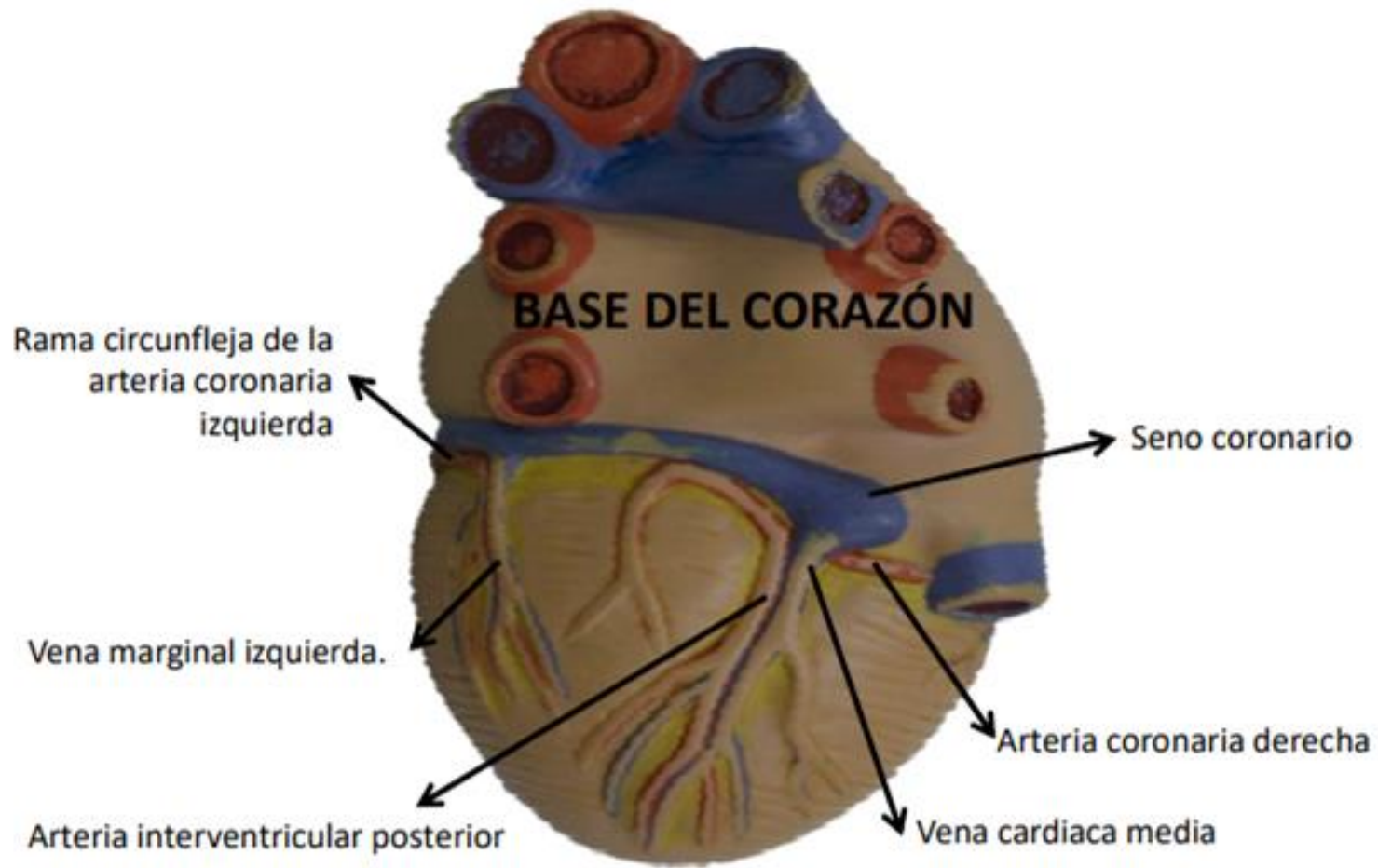


Figura: 4-53. Forma, orientación, caras y bordes del corazón.



BASE DEL CORAZÓN



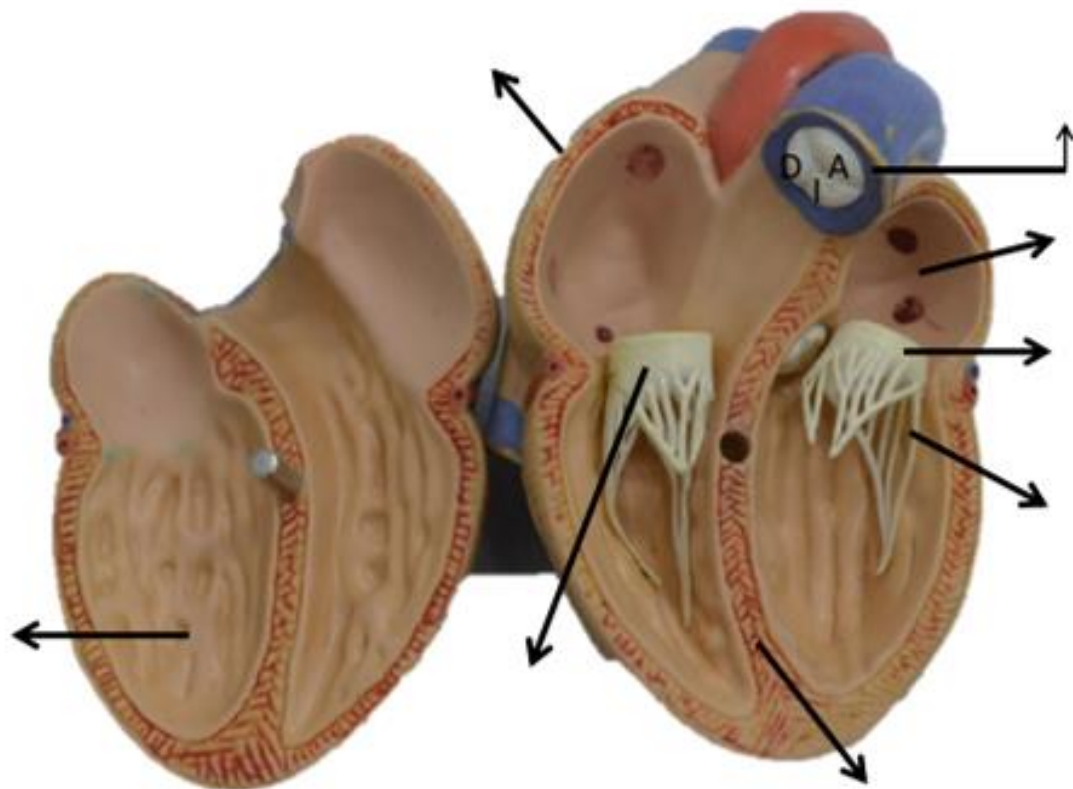
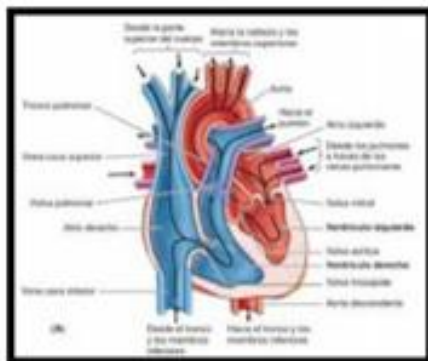


Figura: 4-49. Ciclo cardíaco.

Fuente: Moore KL, Dalley AF, Agur A MR; Fundamentos de anatomía con orientación clínica. 8a Ed. Barcelona: Wolters kluwer Health; 2018. Pagina, 683

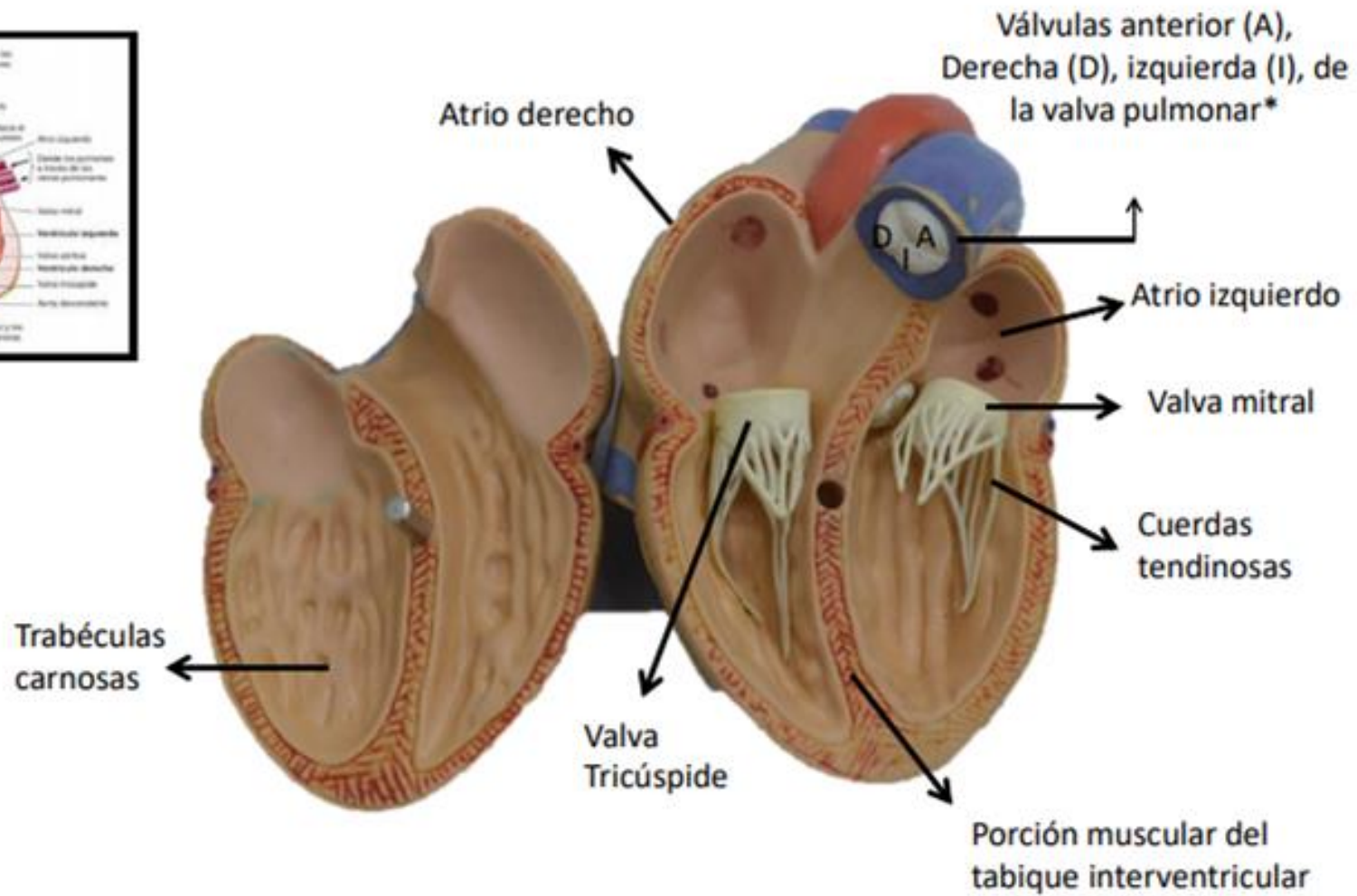
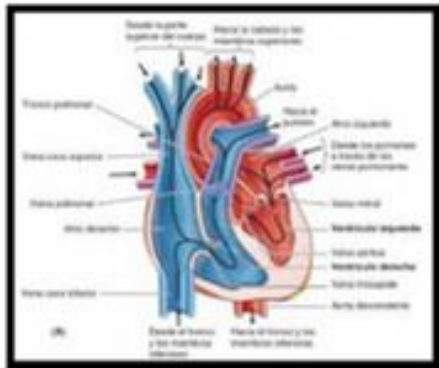
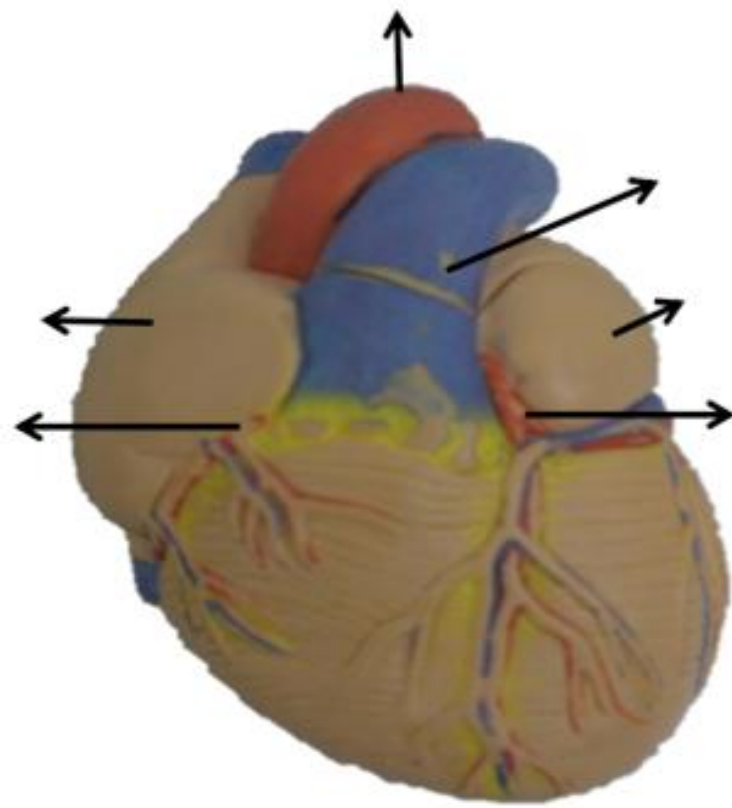


Figura: 4-49. Ciclo cardíaco.



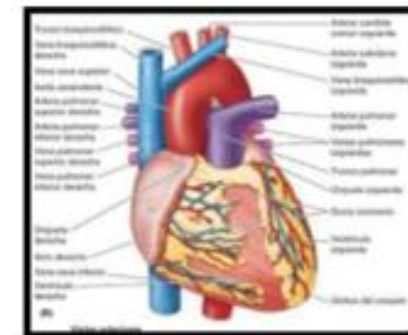
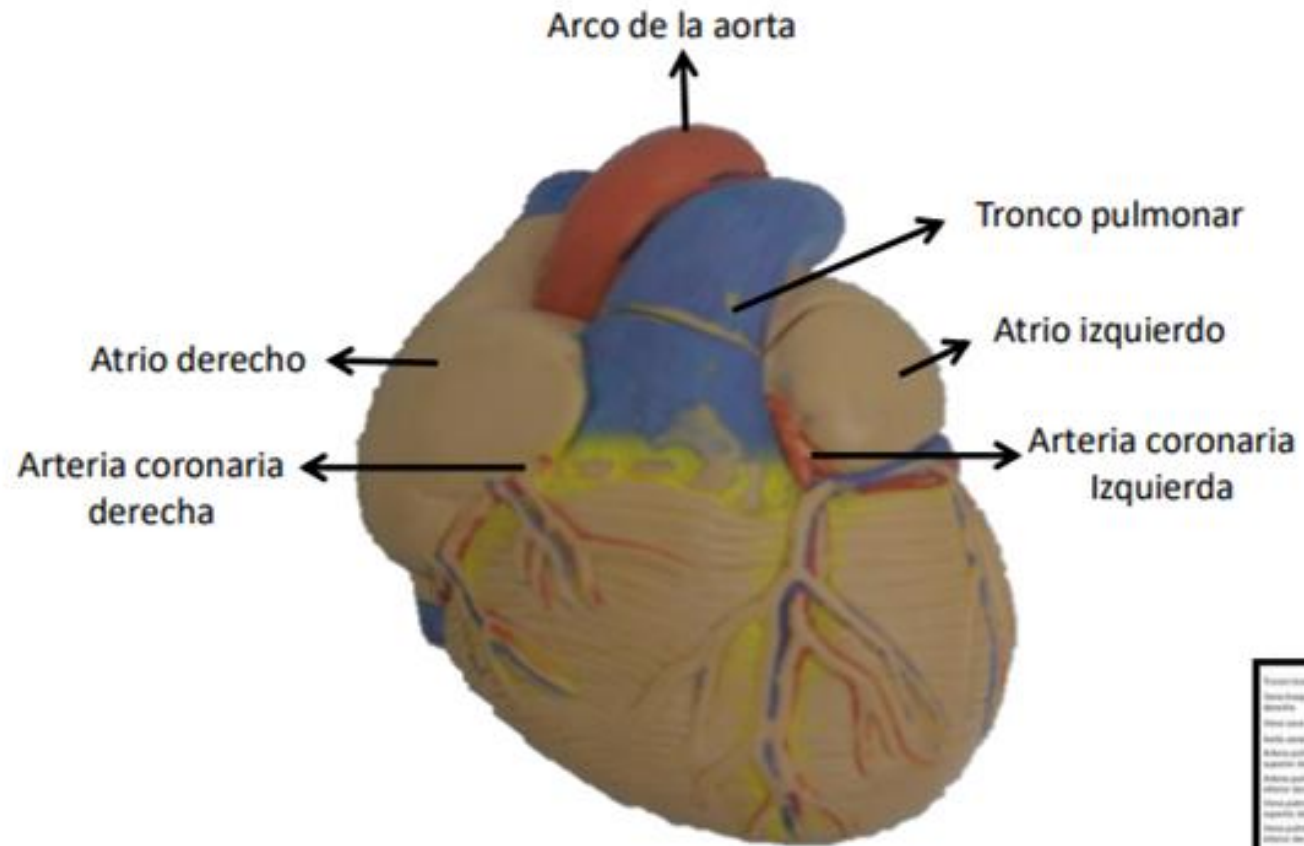
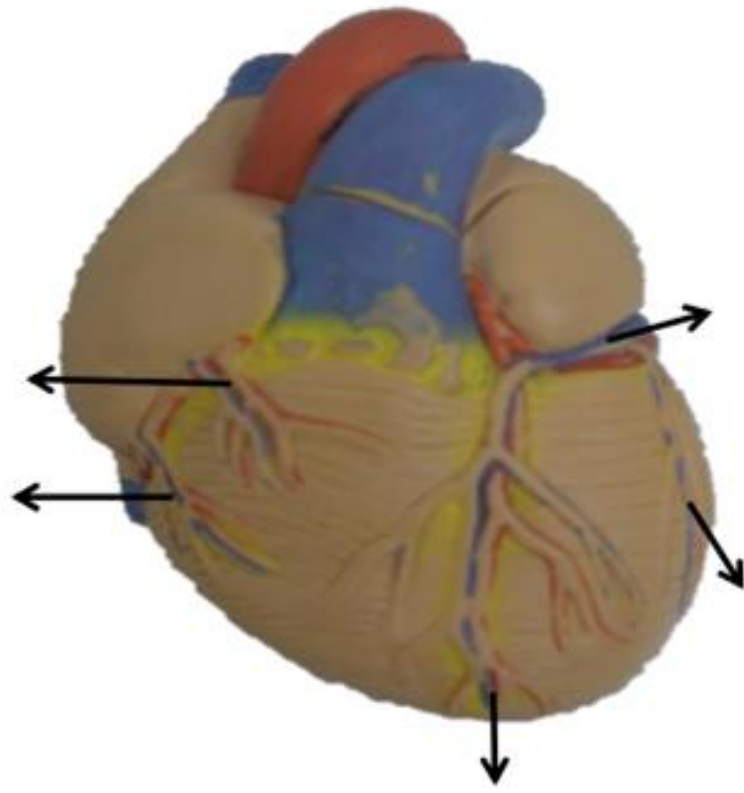
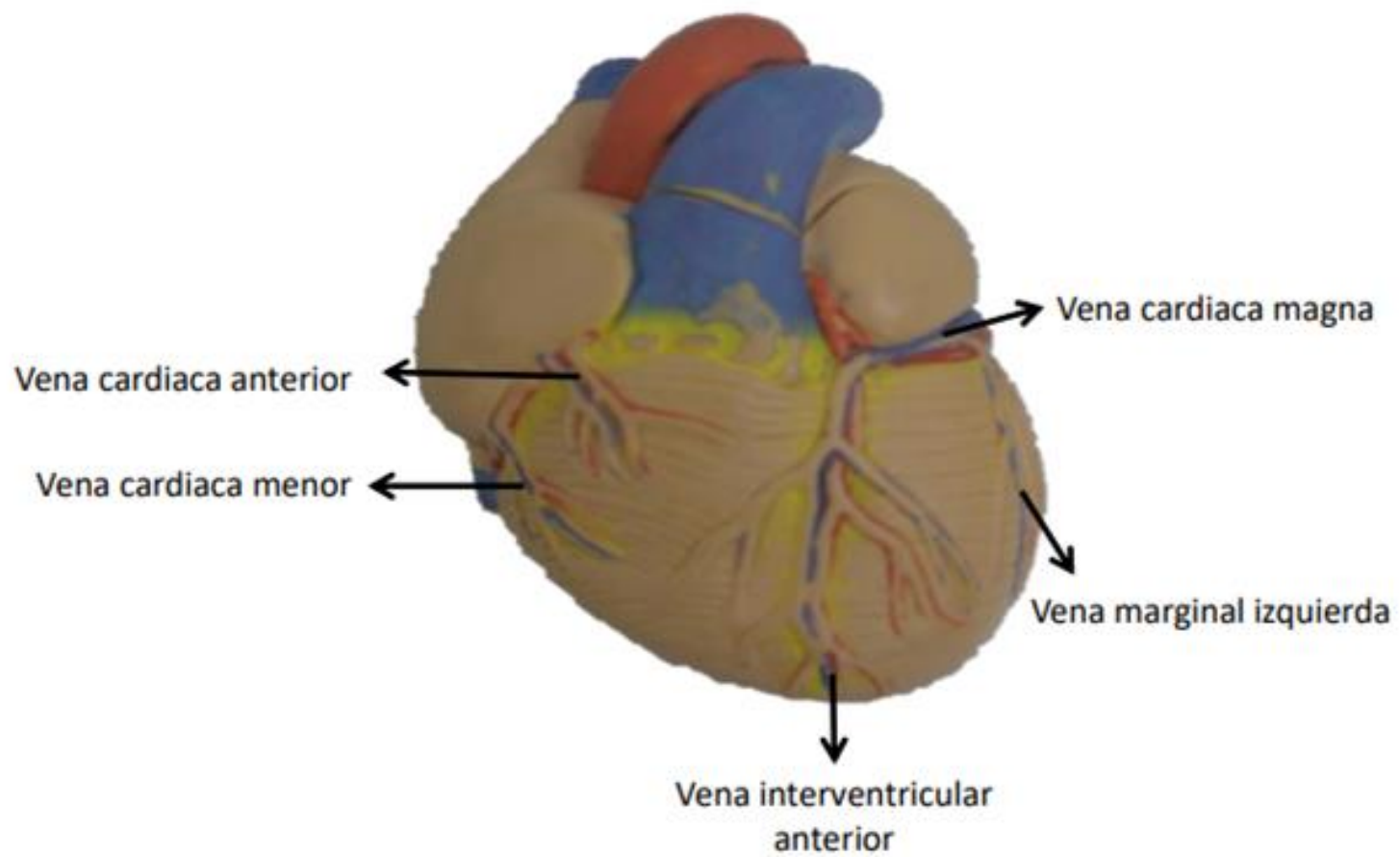


Figura: 4-53. Forma, orientación, caras y bordes del corazón.





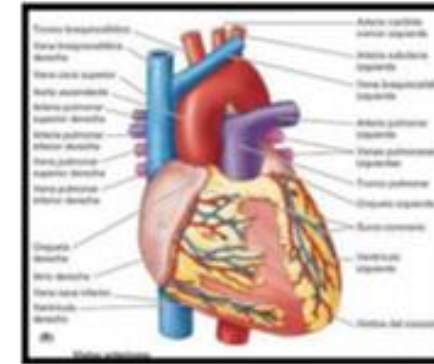
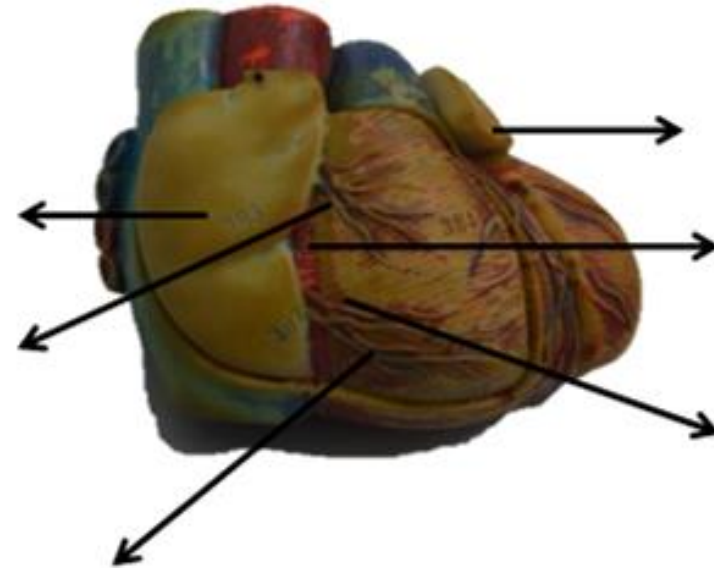


Figura: 4-53. Forma, orientación, caras y bordes del corazón.

Fuente: Moore KL, Dalley AF, Agur A MR; Fundamentos de anatomía con orientación clínica. 8a Ed. Barcelona: Wolters kluwer Health; 2018. Pagina, 689

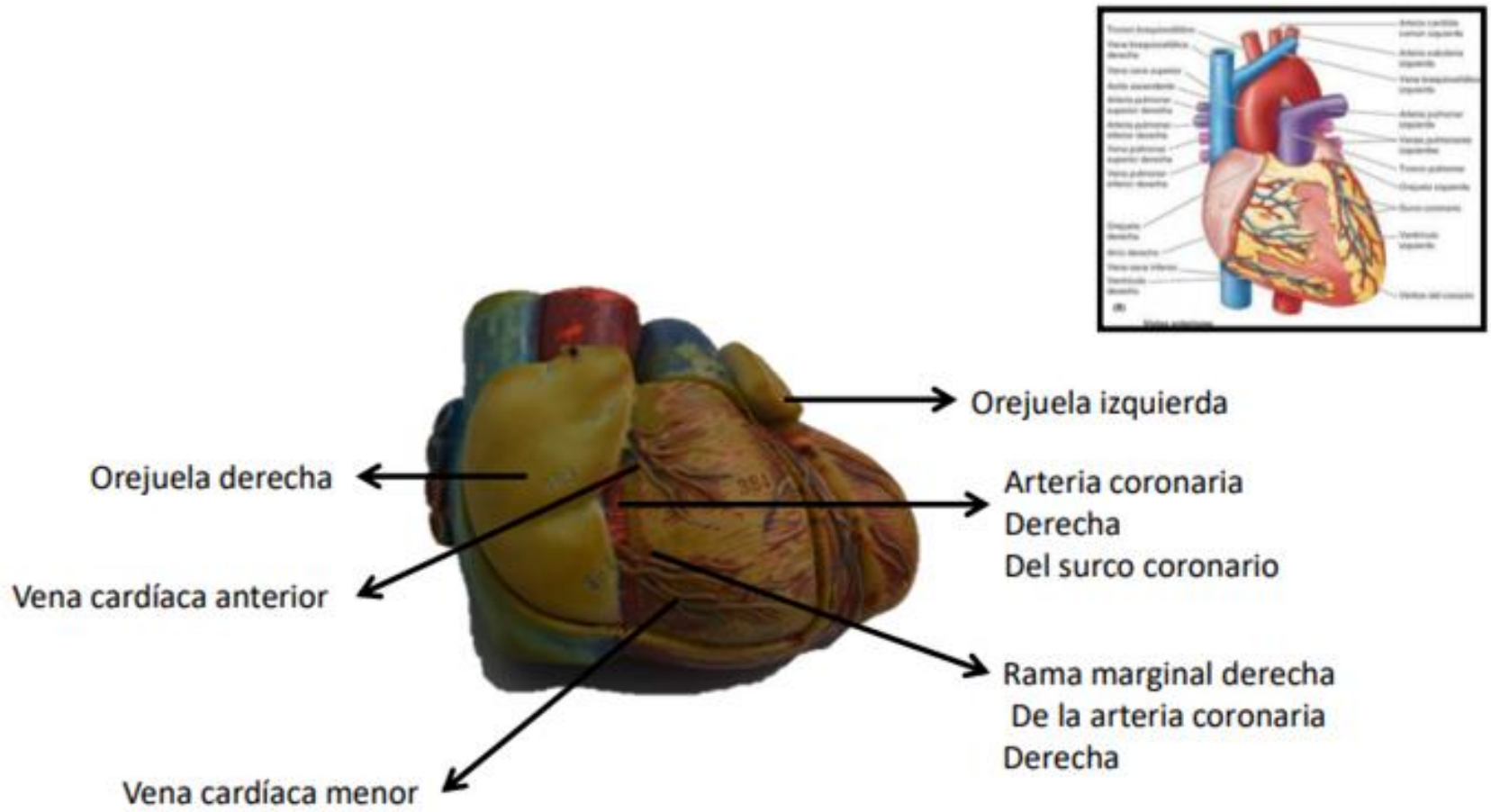
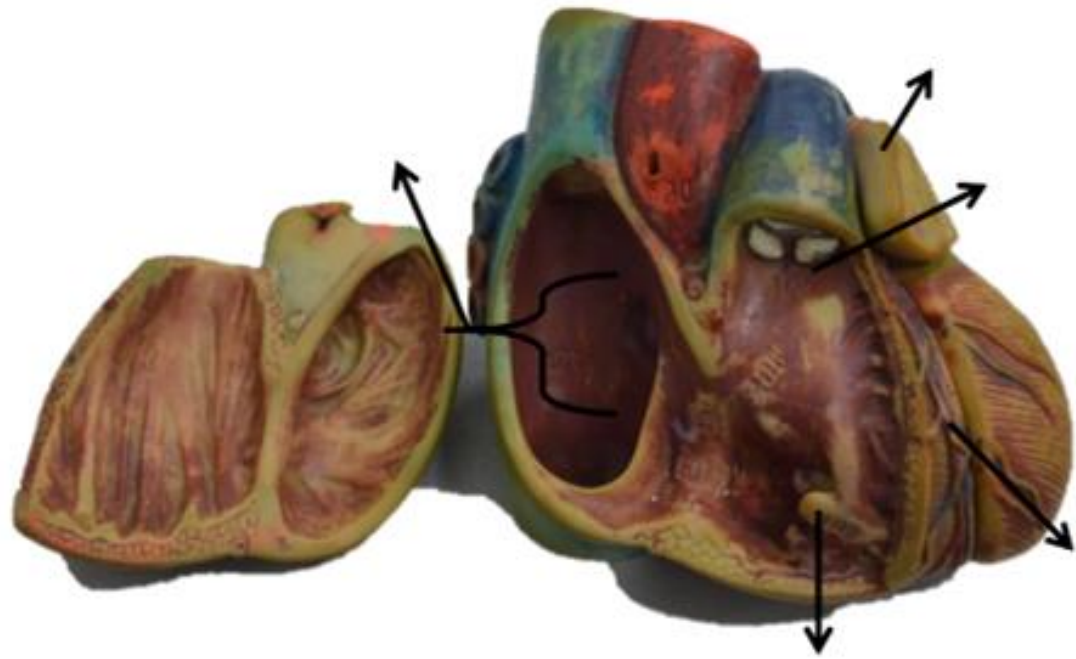
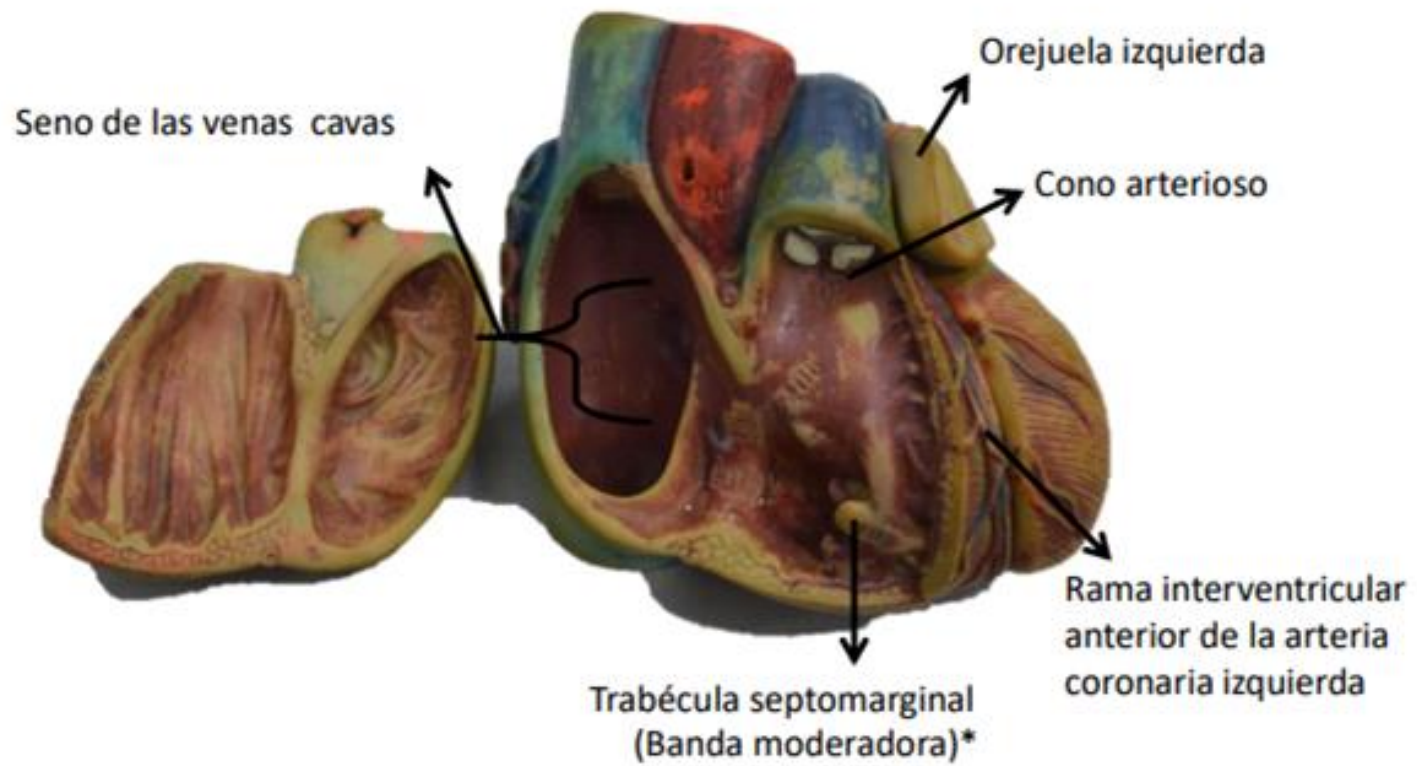
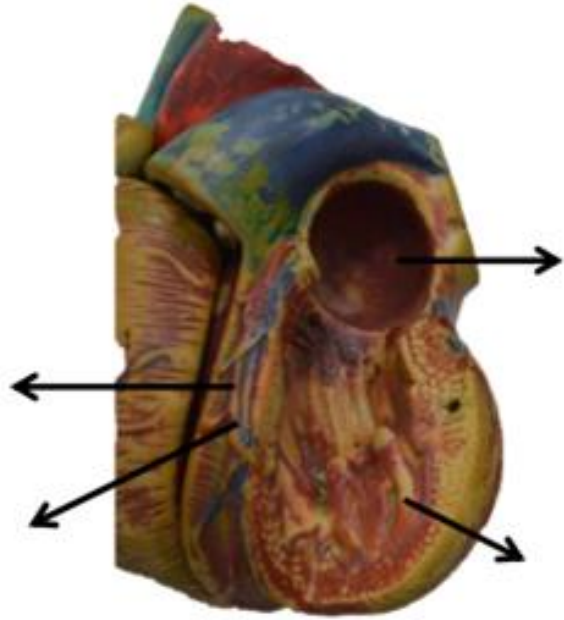
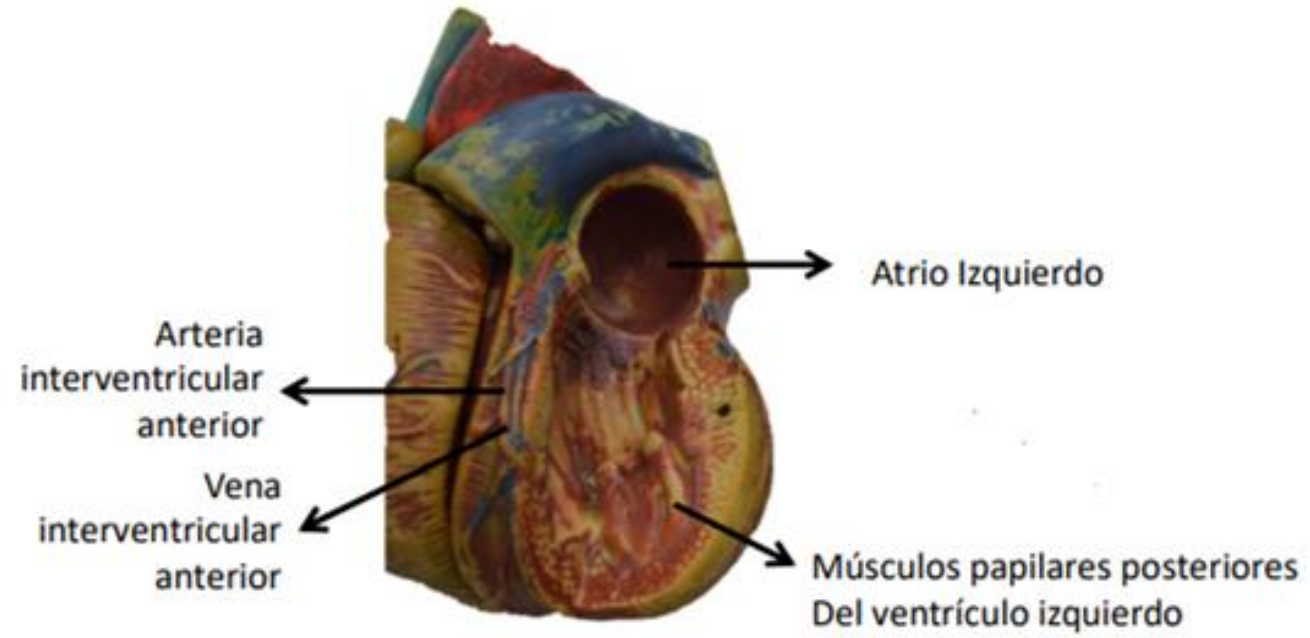


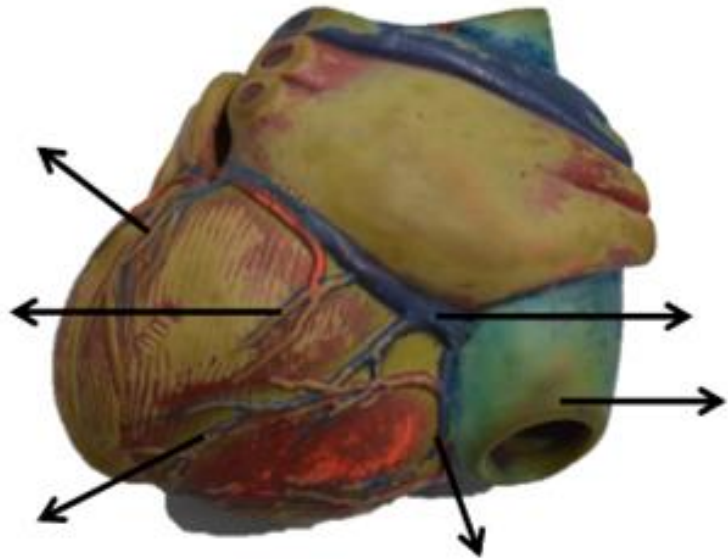
Figura: 4-53. Forma, orientación, caras y bordes del corazón.











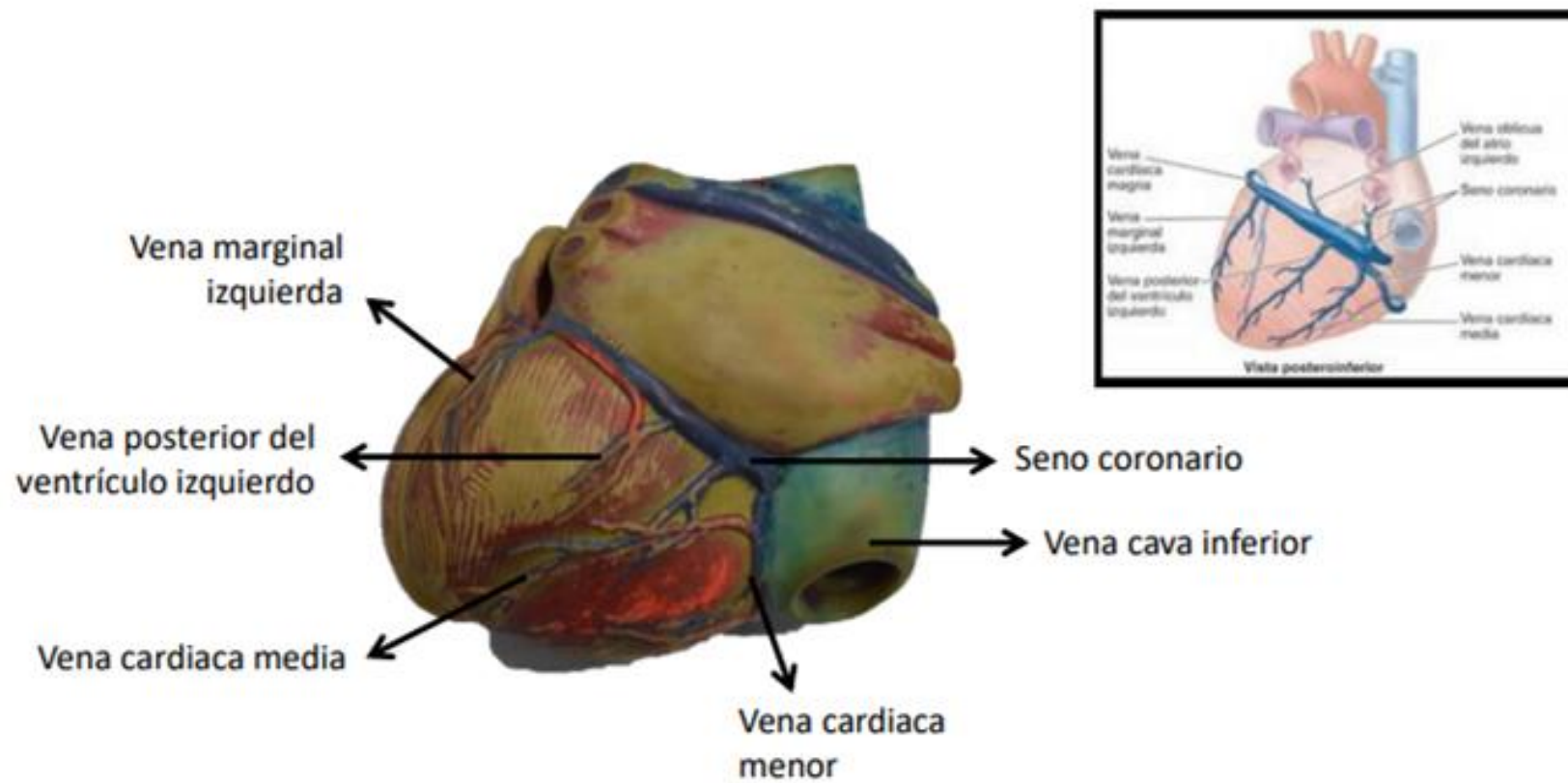
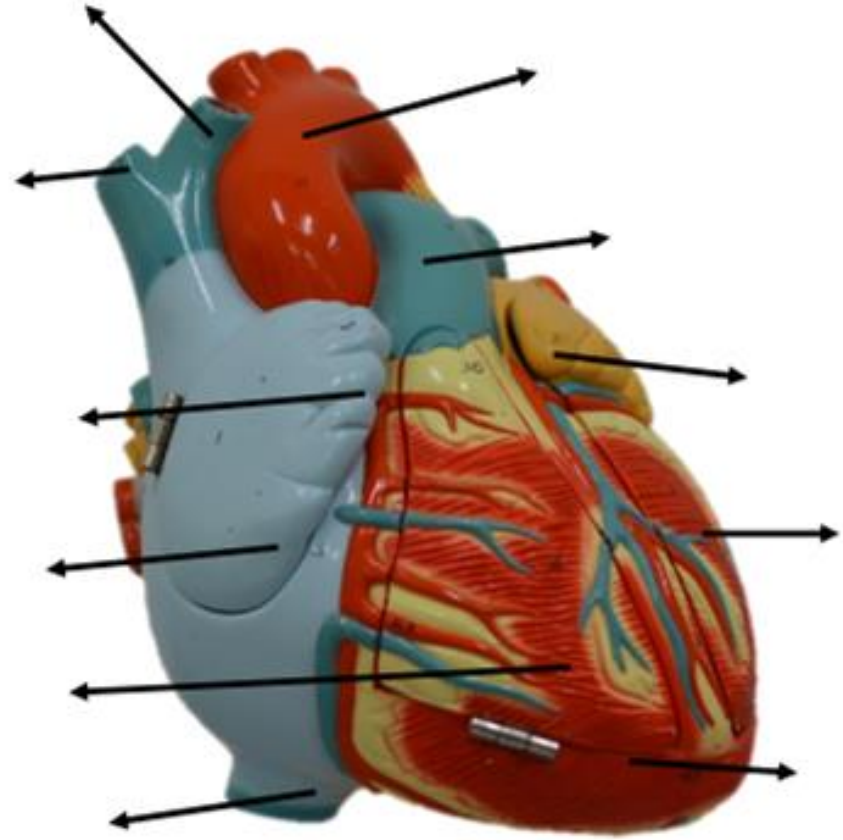


Figura: 4-62. Venas del corazón.



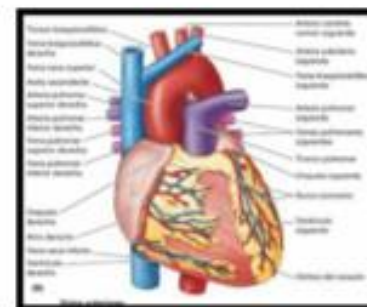
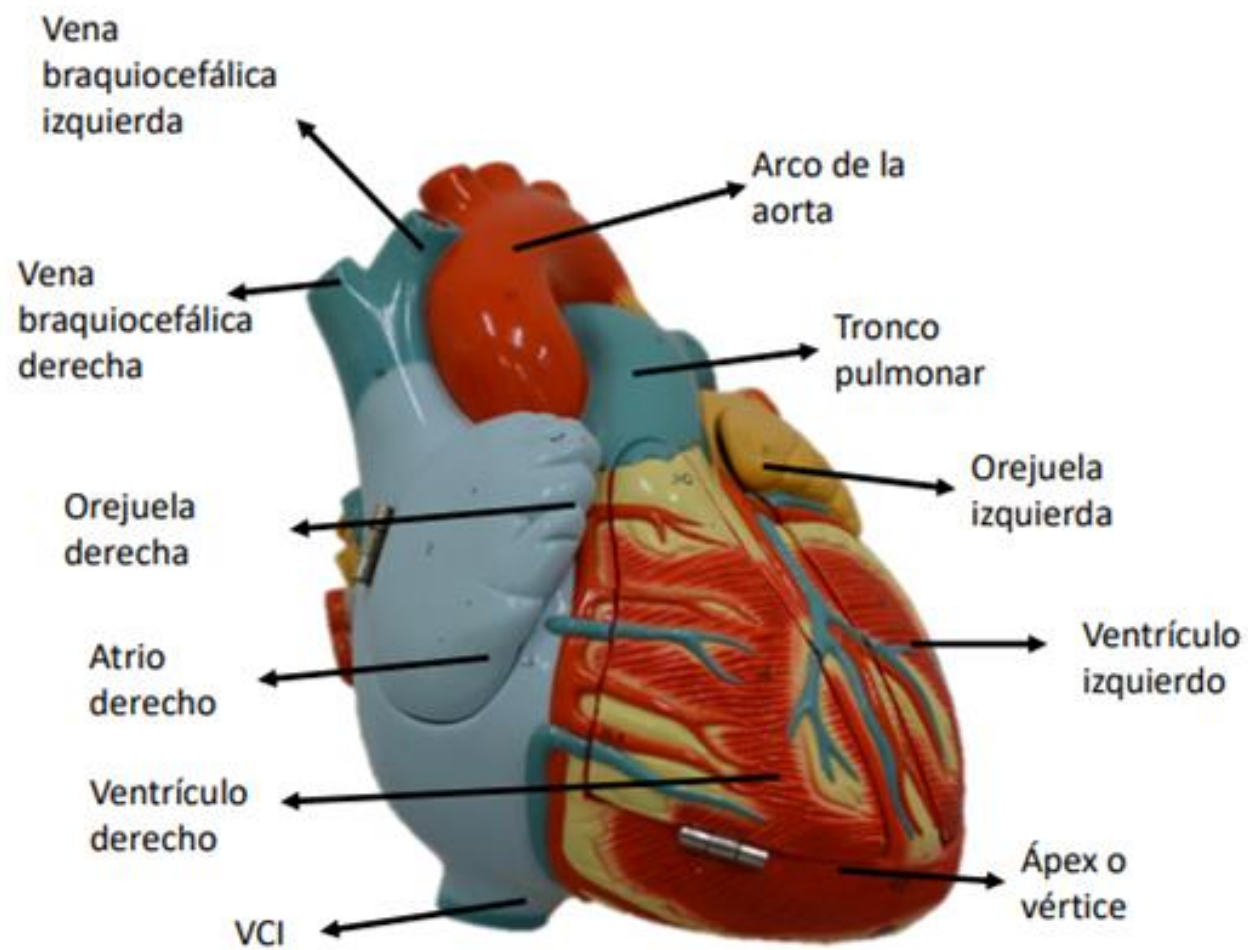
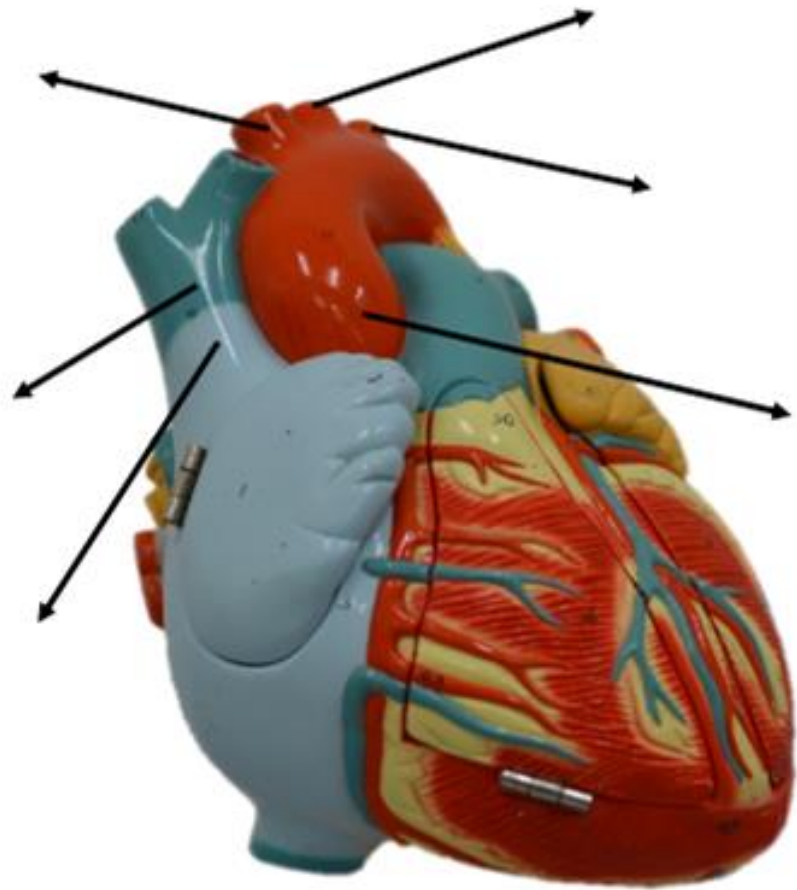


Figura: 4-53. Forma, orientación, caras y bordes del corazón.



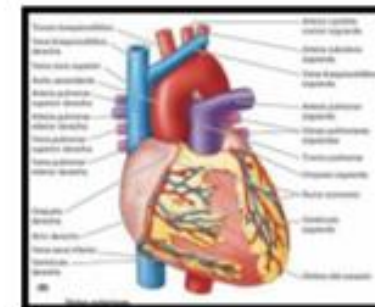
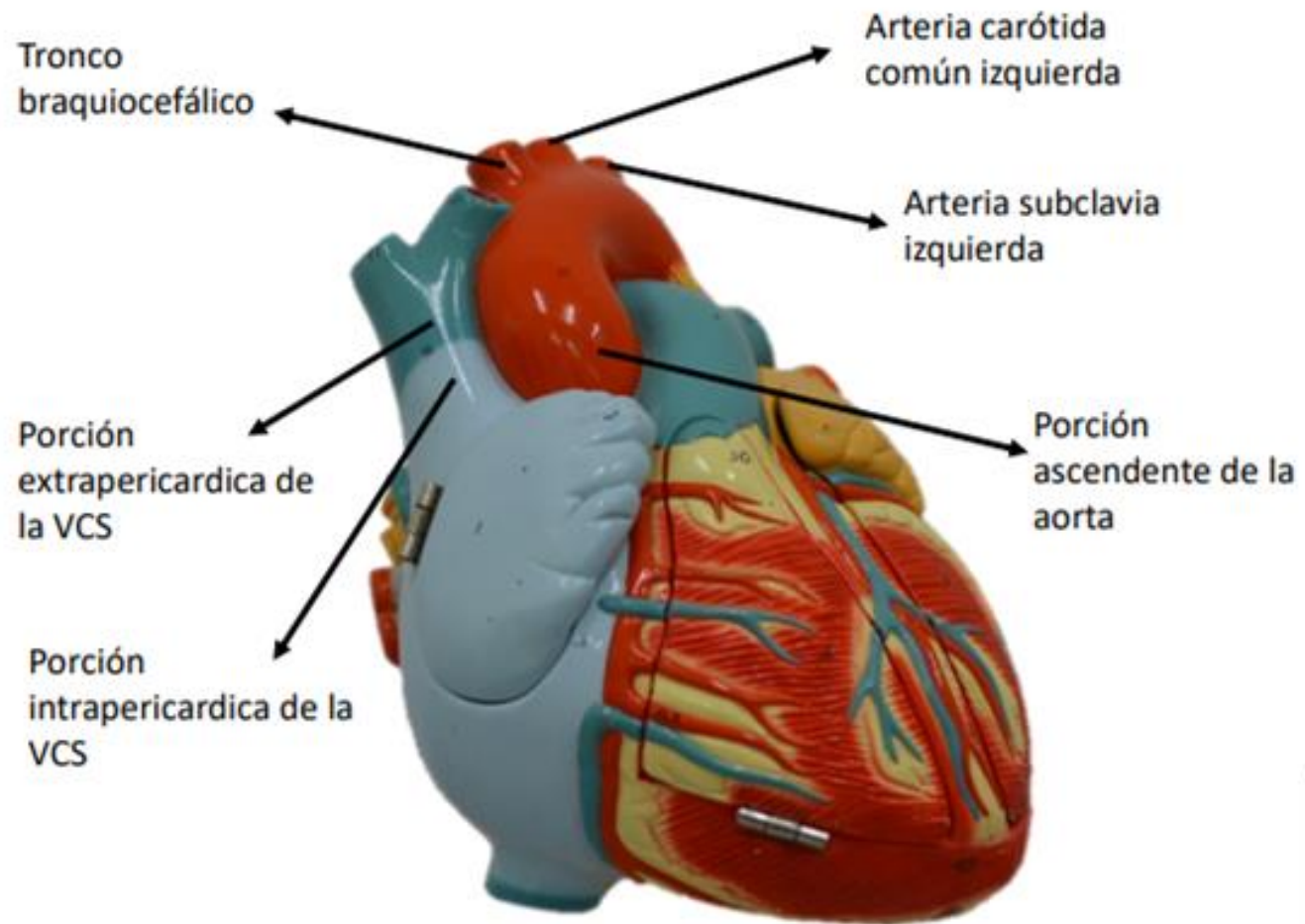
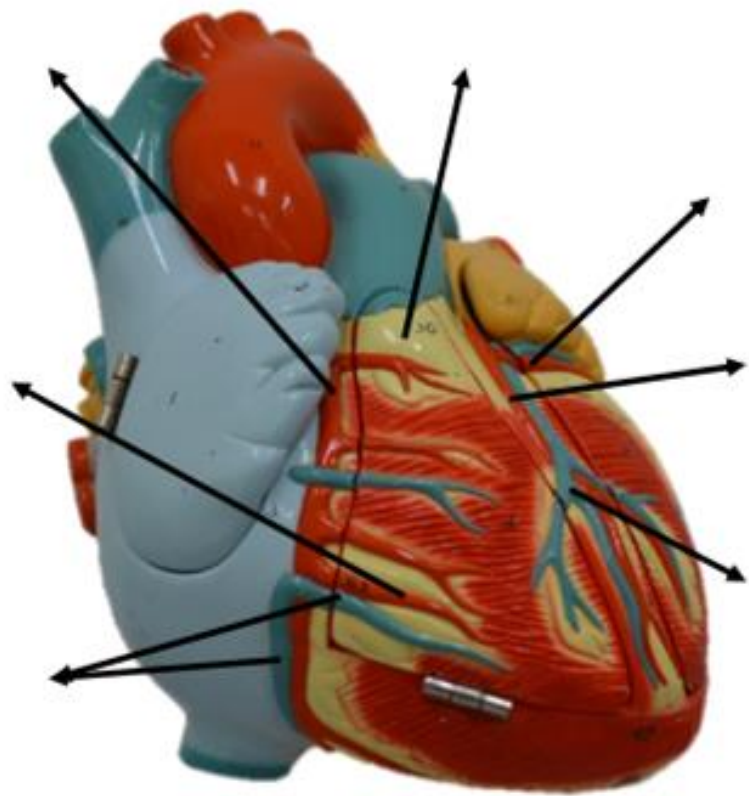
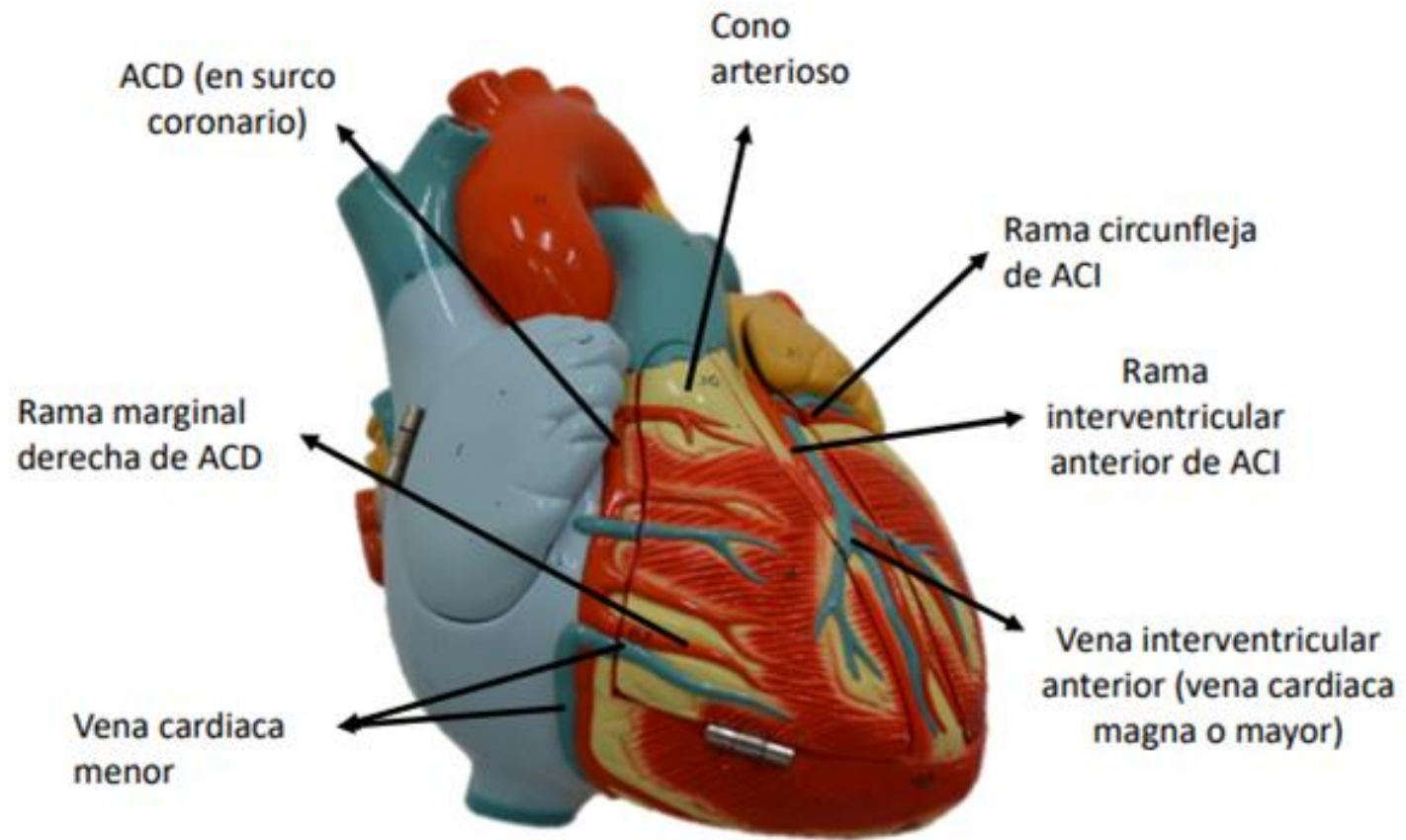
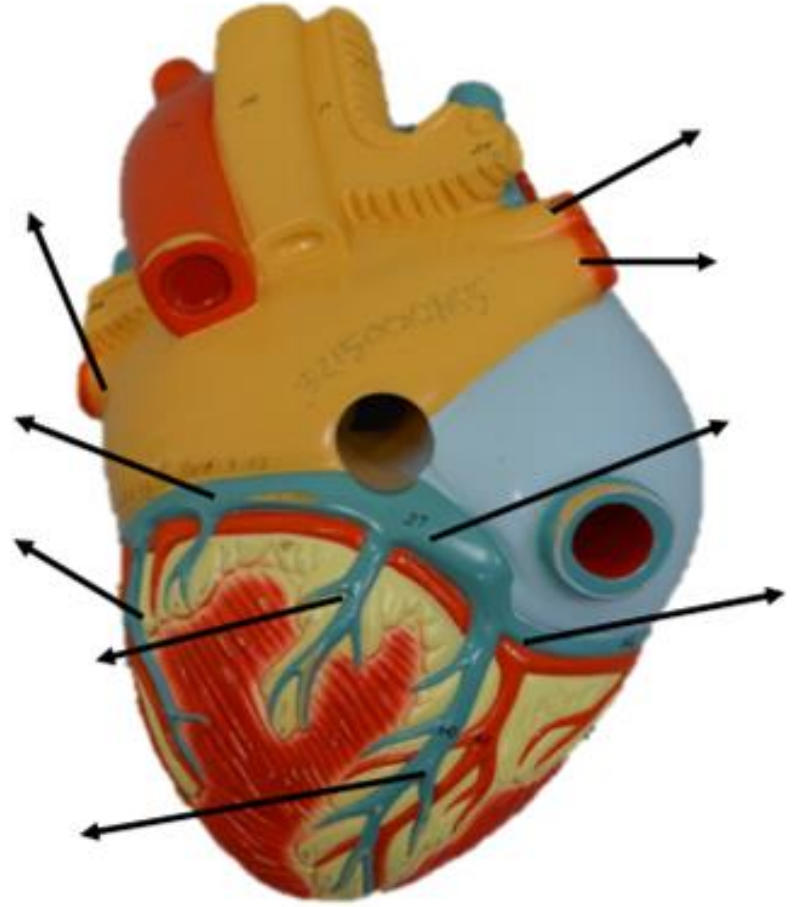
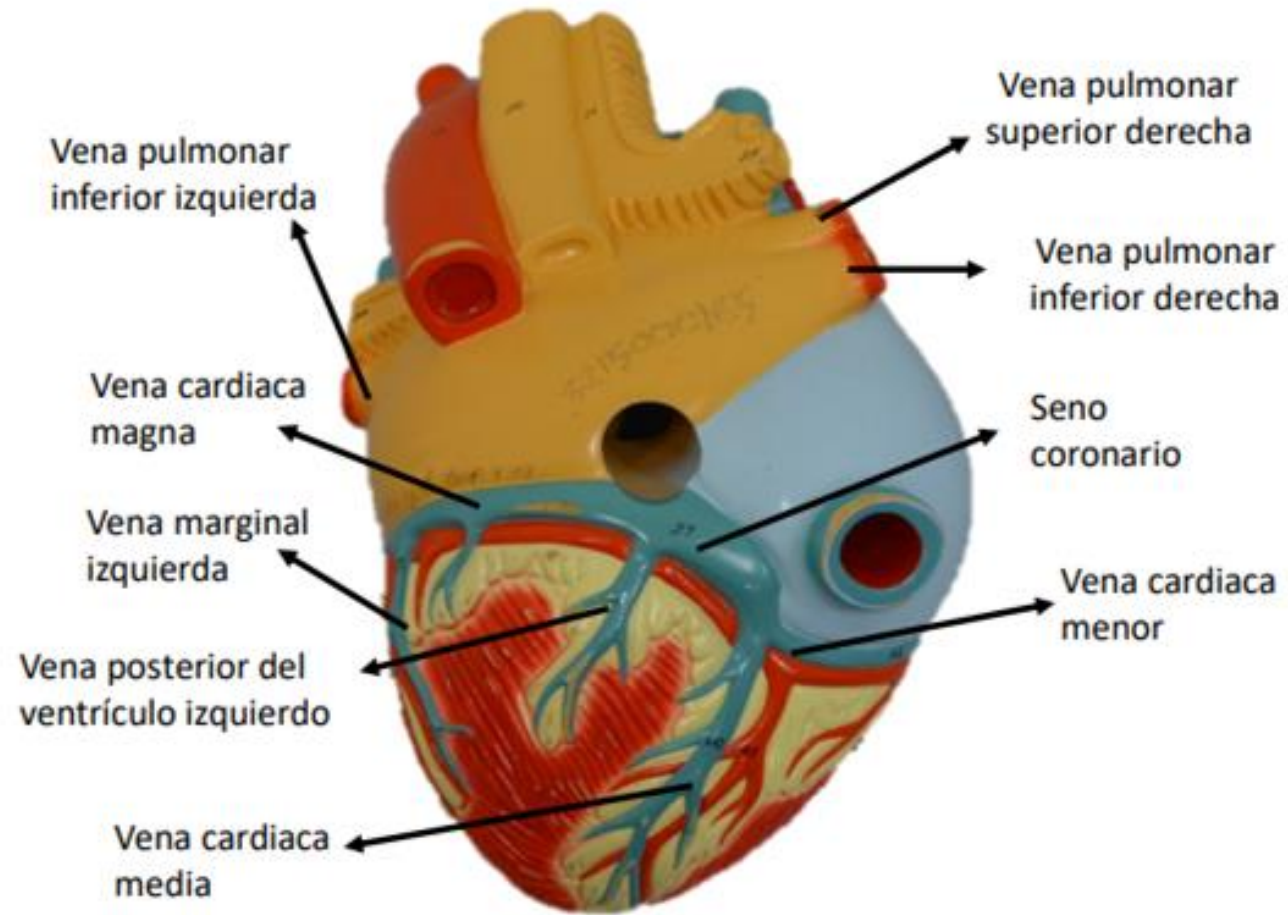


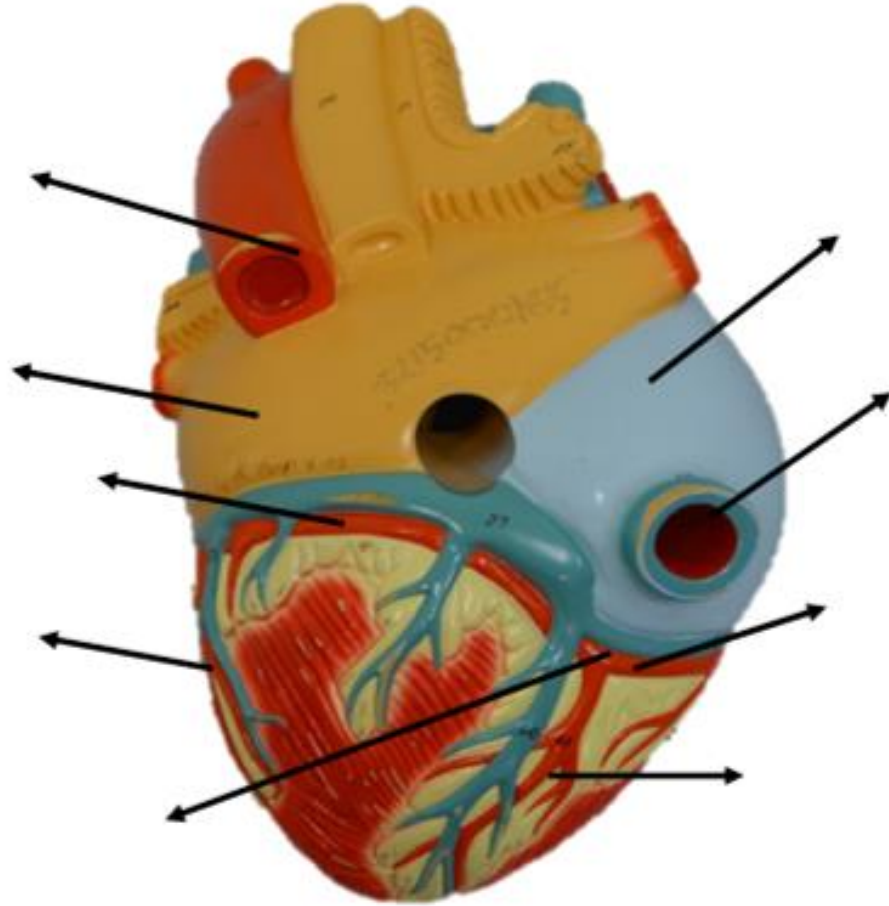
Figura: 4-53. Forma, orientación, caras y bordes del corazón.

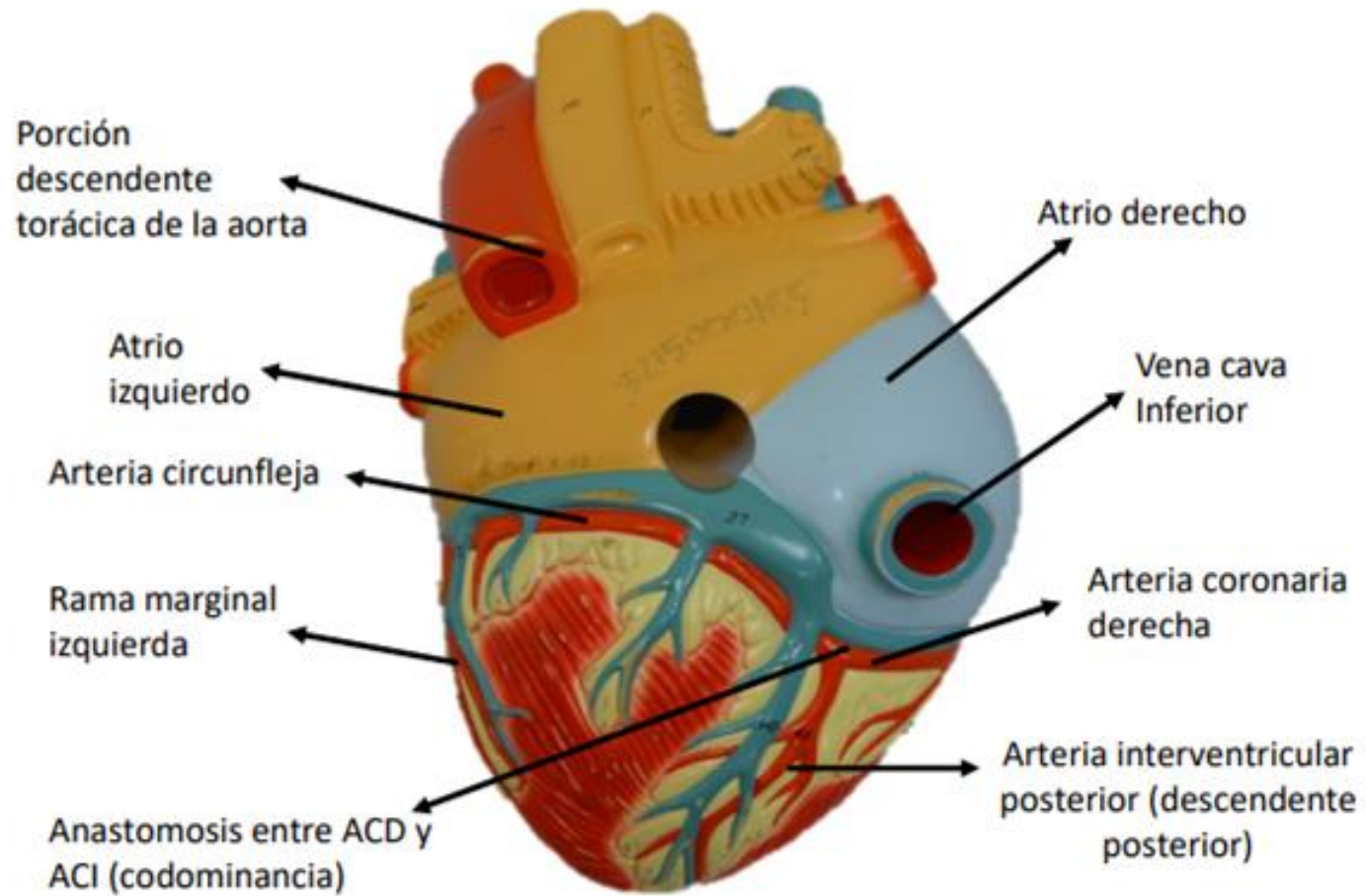


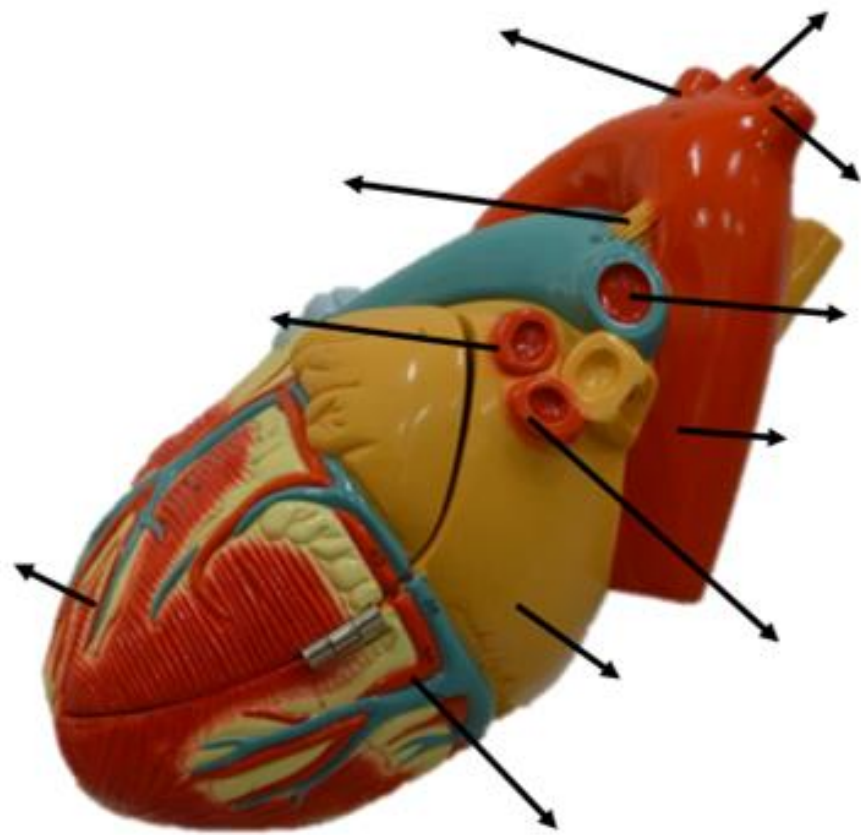


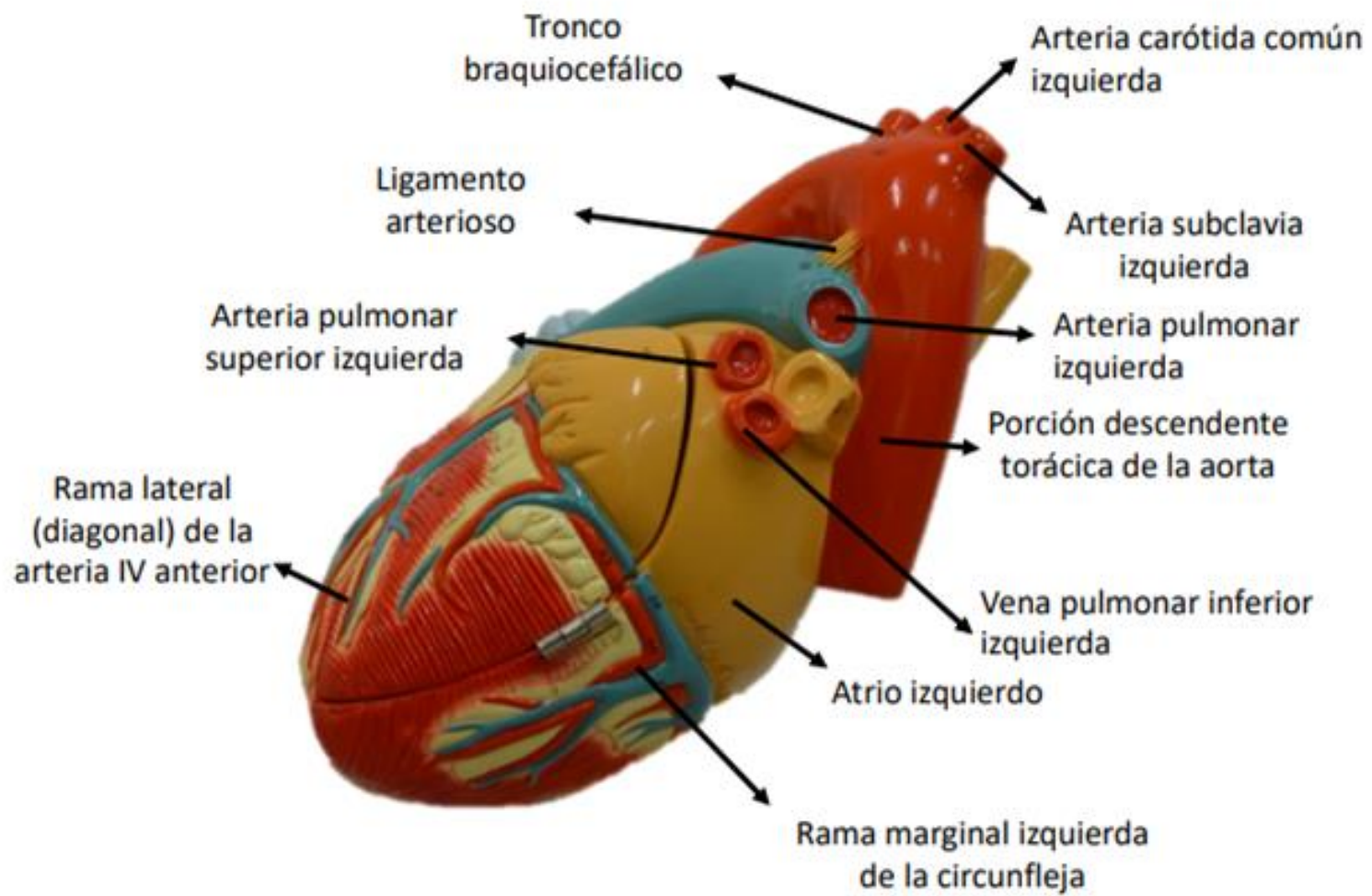


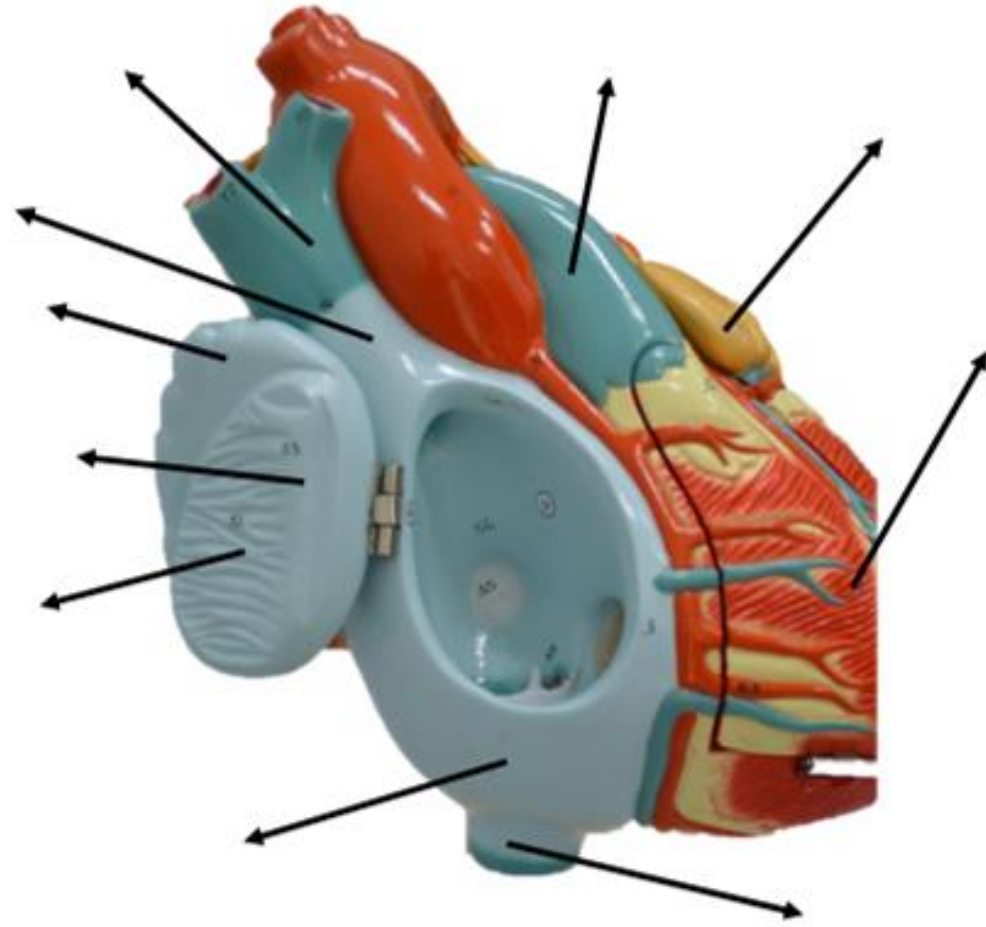


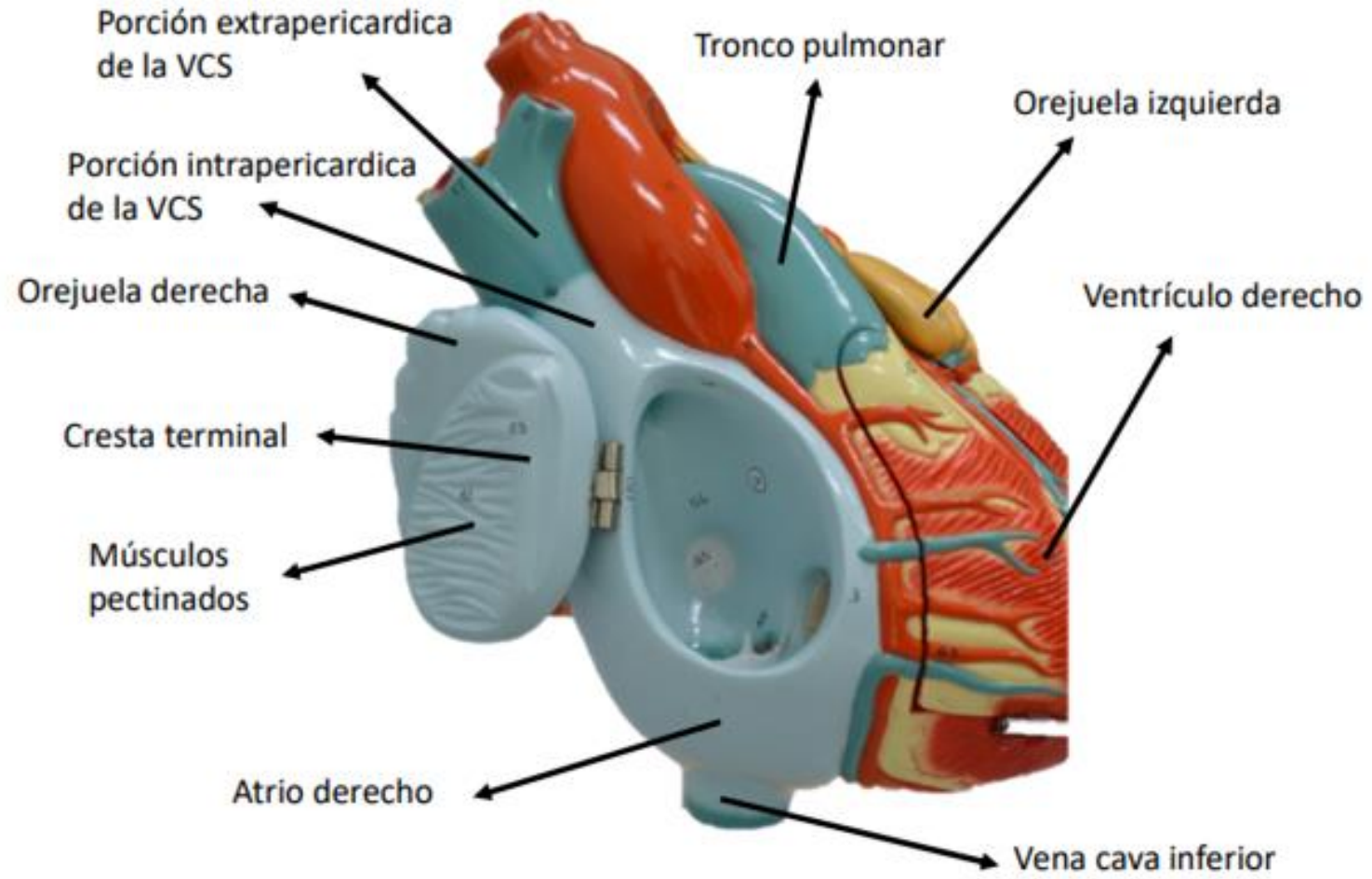


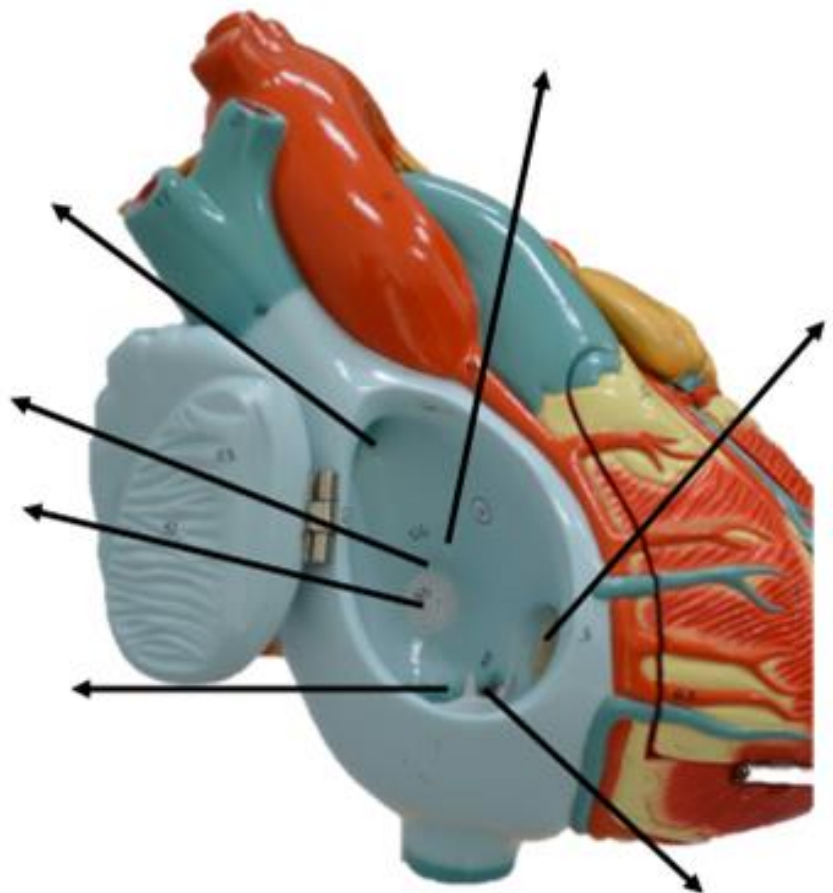


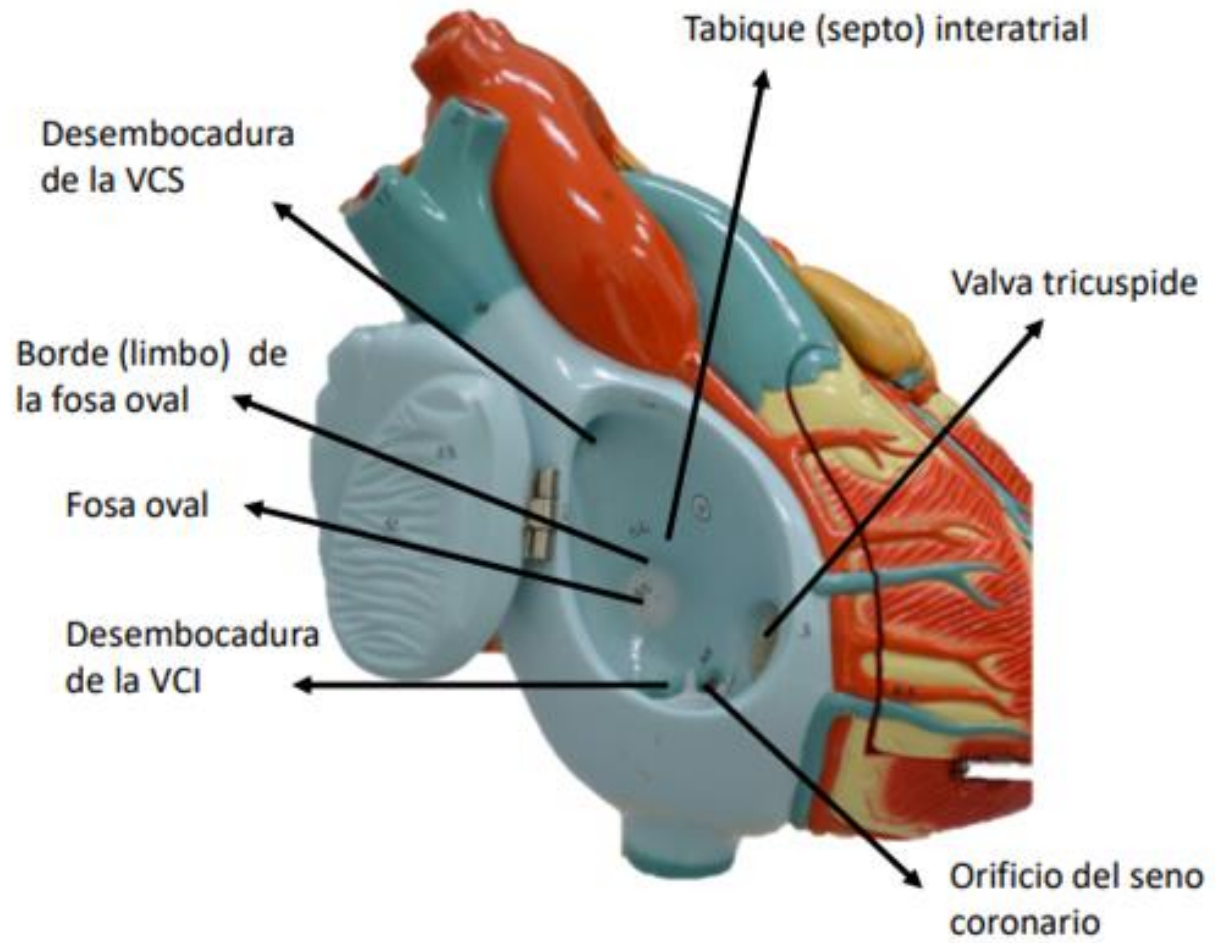


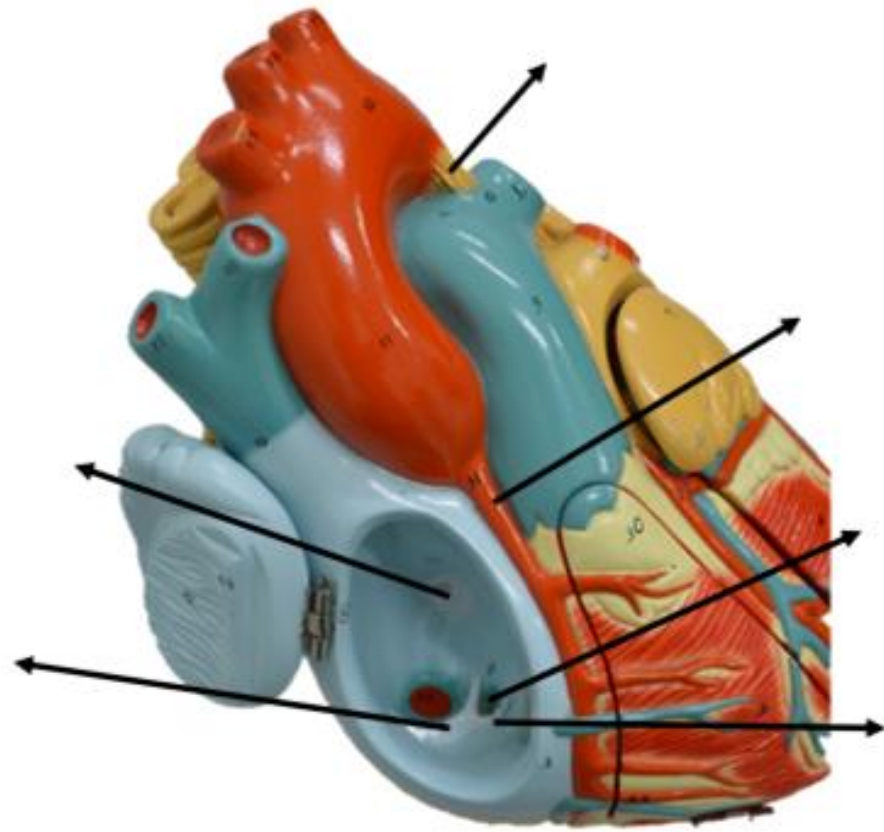












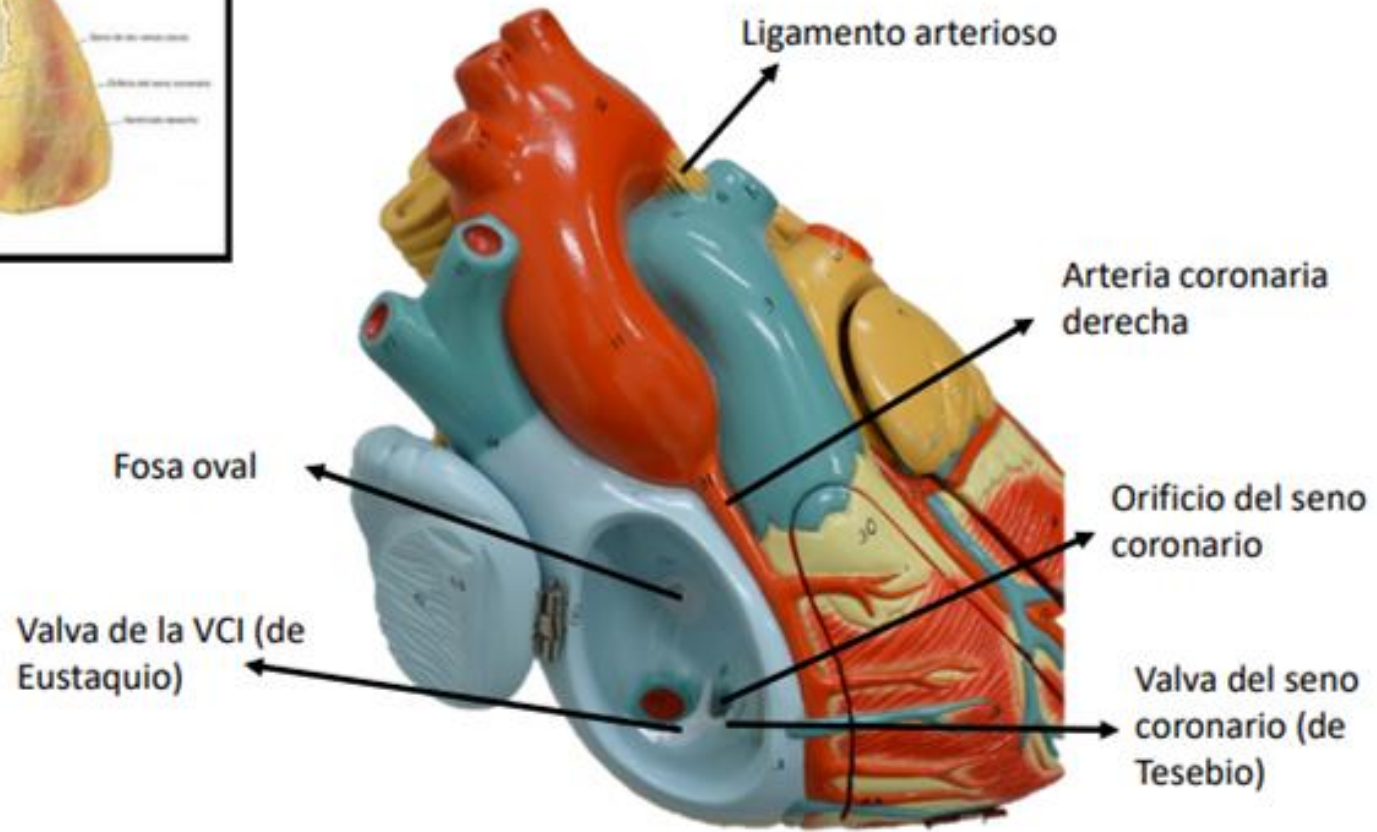
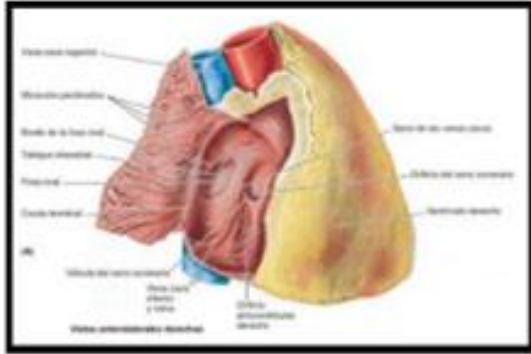
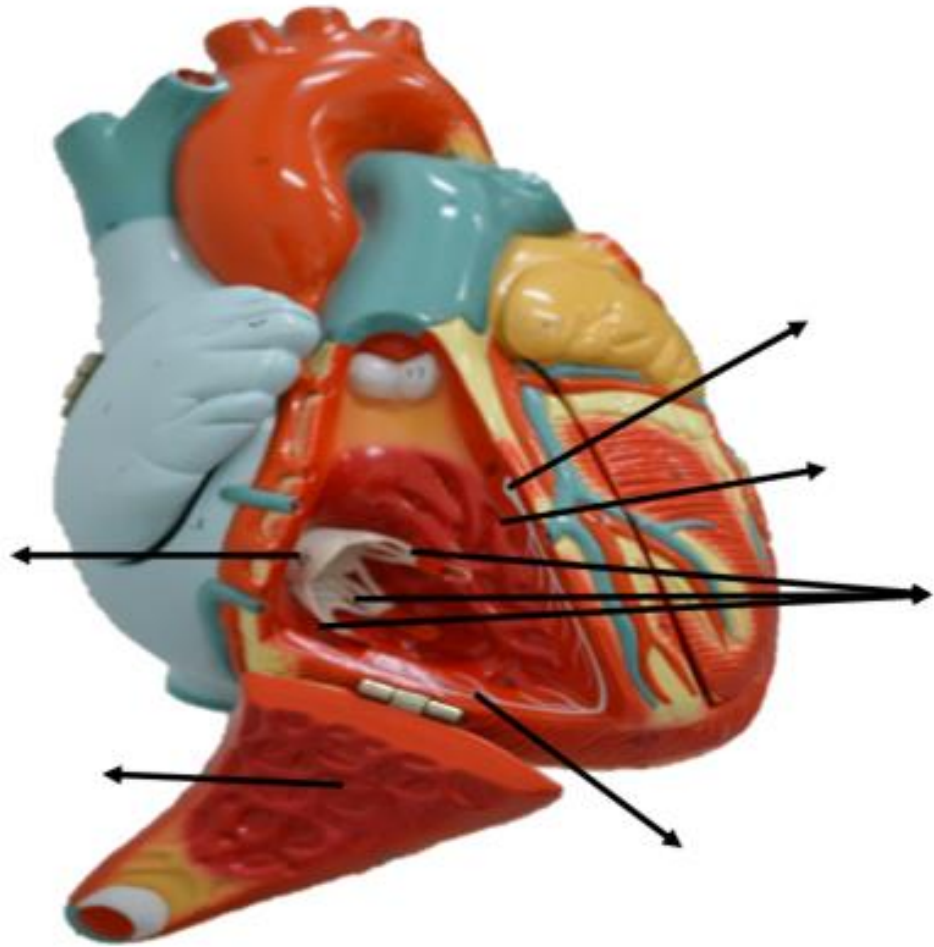
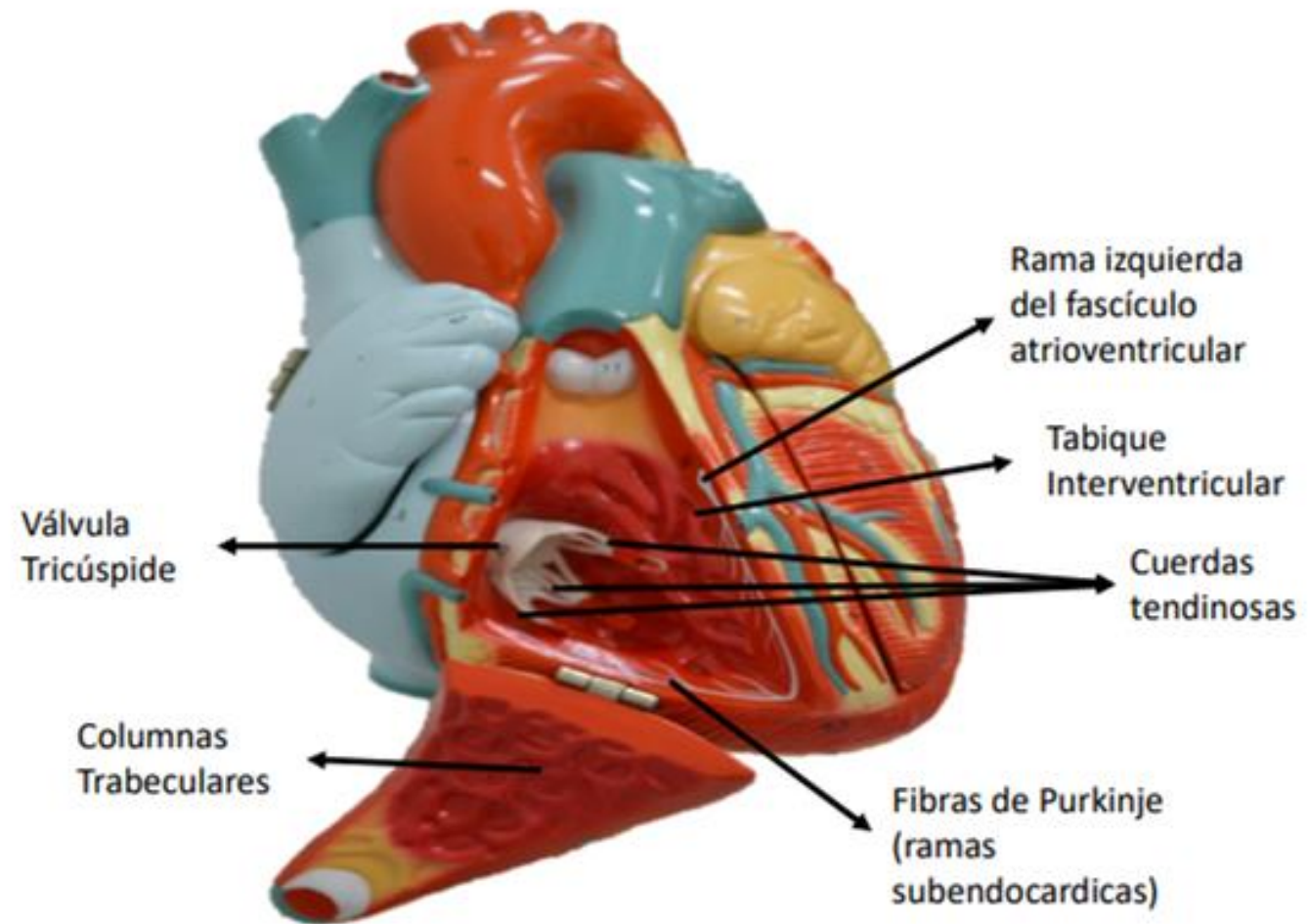
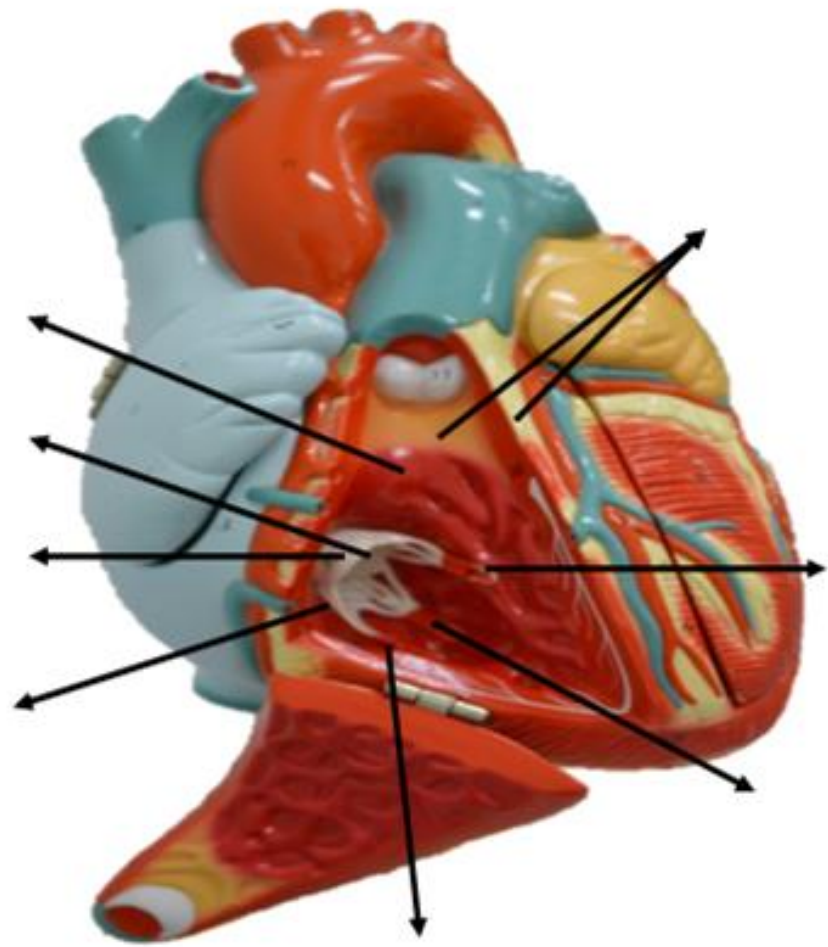
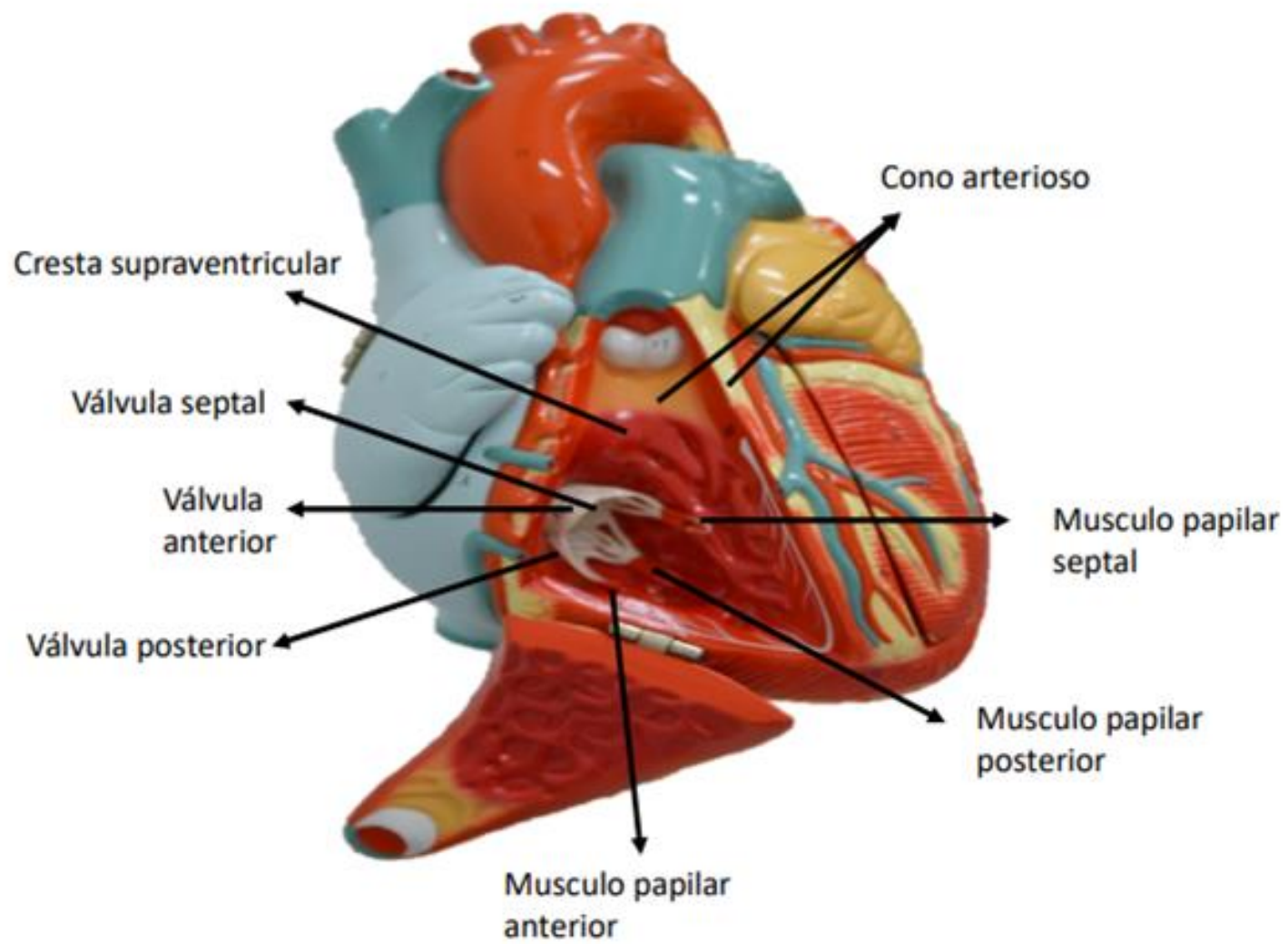


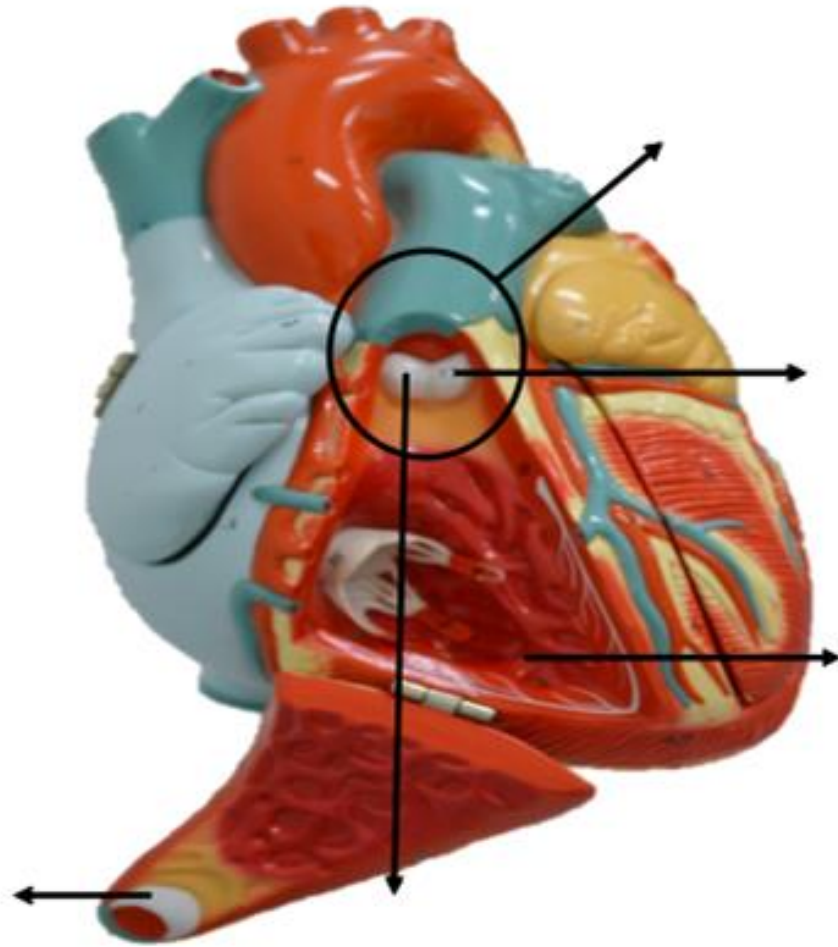
Figura: 4-54. Atrio derecho del corazón.

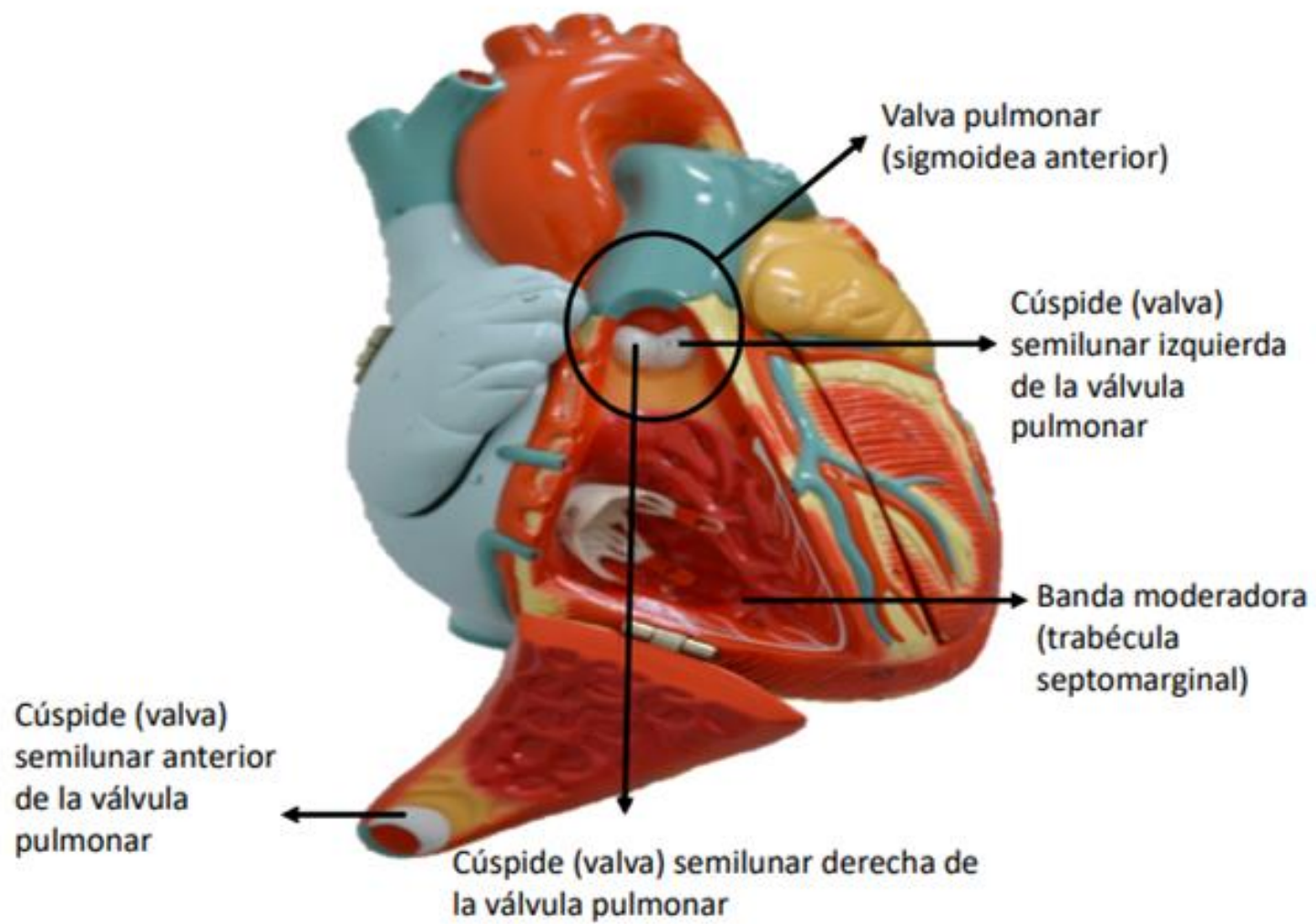


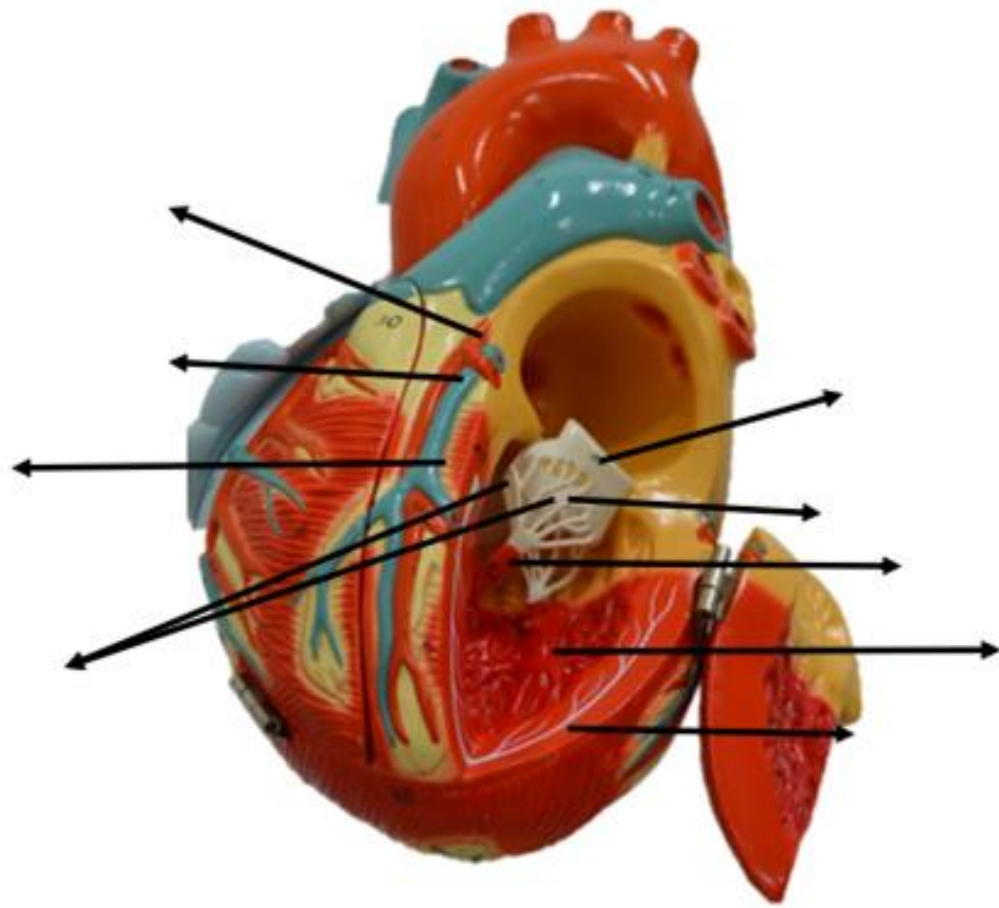












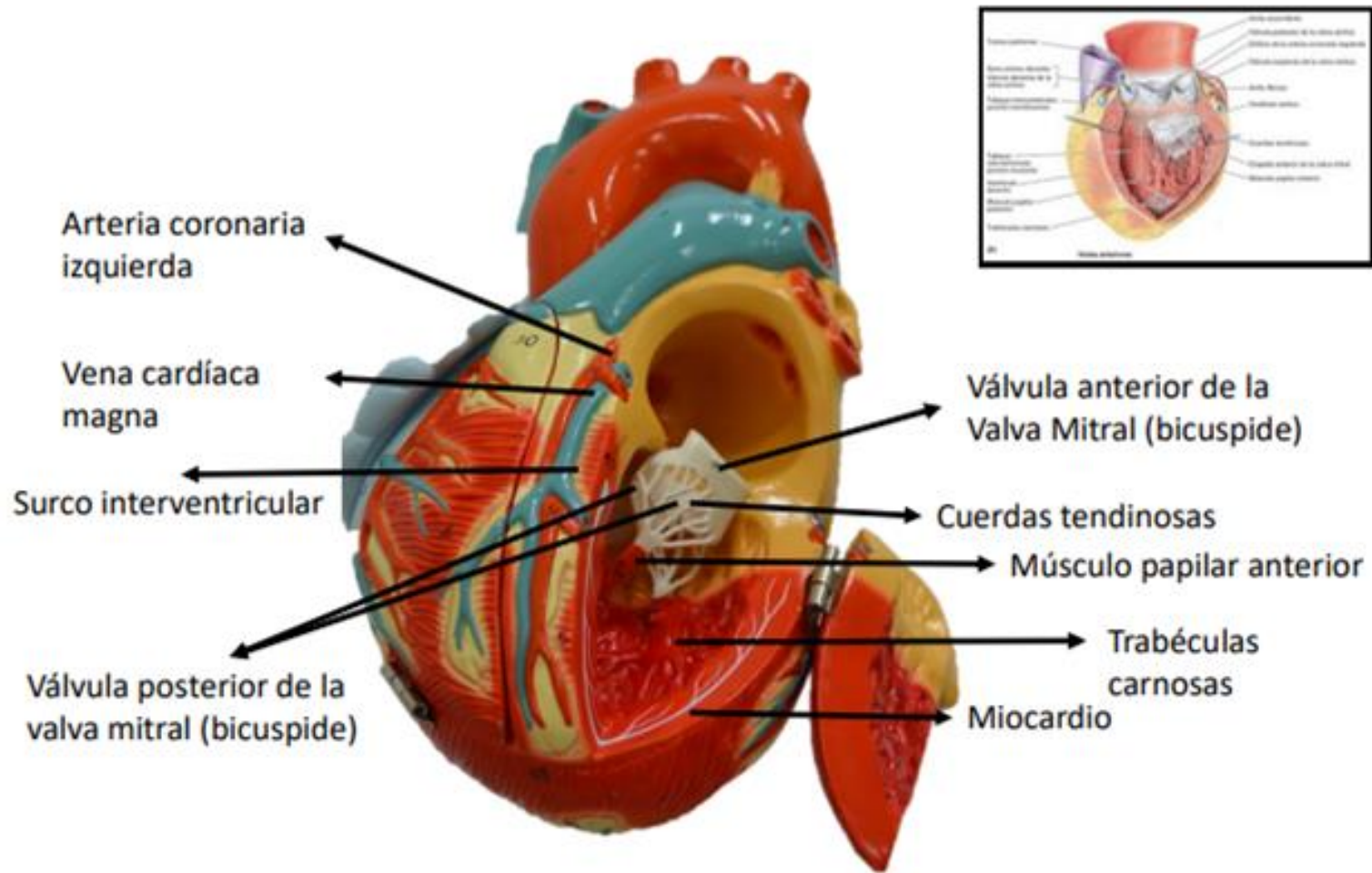
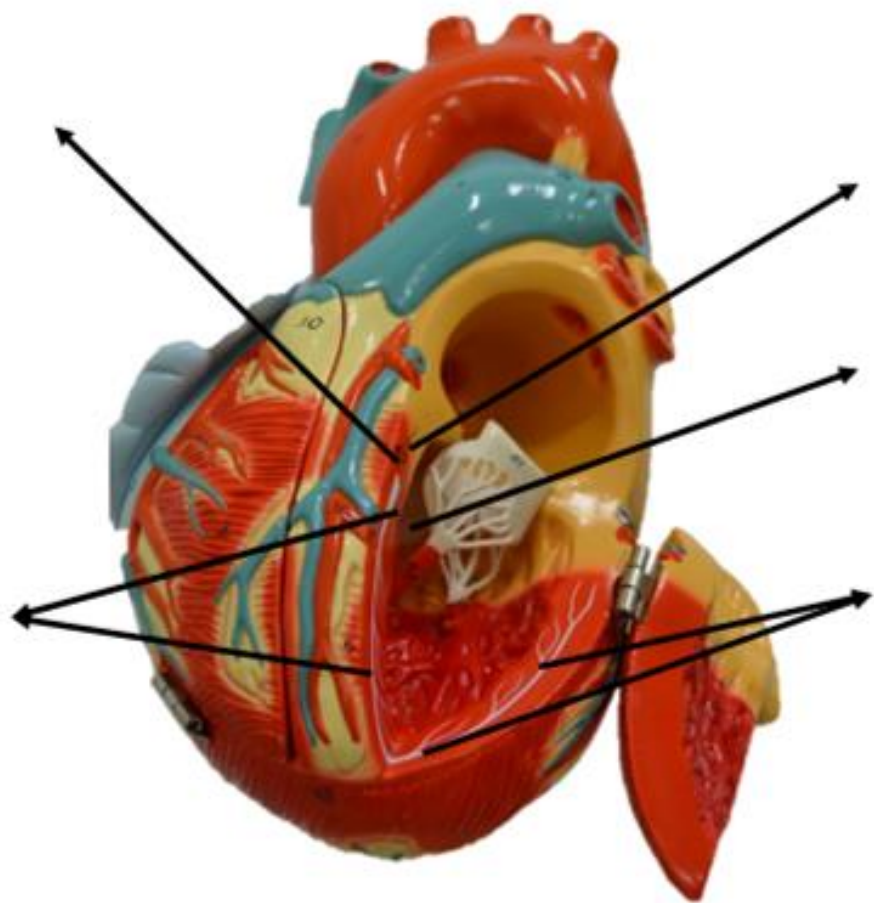
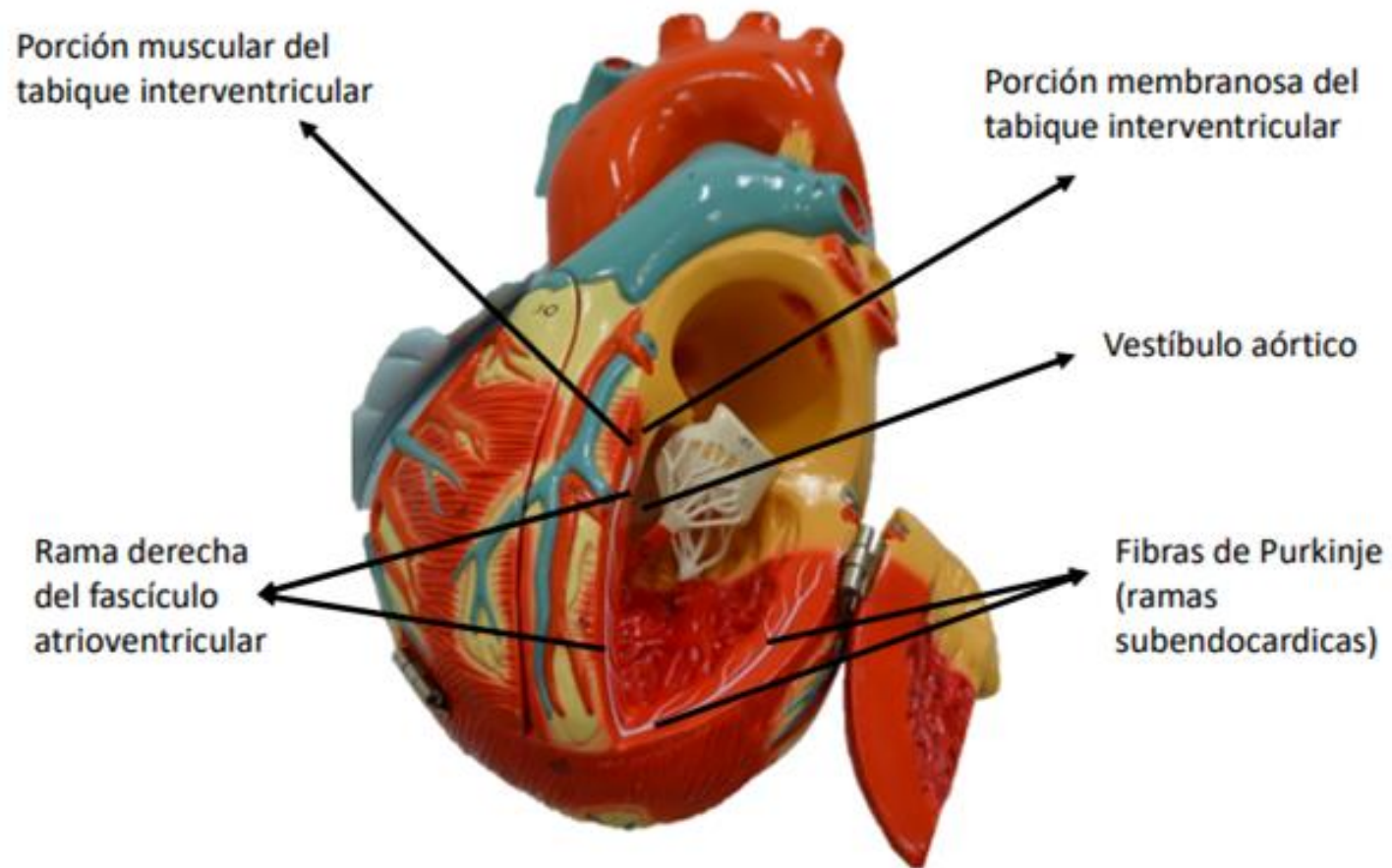
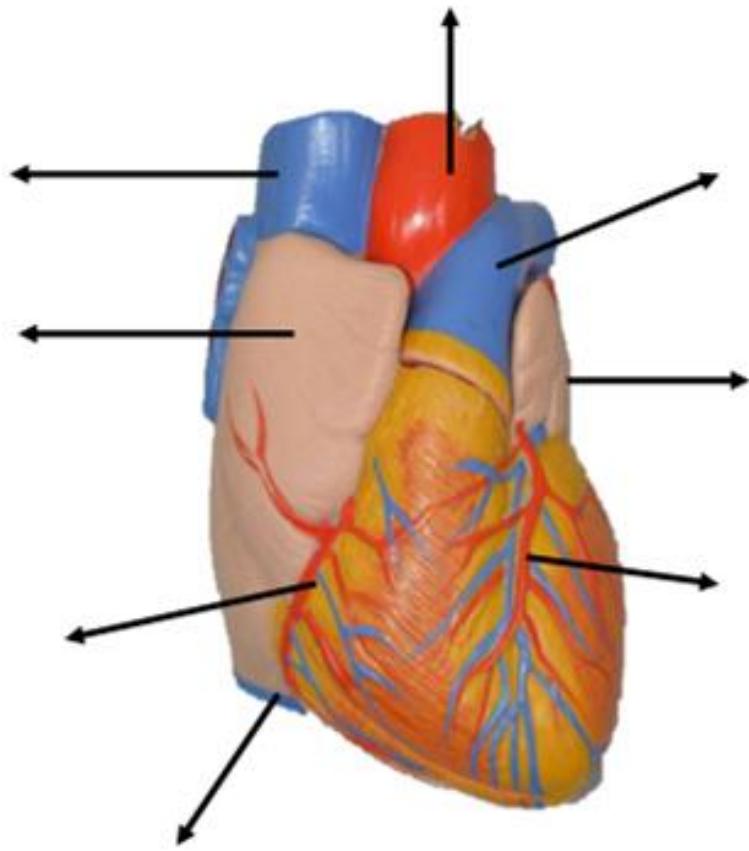


Figura: 4-58. Vista interior y del tracto de salida del ventrículo izquierdo del corazón.







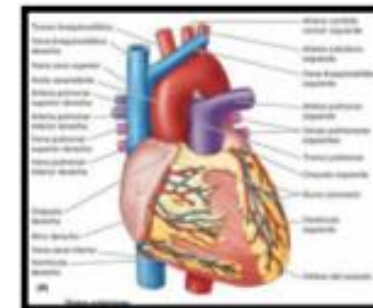
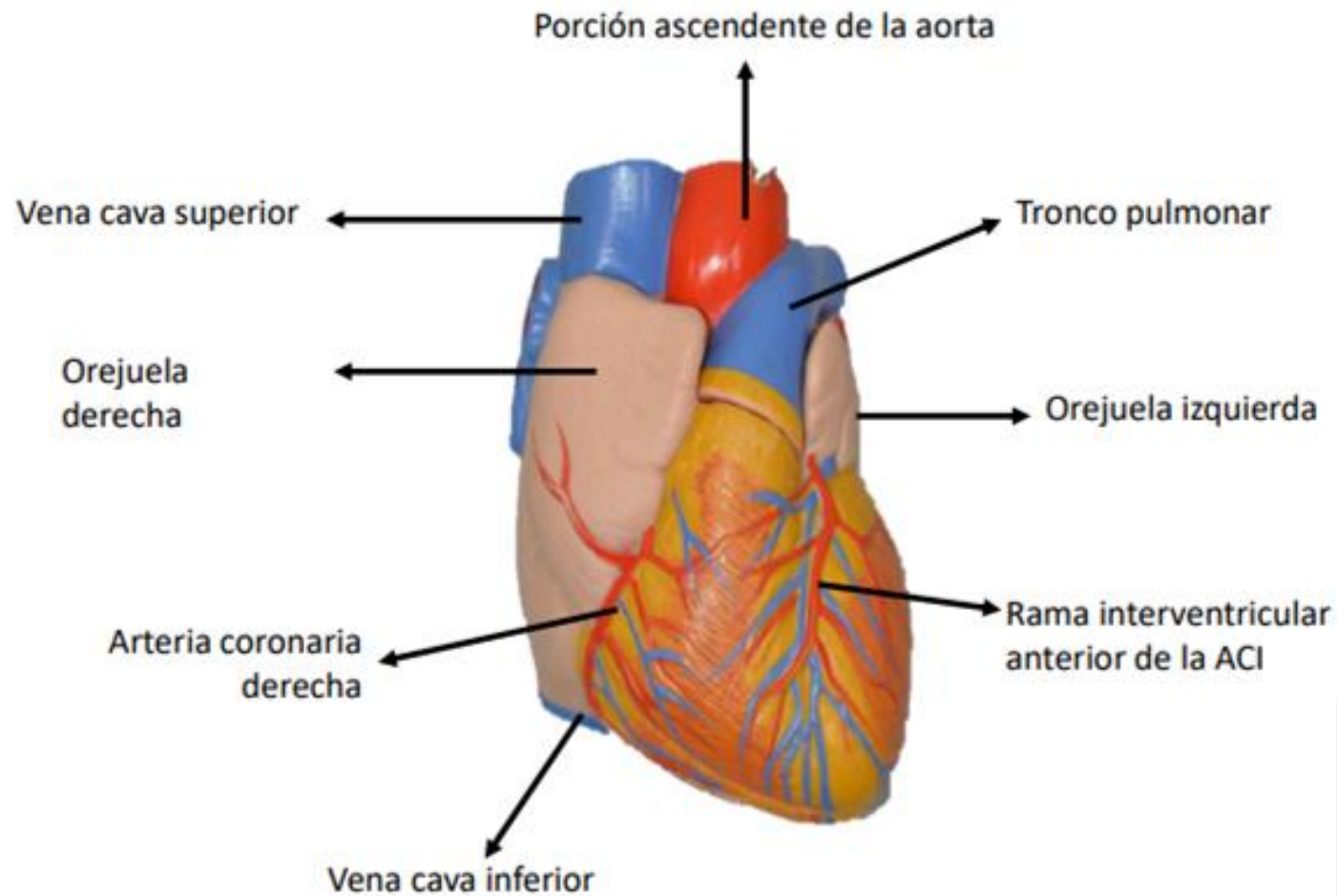
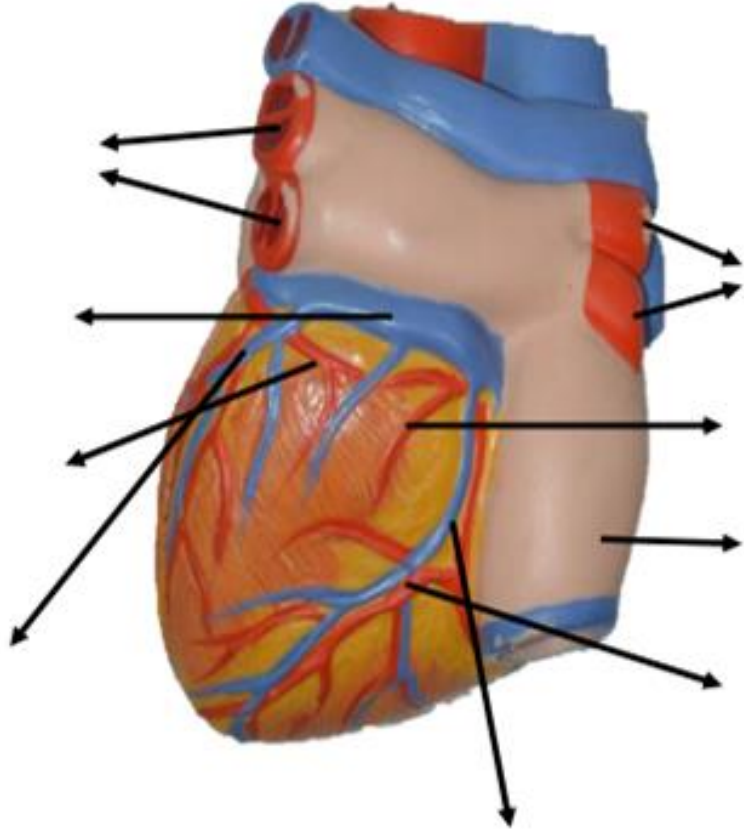
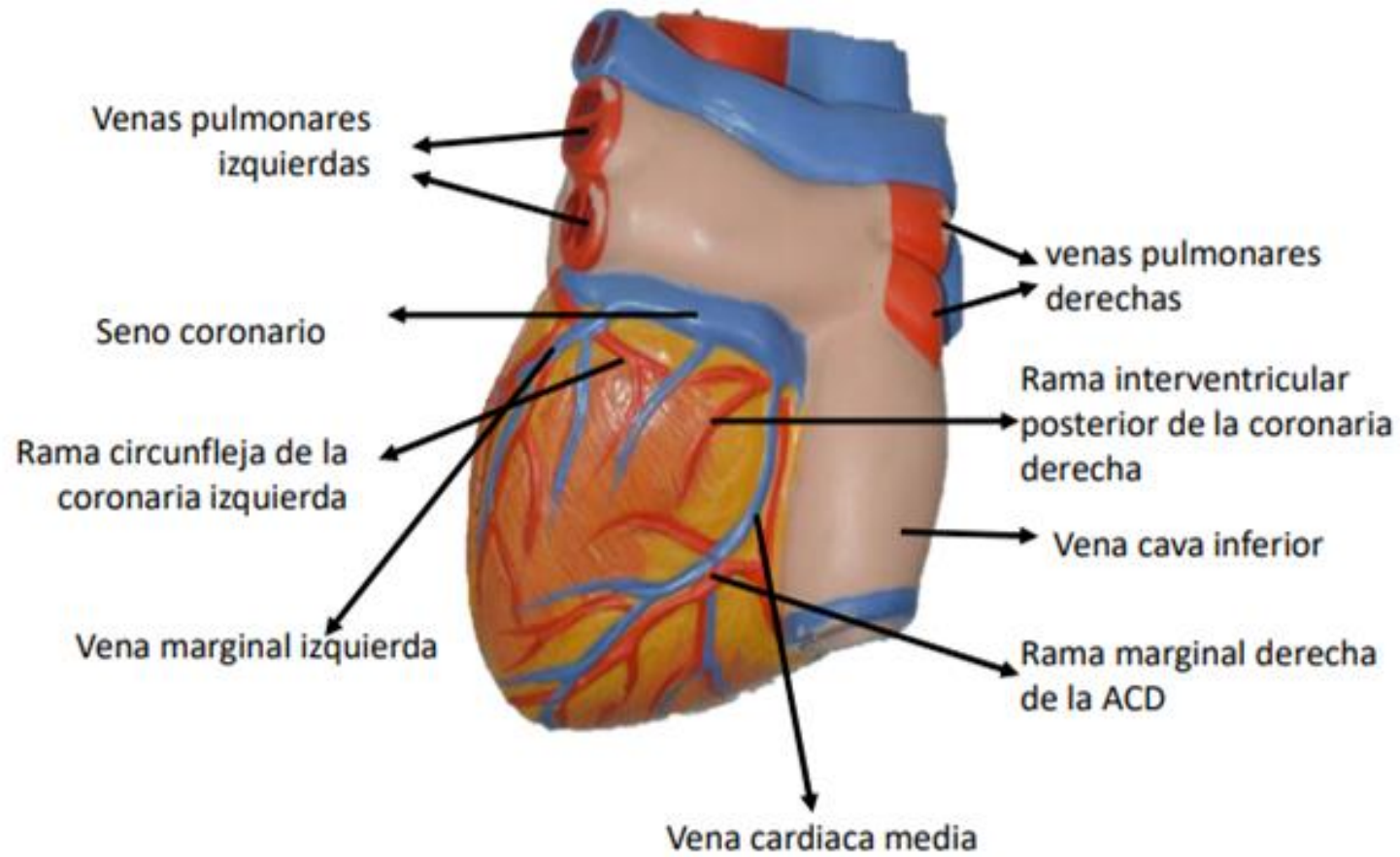
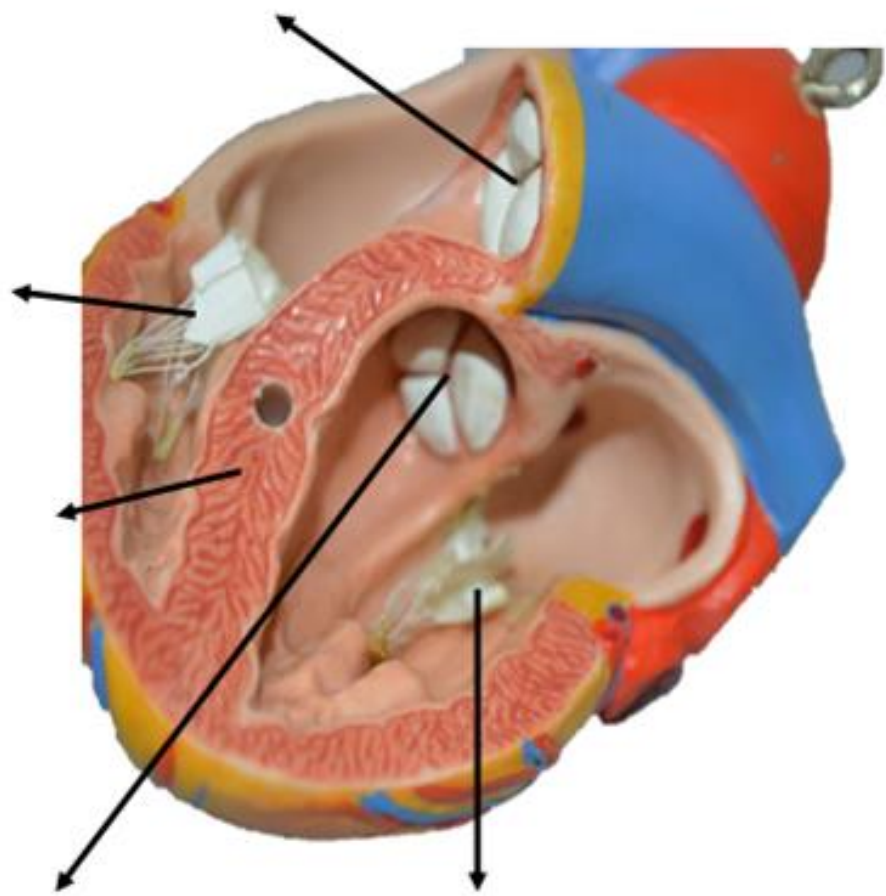
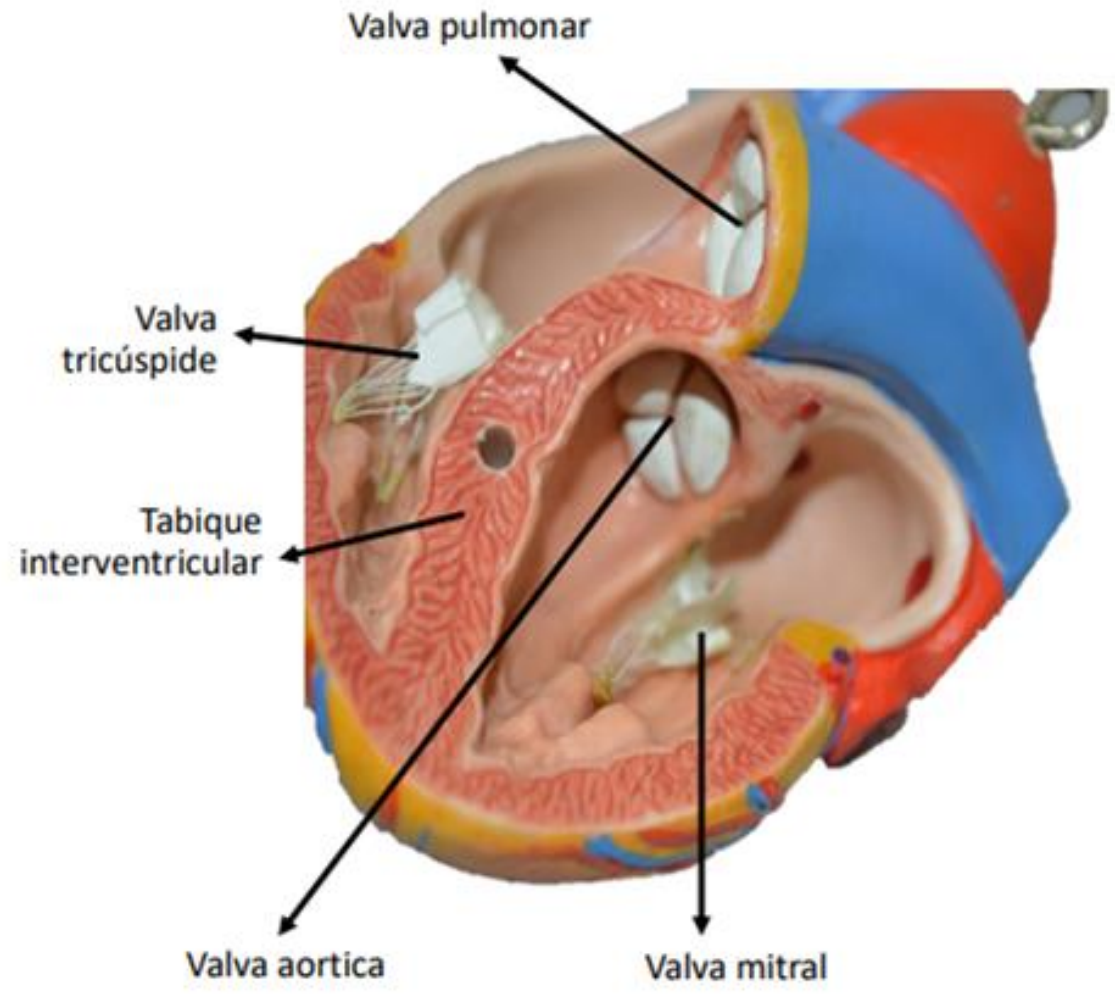


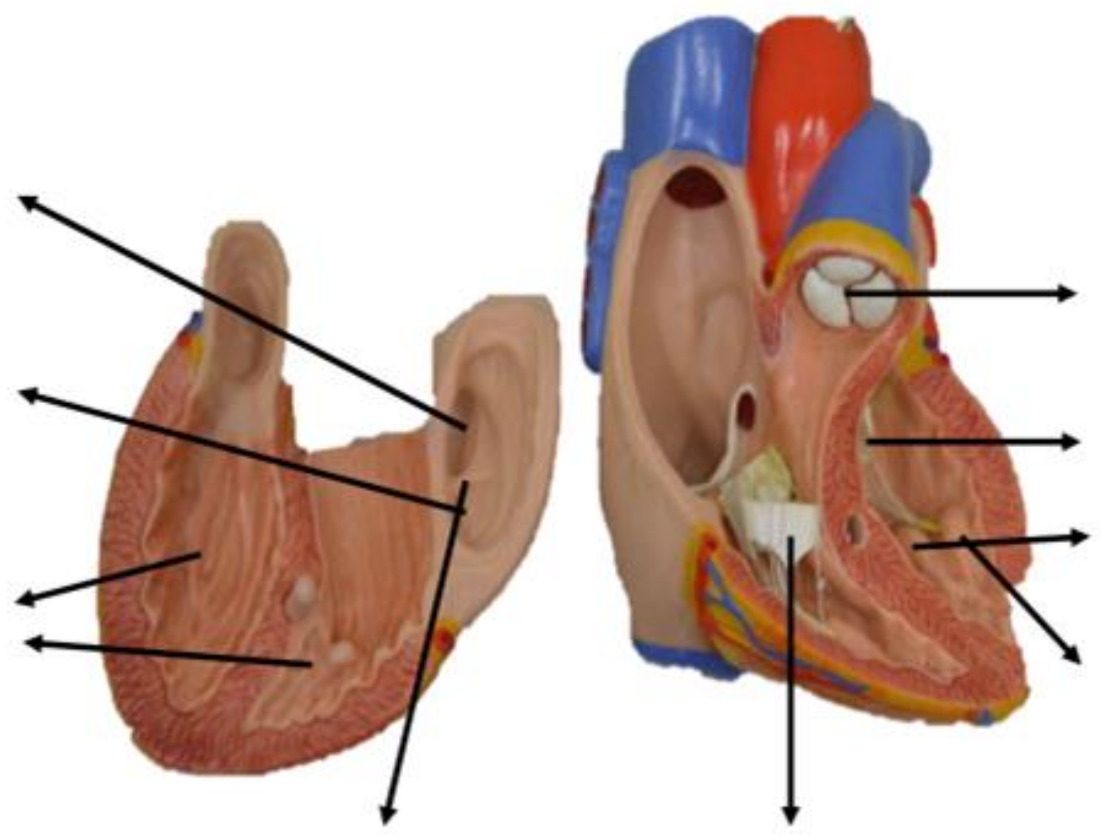
Figura: 4-53. Forma, orientación, caras y bordes del corazón.











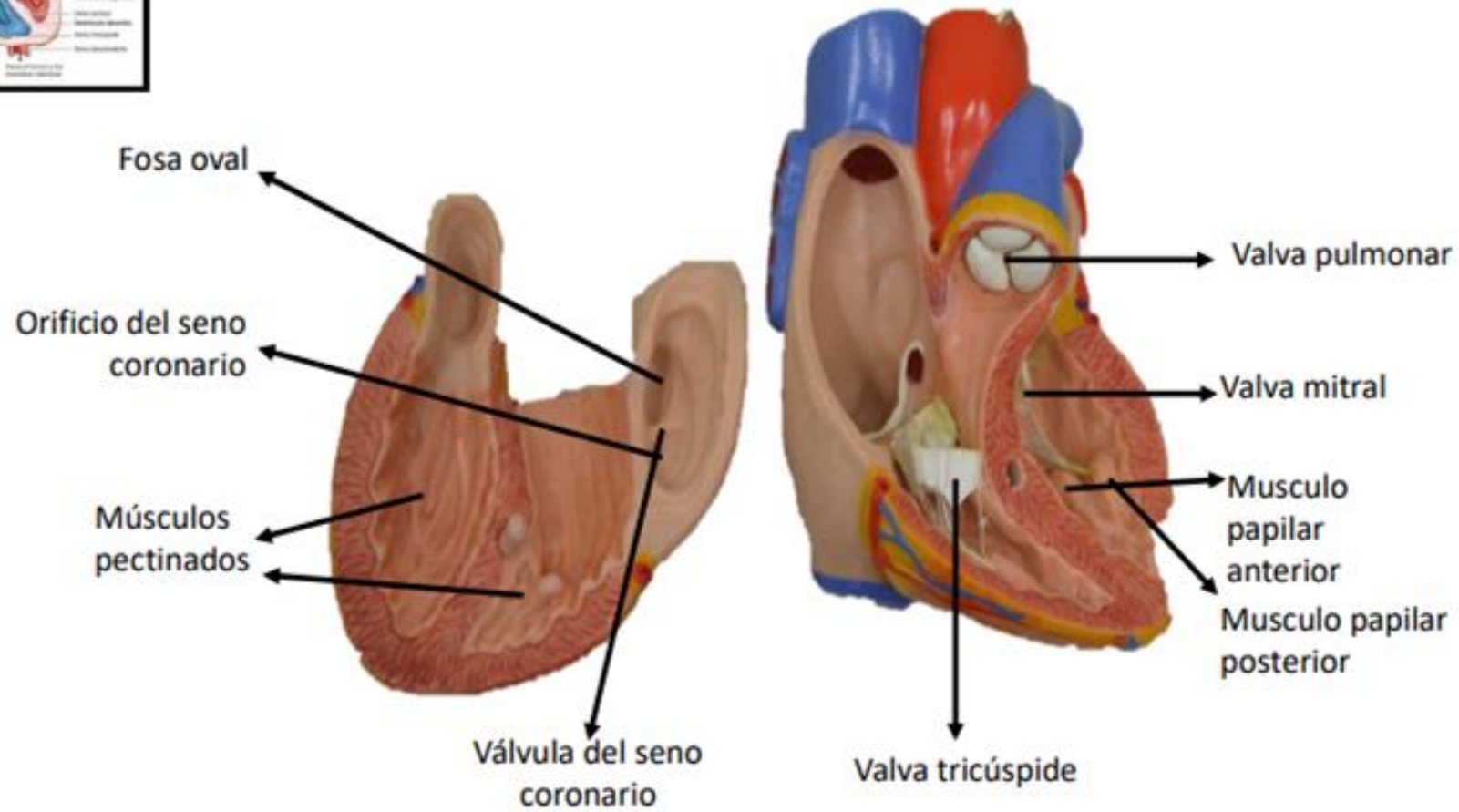
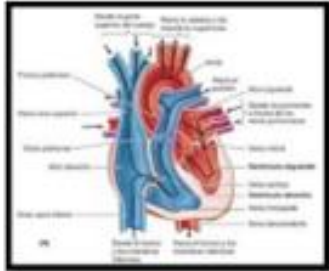
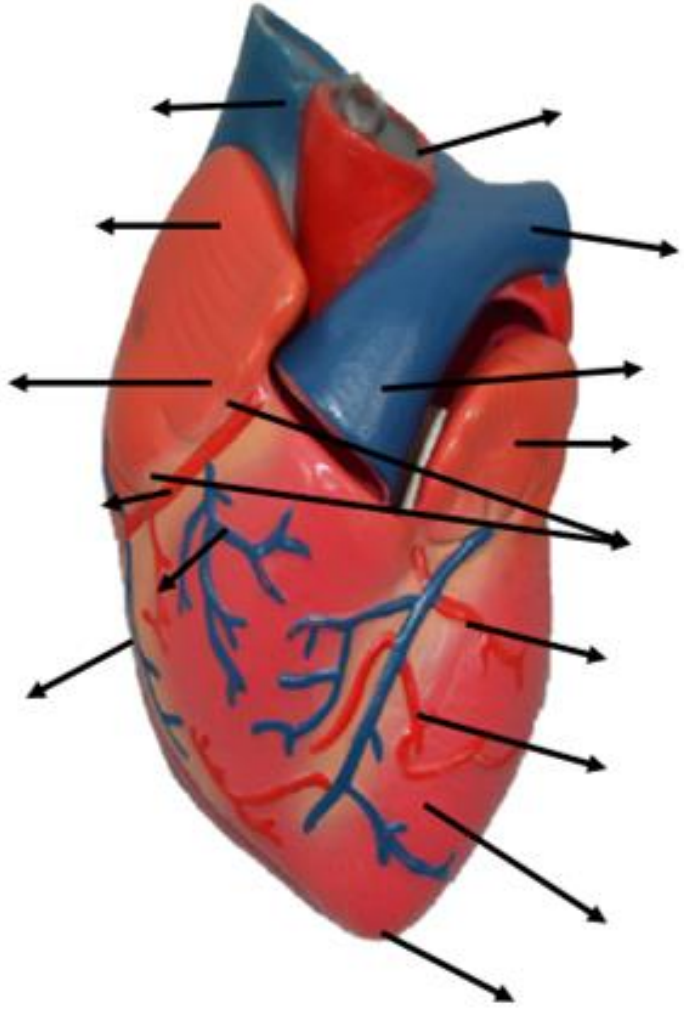


Figura: 4-49. Ciclo cardíaco.



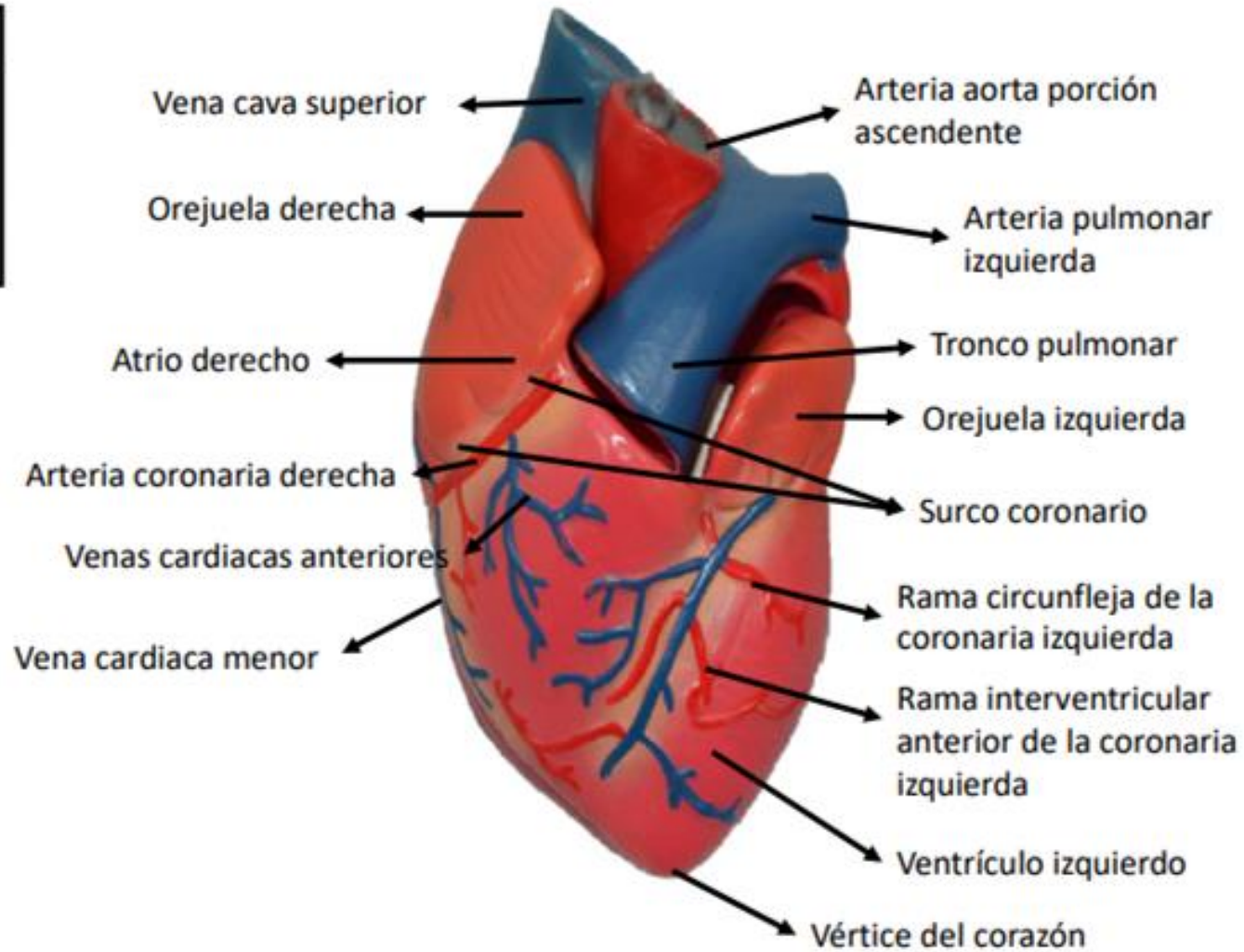
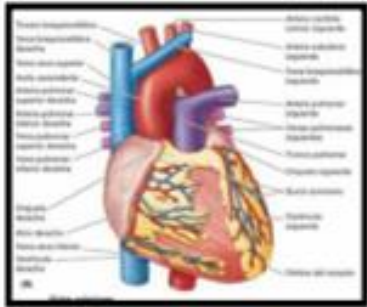
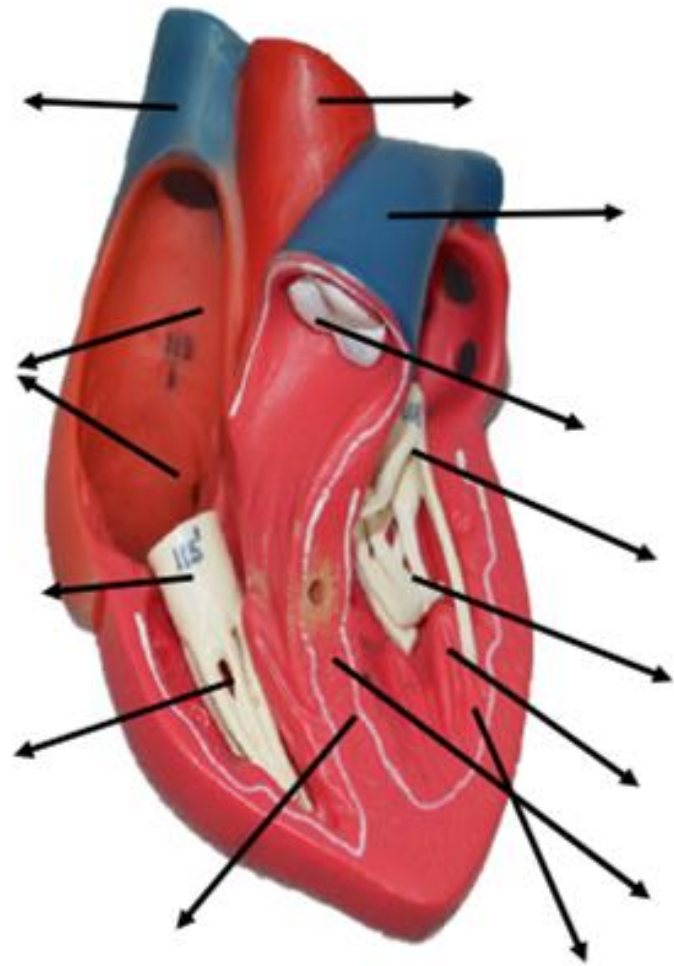
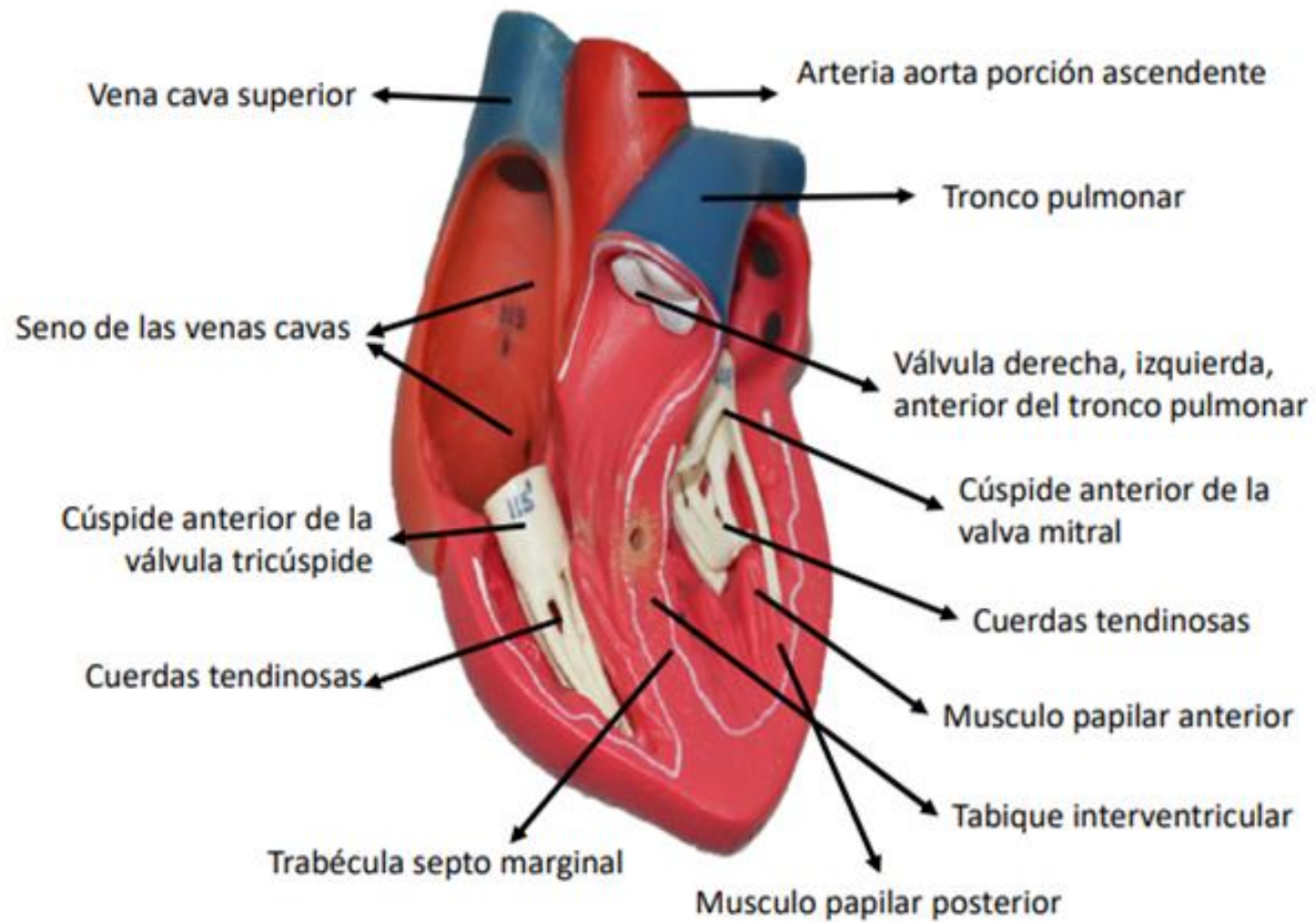
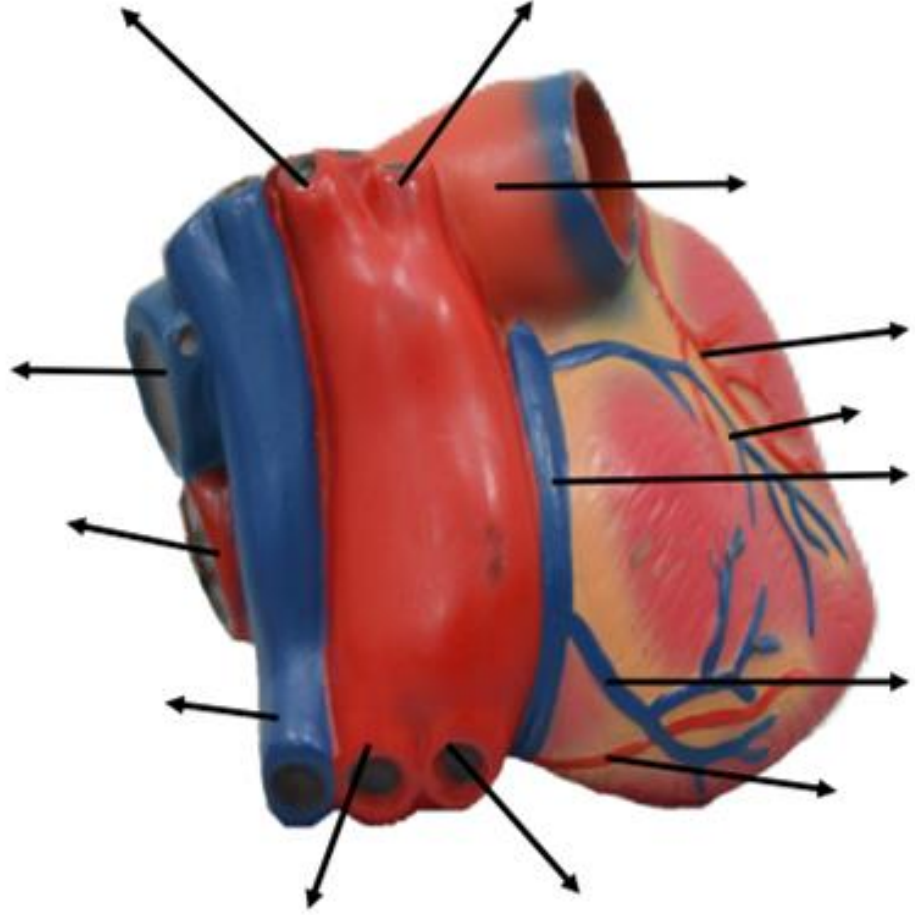
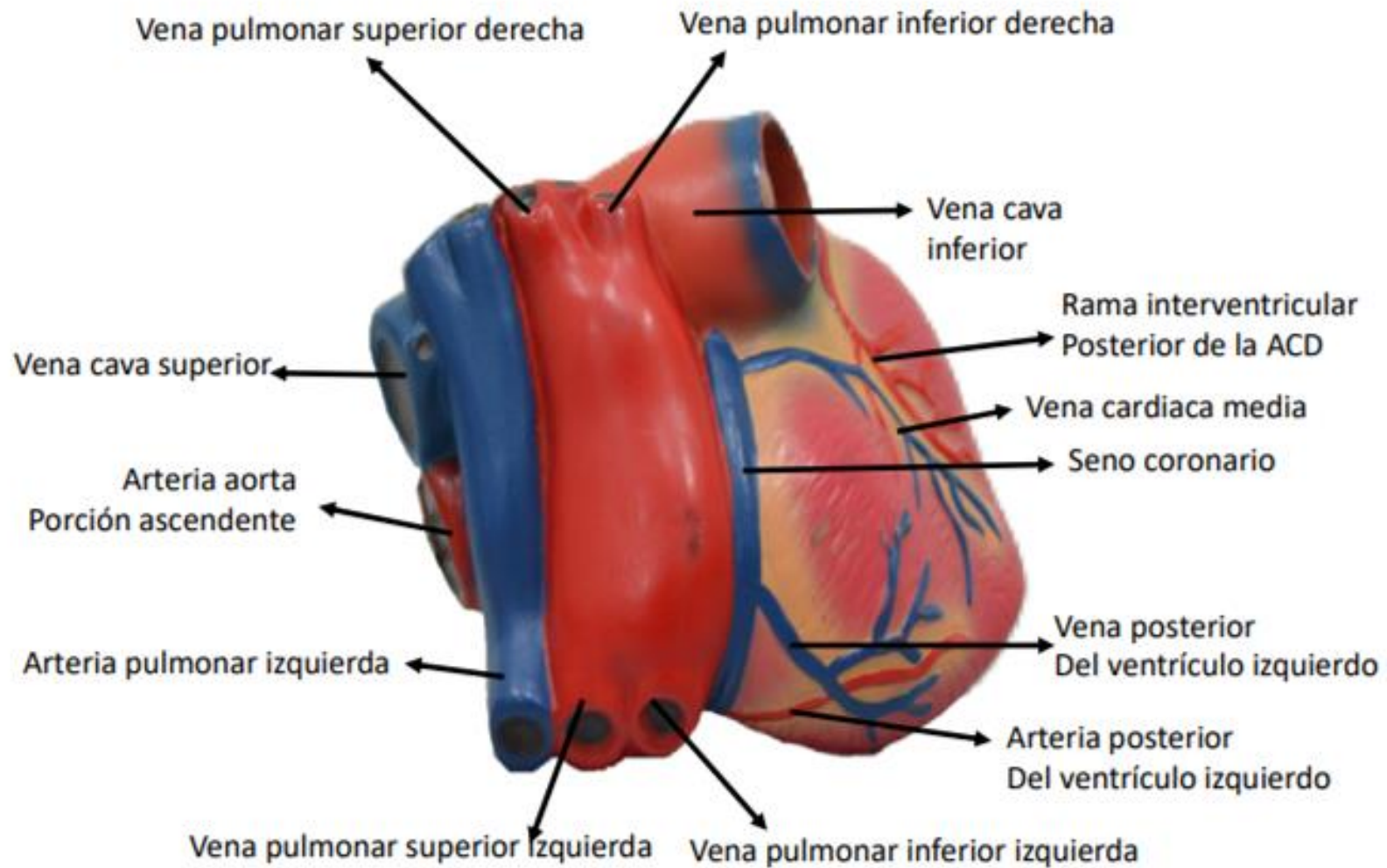


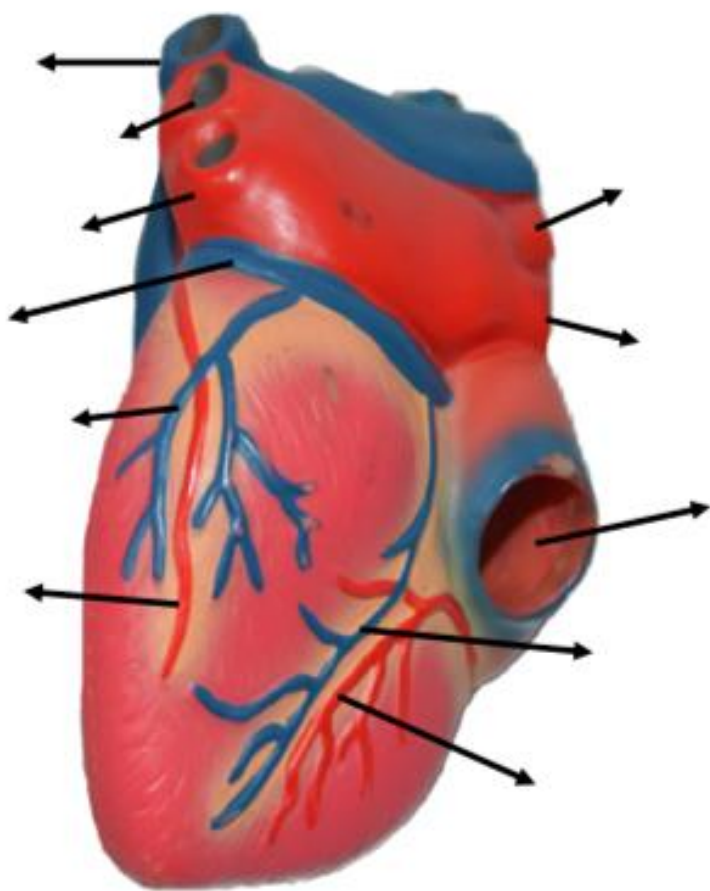
Figura: 4-53. Forma, orientación, caras y bordes del corazón.

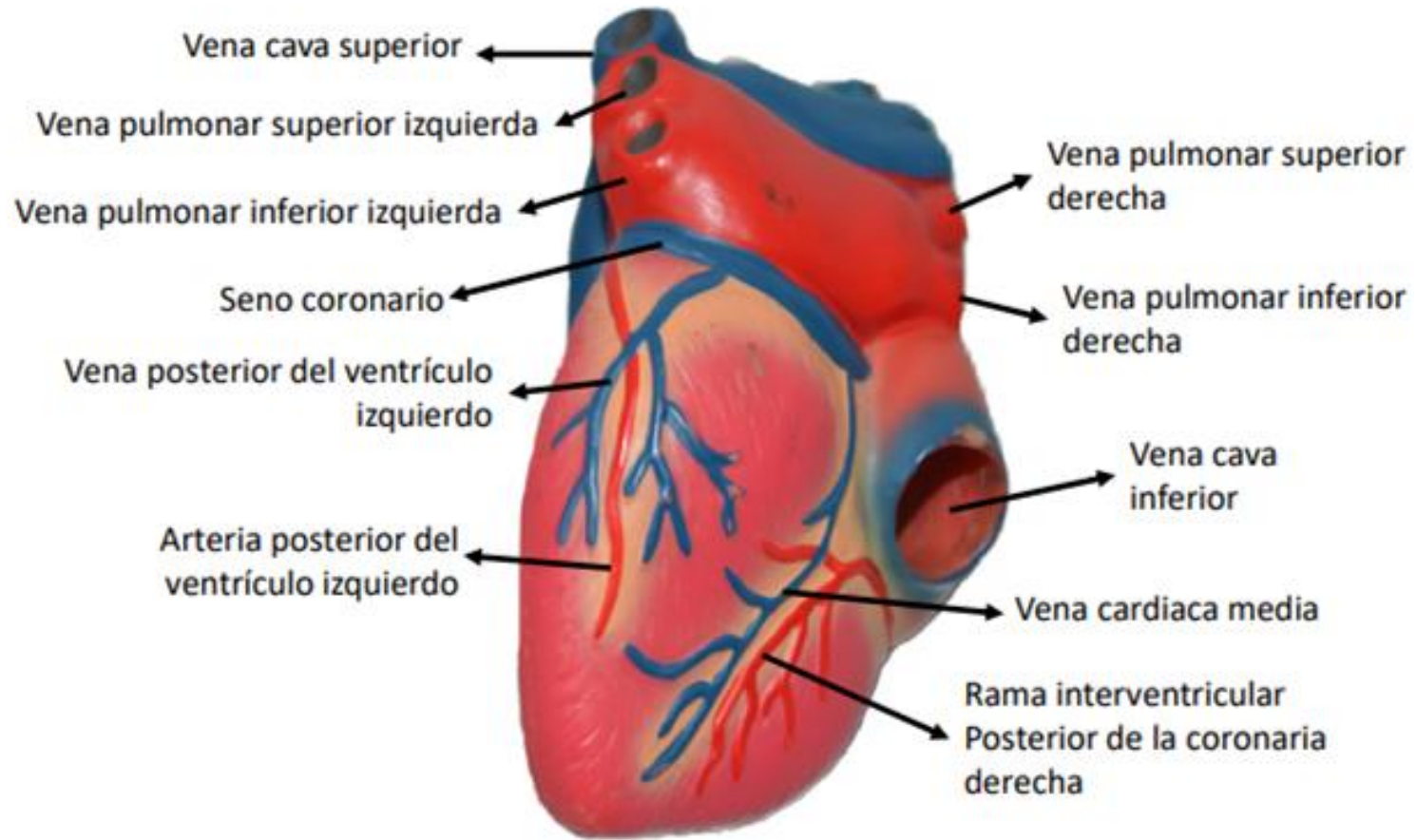


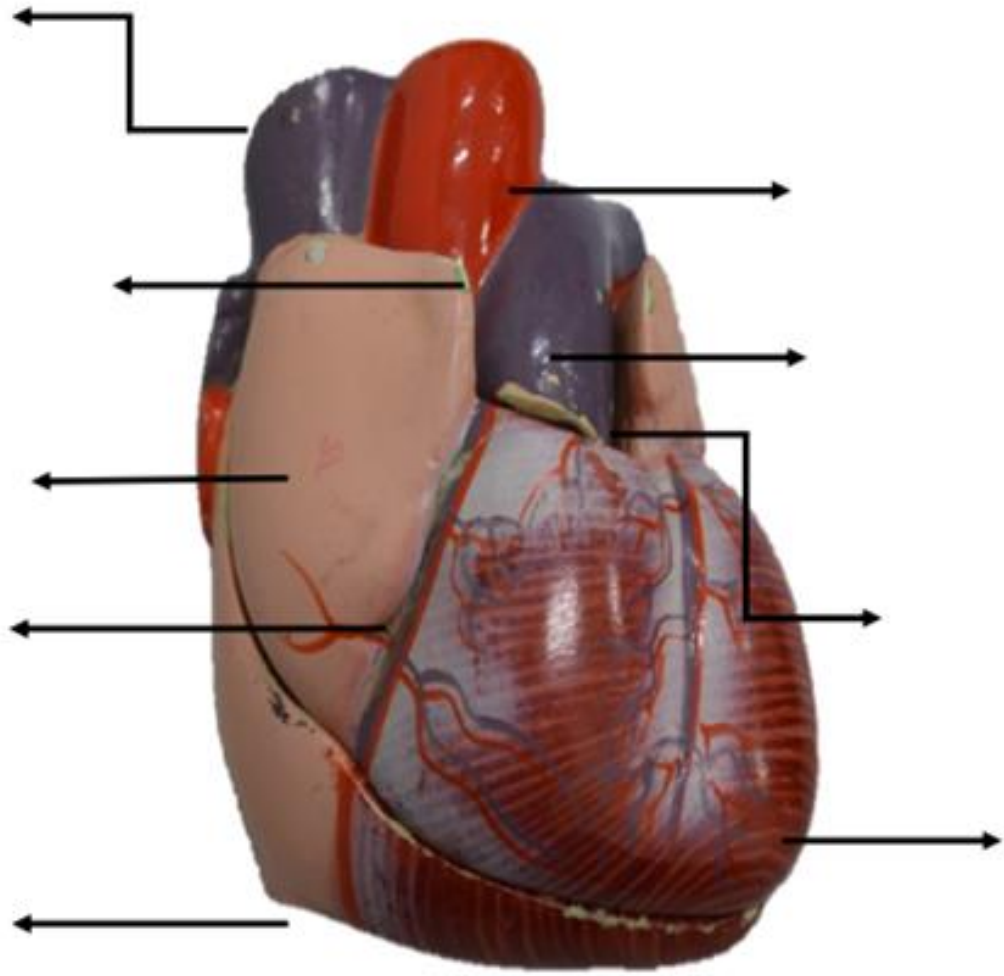












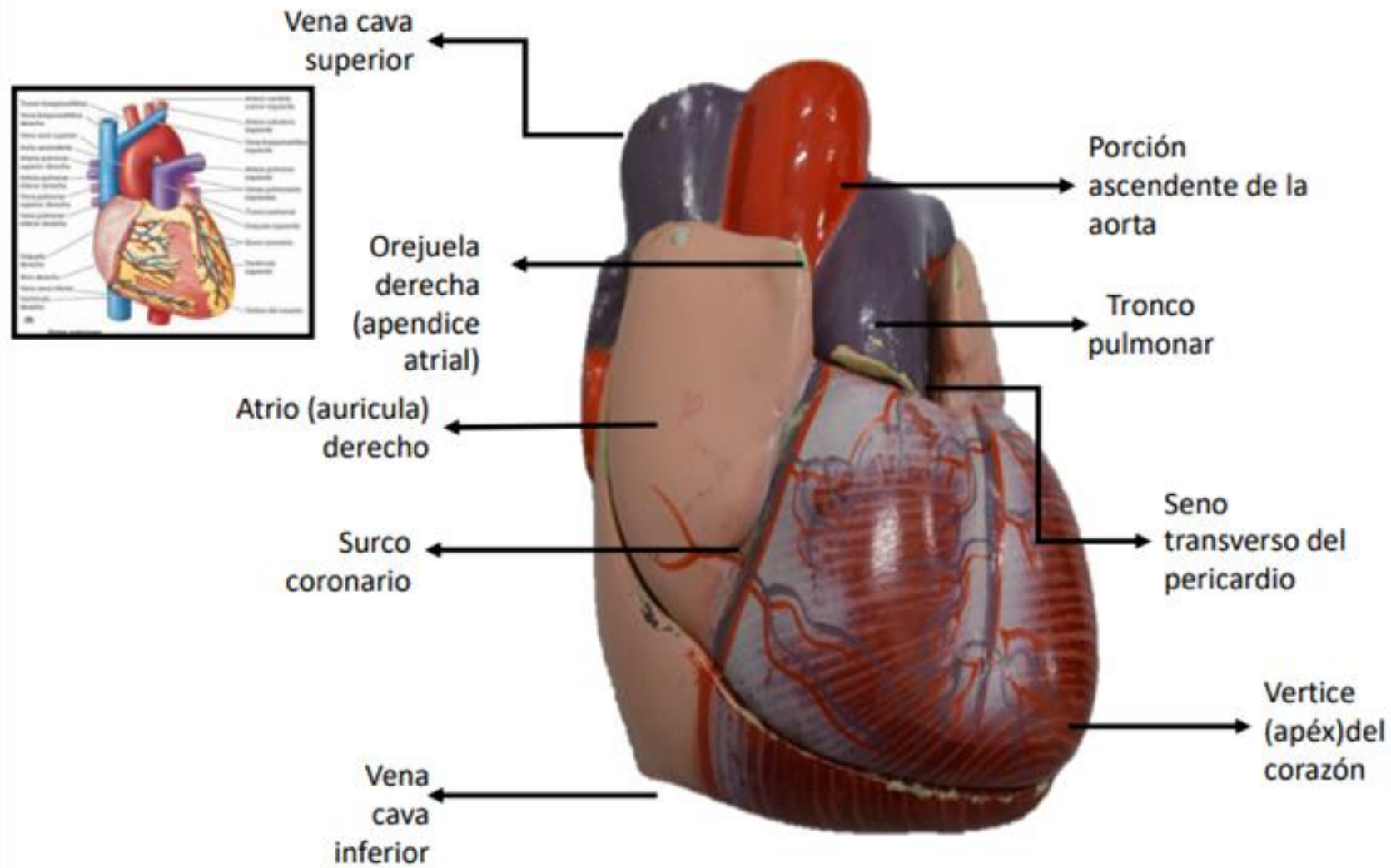
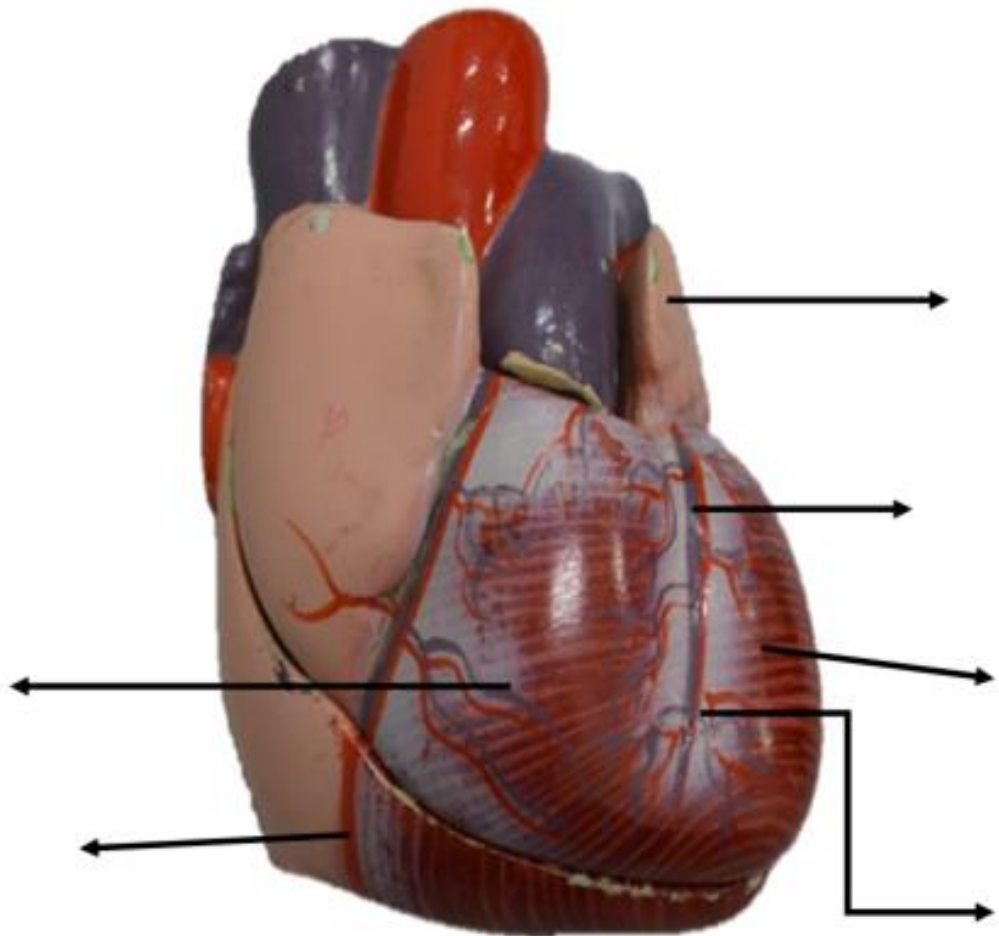


Figura: 4-53. Forma, orientación, caras y bordes del corazón.



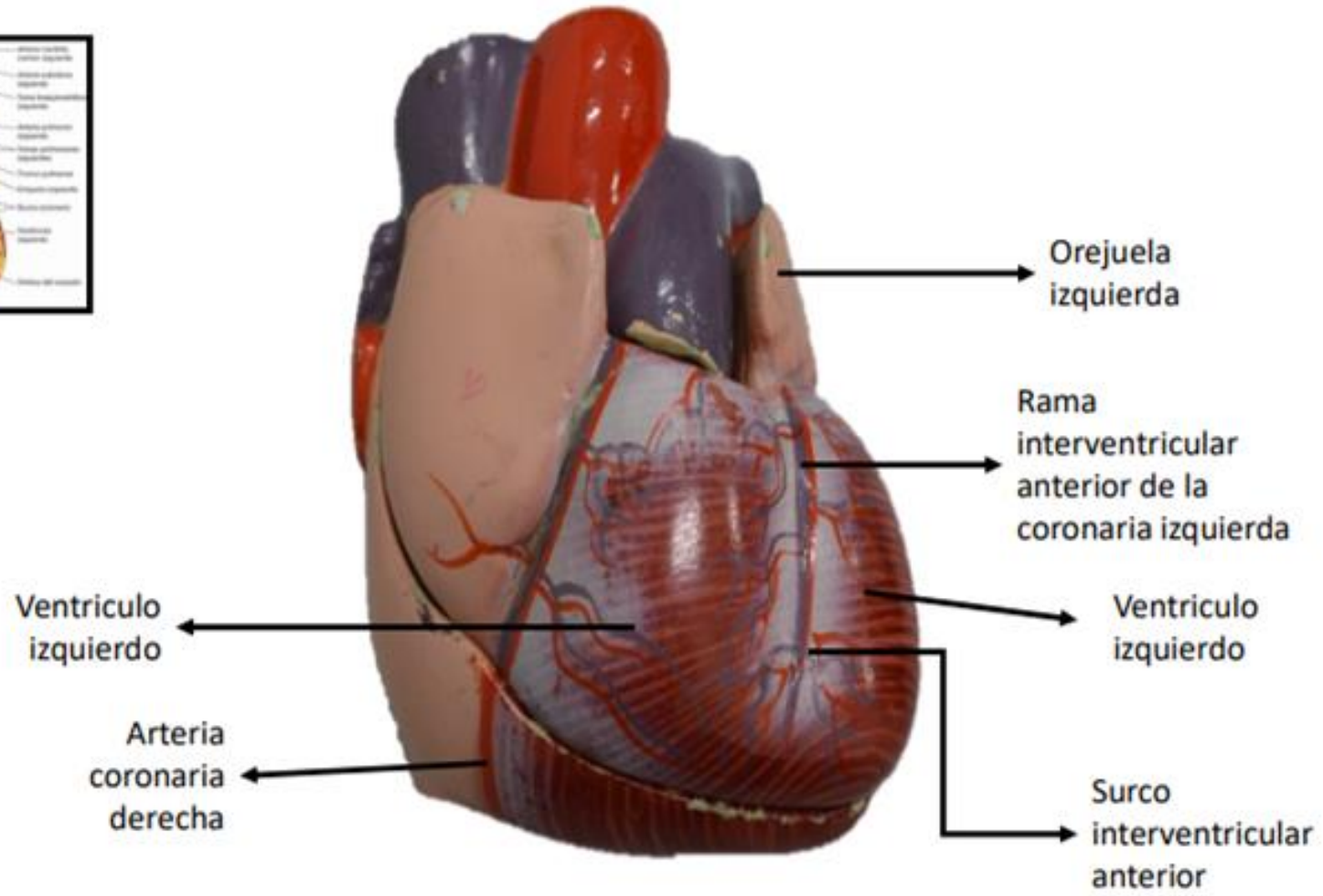
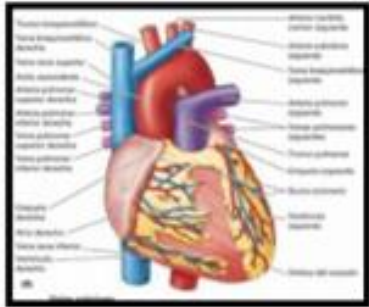
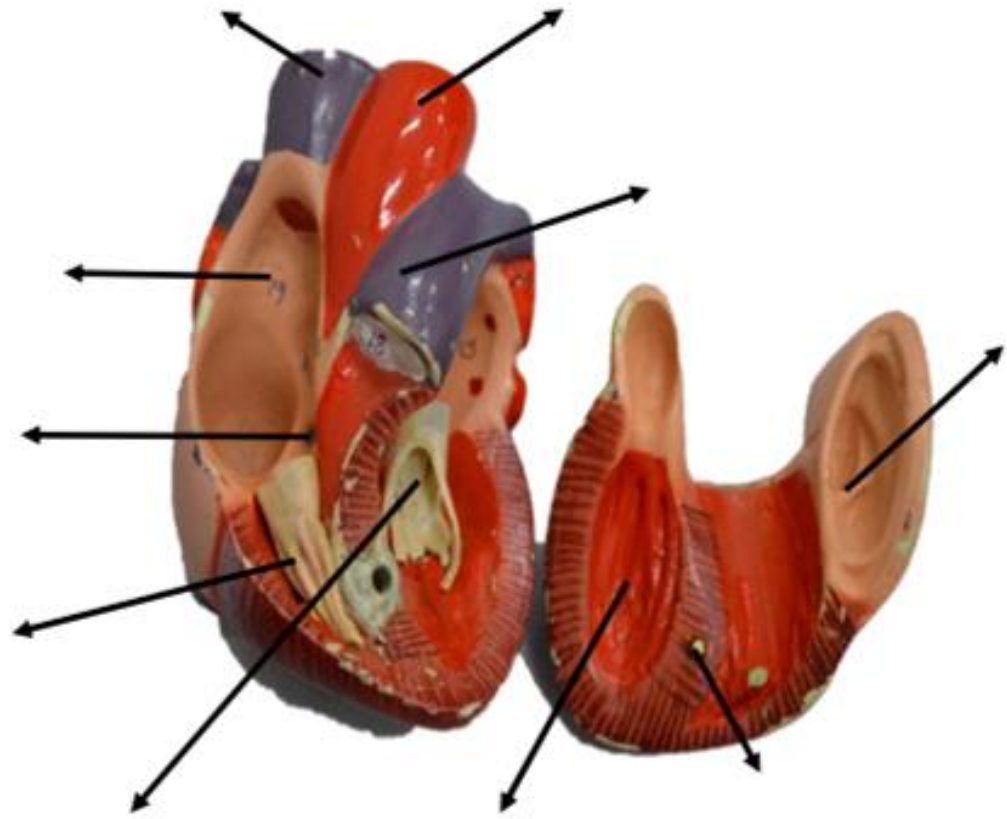


Figura: 4-53. Forma, orientación, caras y bordes del corazón.



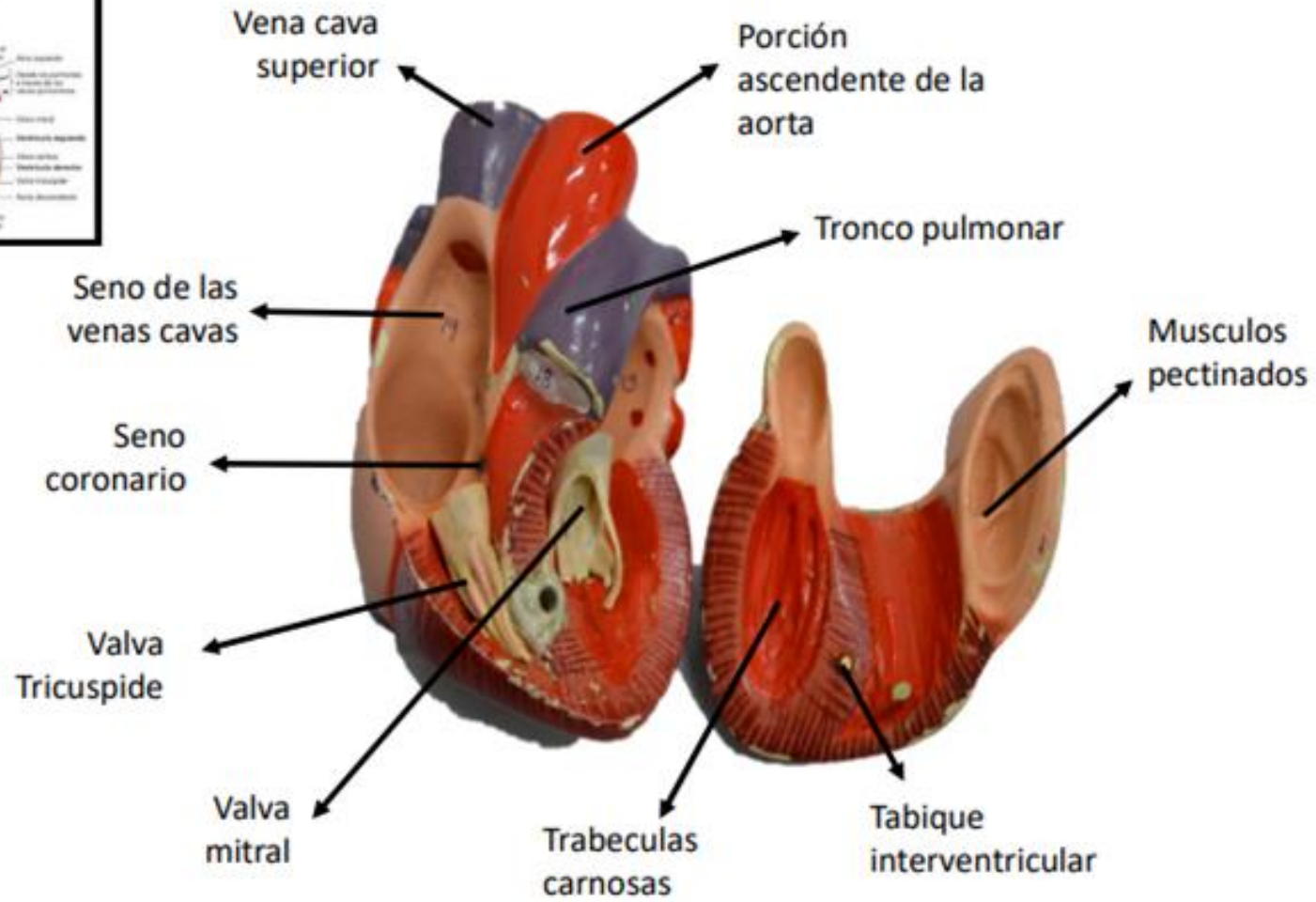
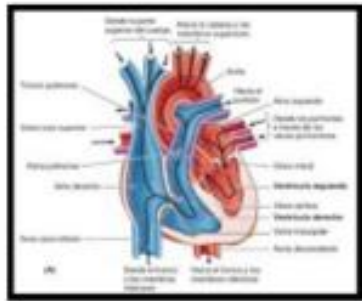
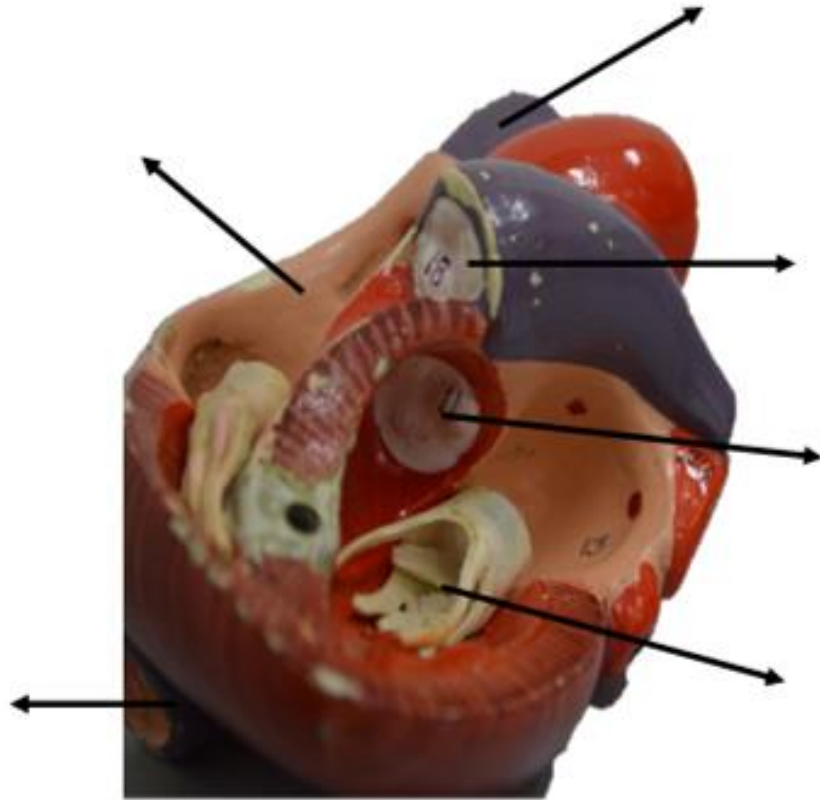
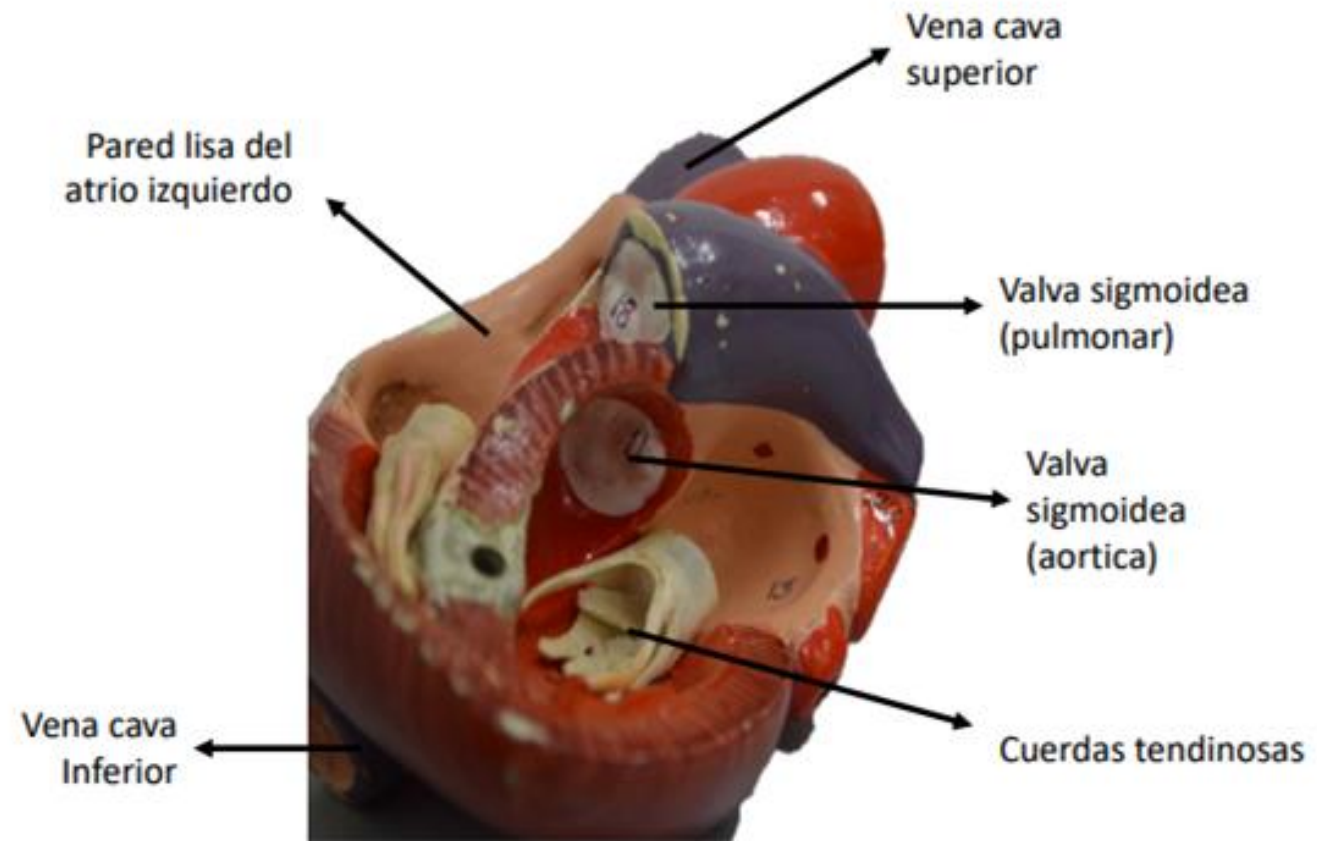
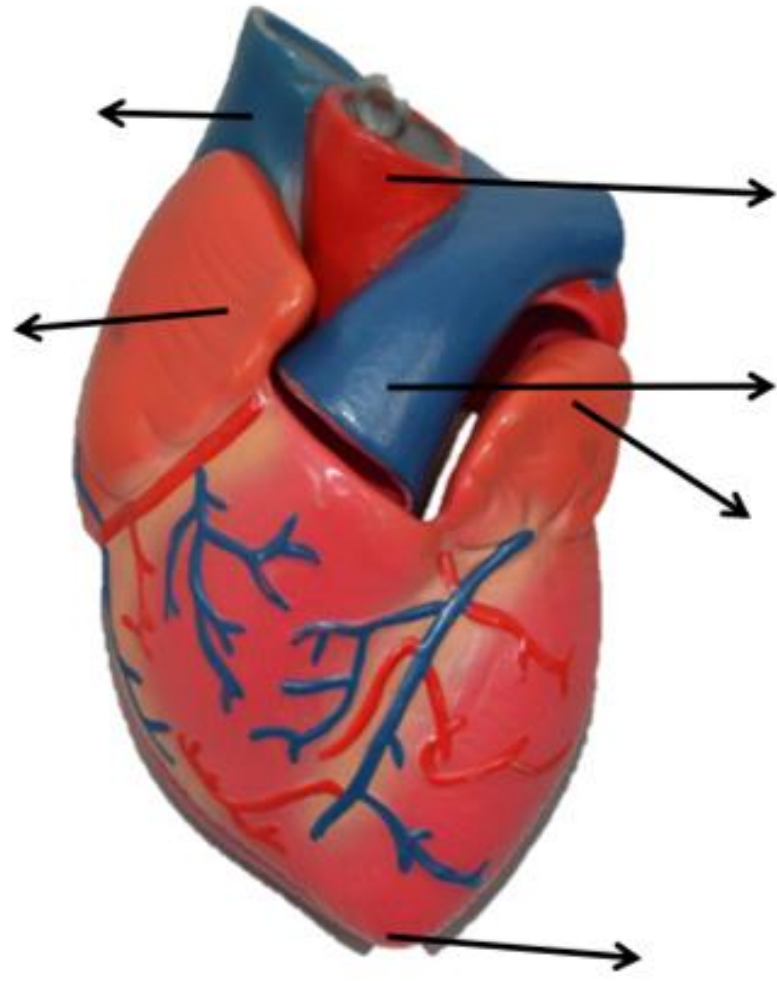


Figura: 4-49. Ciclo cardíaco.







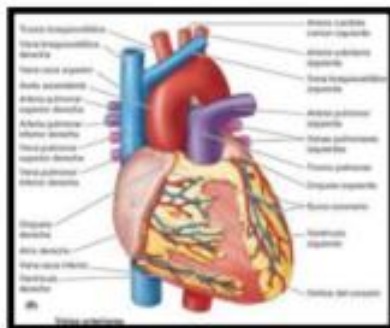
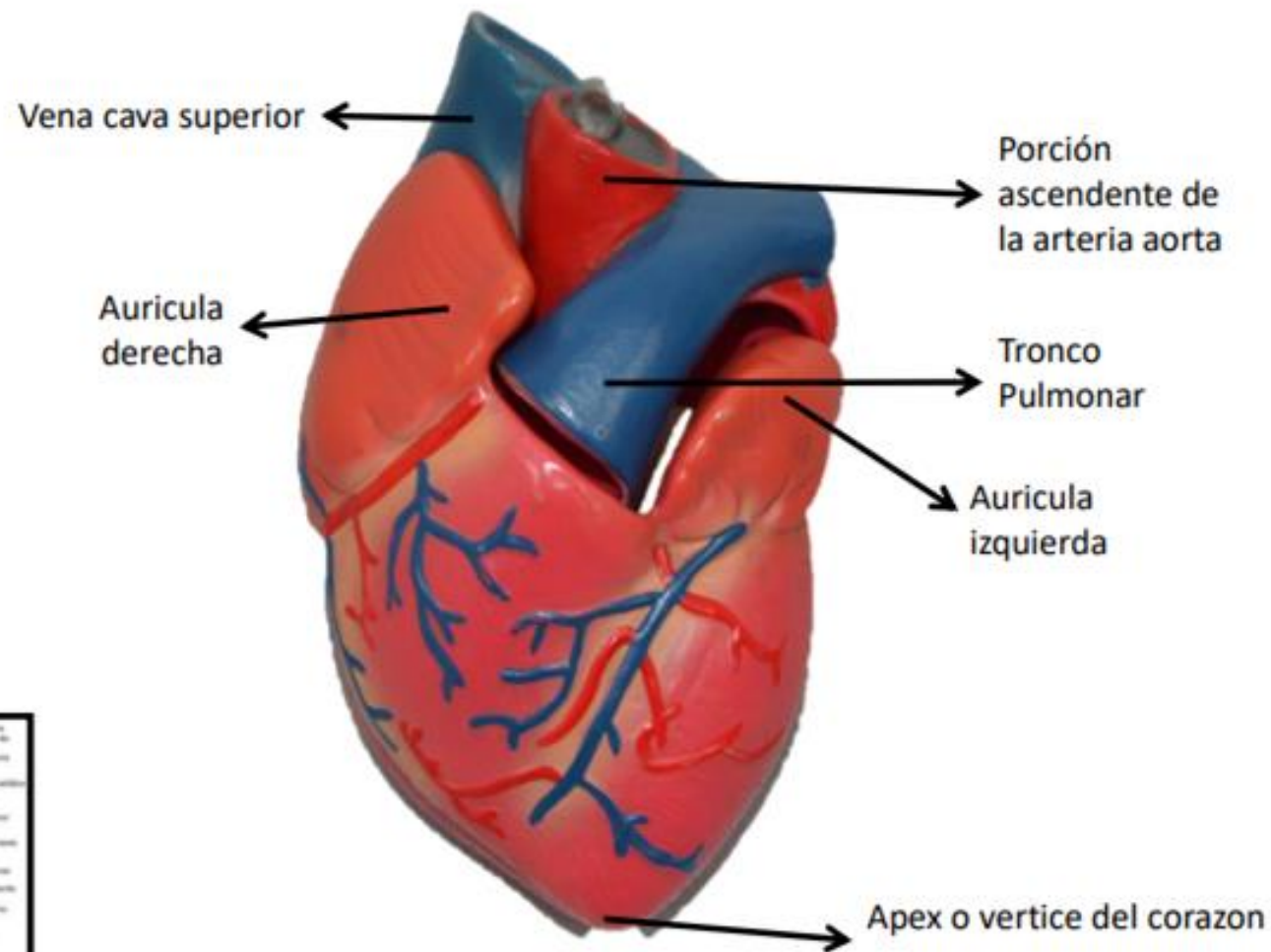
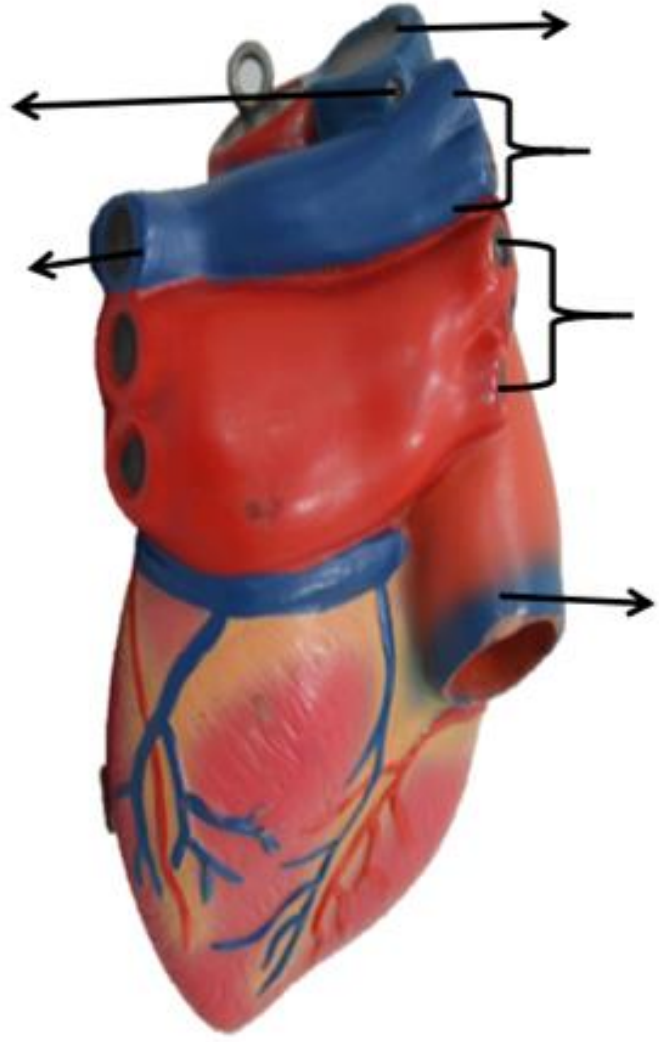
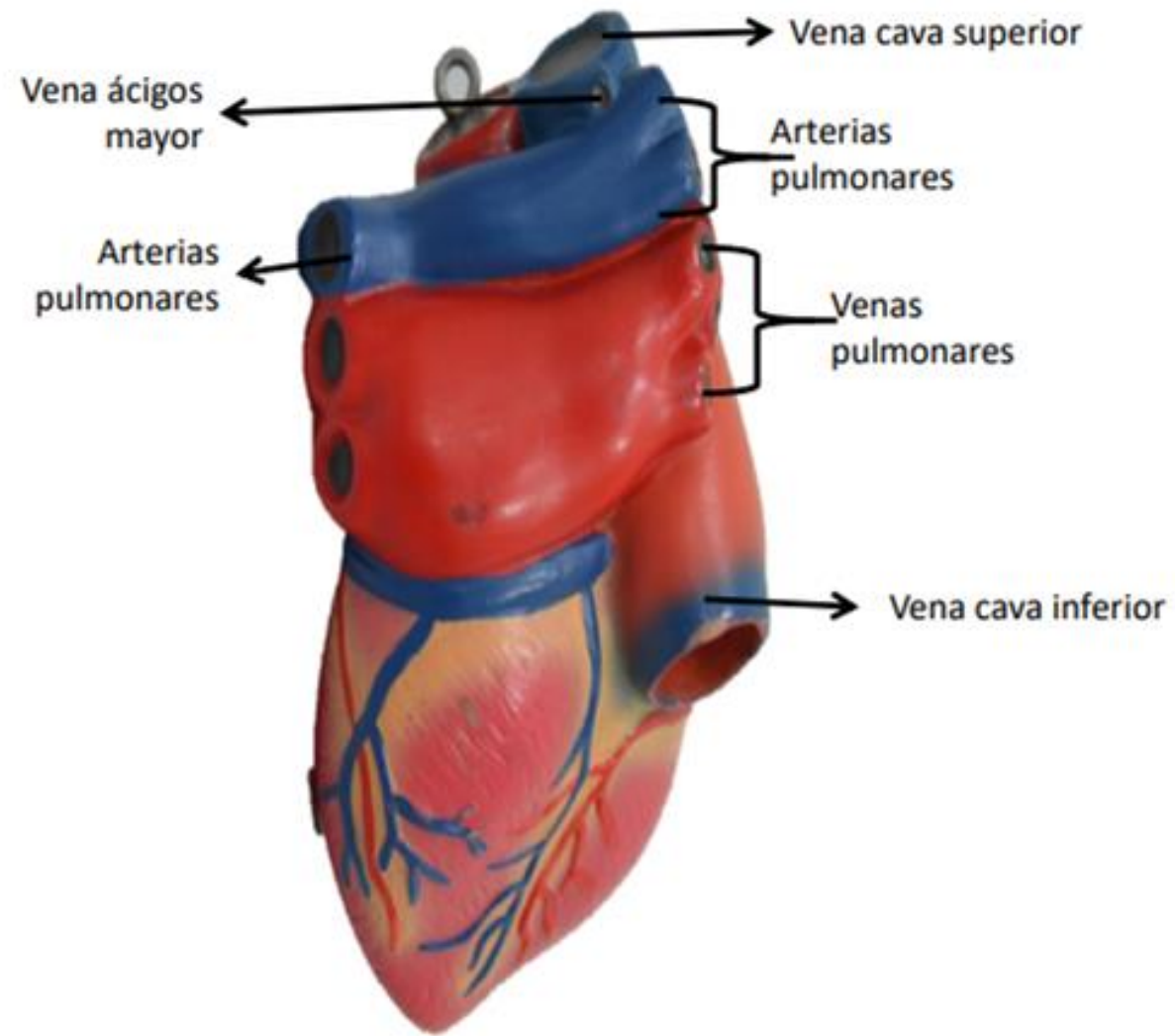
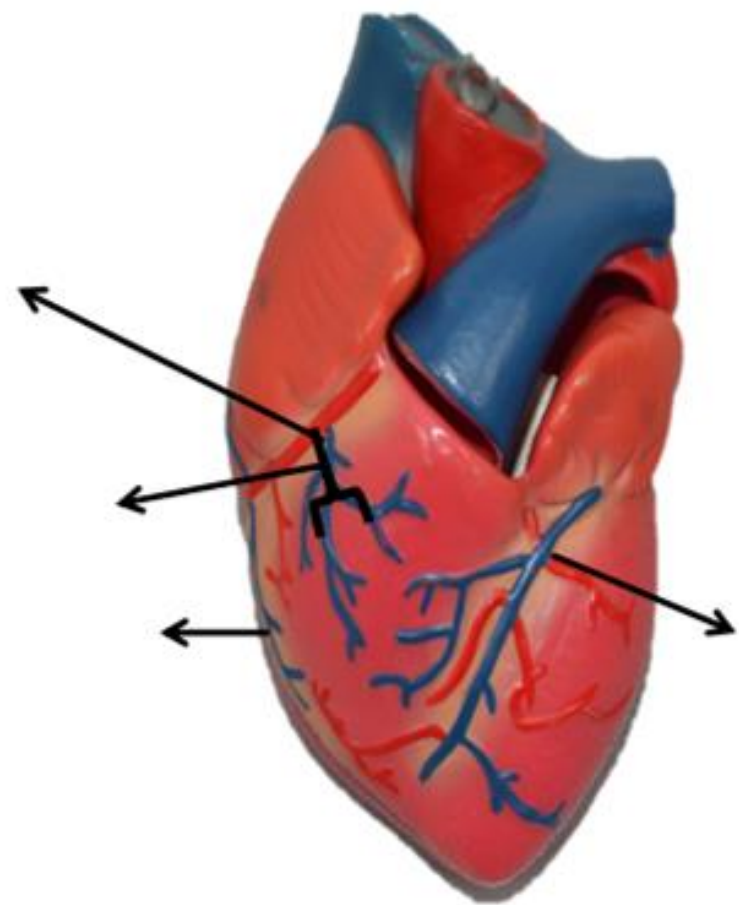


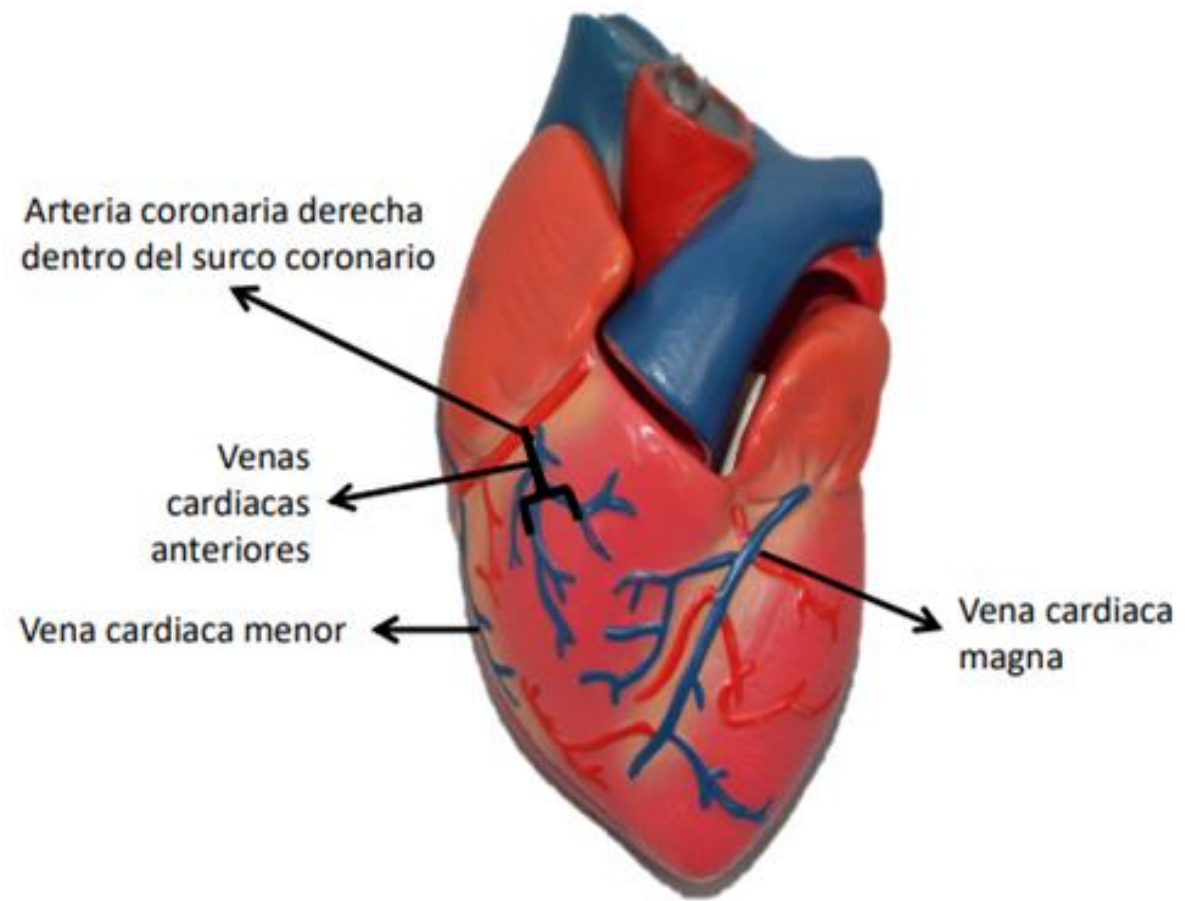
Figura: 4-53. Forma, orientación, caras y bordes del corazón.

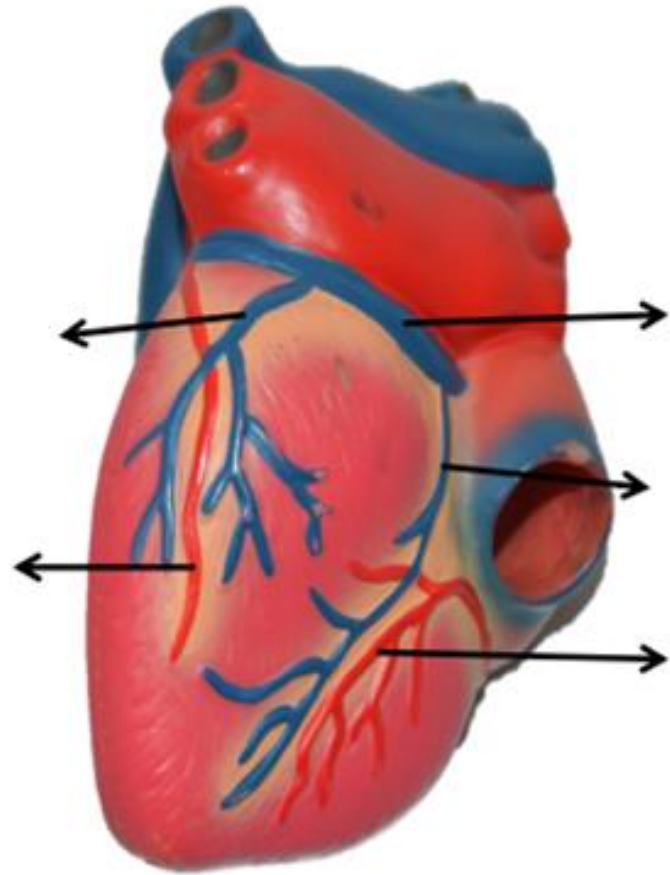
Fuente: Moore KL, Dalley AF, Agur A MR; Fundamentos de anatomía con orientación clínica. 8a Ed. Barcelona: Wolters kluwer Health; 2018. Pagina, 689











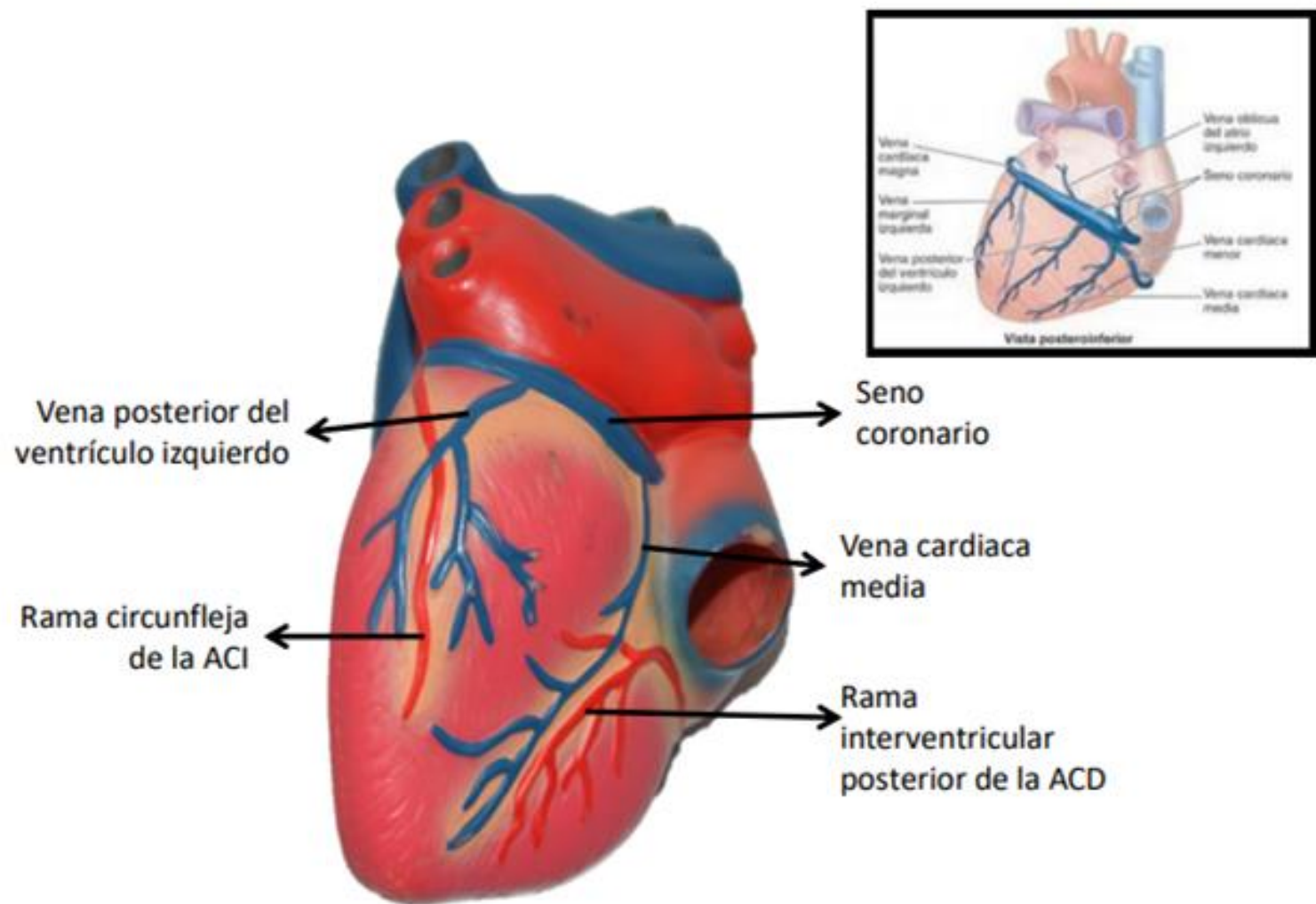


Figura: 4-62. Venas del corazón.

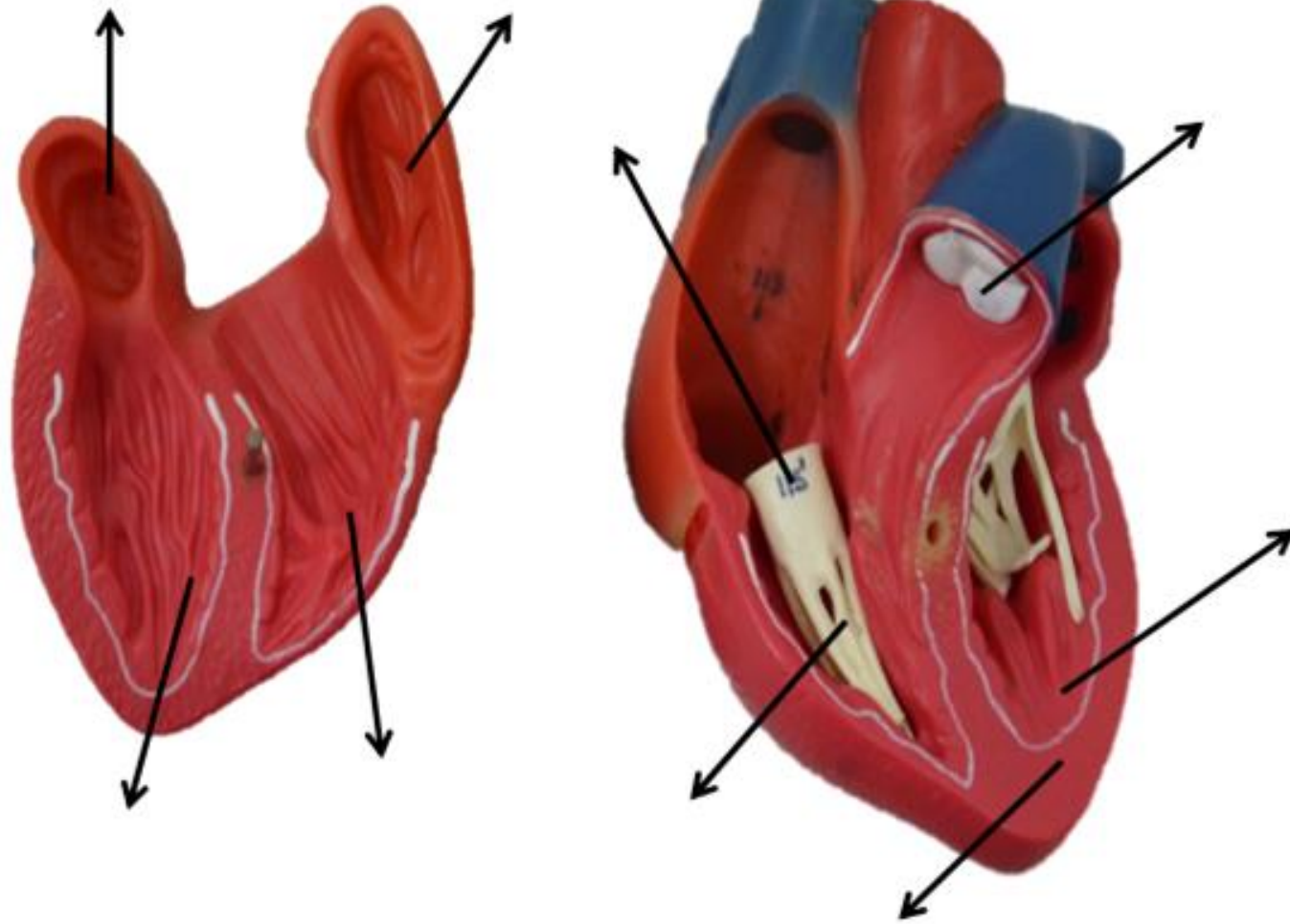
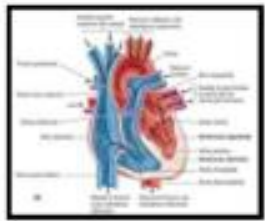


Figura: 4-49. Ciclo cardíaco.

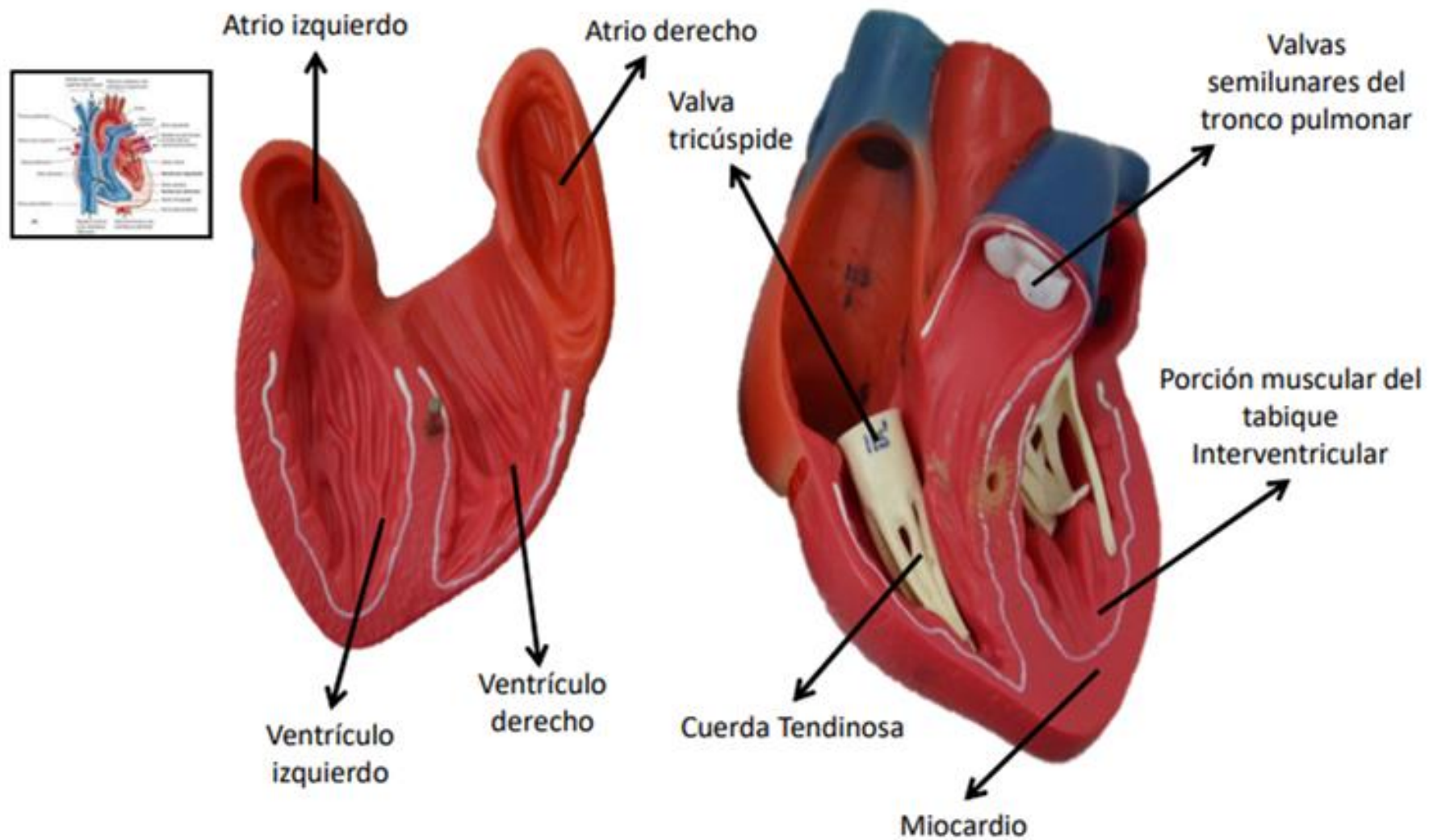


Figura: 4-49. Ciclo cardíaco.